

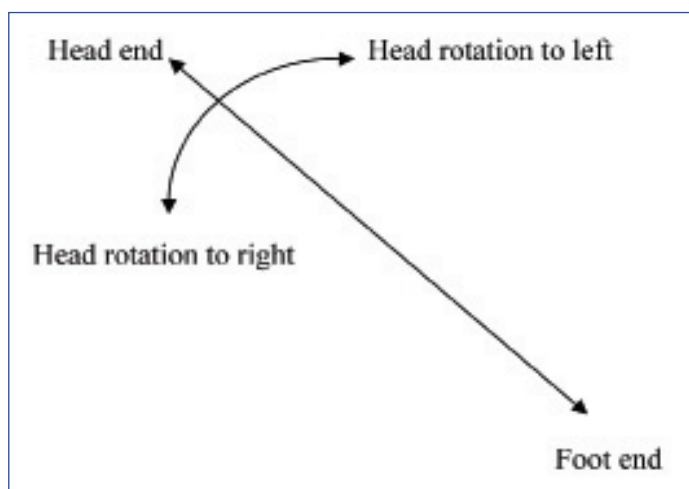
# Head Rotation Manoeuvre during Flexible Bronchoscopy

RAHUL MAGAZINE

**Keywords:** Bronchoscopist, Magazine's head rotation manoeuvre, Trans bronchial needle aspiration

Sir,

During flexible bronchoscopy it is not possible, at times, to rotate the scope further once the limit of bronchoscopist's wrist movements have been reached. Moreover, maintaining this extreme wrist position – full flexion or extension – for a long time can be painful for the bronchoscopist. However, such movements are required quite often during flexible bronchoscopy and, more so, if a Trans Bronchial Needle Aspiration (TBNA) is being performed [1]. During TBNA, depending on the location of the lymph node, the operator may need to rotate the wrist to extreme positions in order to position the needle correctly for a proper puncture of the node. At times even full flexion or extension does not result in the scope reaching the desired spot. Keeping this problem in mind, a simple technique was devised which can add more rotation to the scope, and sometimes even obviate the need to perform extreme flexion or extension of the wrist. It is proposed that during flexible bronchoscopy – with the bronchoscopist behind a supine patient's head – when the operator needs to rotate the scope he may make the usual wrist movements, but add a further step if more rotation of the scope is required. The step includes gently rotating the patient's head laterally to the side towards which the rotation of the scope is desired [Table/Fig-1]. This will make the scope rotate over and above that can be achieved by even the extreme wrist movement. The degree of rotation of the scope can be adjusted by gently rotating the head back and forth. It is proposed to call this technique Magazine's head rotation manoeuvre. It was found to be particularly useful while doing TBNA; and has been performed successfully, in 20 patients, while doing flexible bronchoscopy via transnasal or transoral approach. These observations have been made during routine flexible bronchoscopy and not under formal study conditions. Eighteen of these patients were undergoing flexible bronchoscopy for TBNA, and for the rest the head rotation



**[Table/Fig-1]:** Orientation of the patient and the direction of head rotation.

manoeuvre was performed to negotiate a difficult anatomy. Head rotation has been found to cause movement of endotracheal tube which are mostly predictable but in some situations random [2]. While performing this manoeuvre certain precautions need to be taken: the patient should not have any cervical spine disease and, of course, care needs to be taken that the upper airway patency is not compromised in any way.

## REFERENCES

- [1] Kùpell E. Conventional transbronchial needle aspiration in community practice. *J Thorac Dis.* 2015;7(Suppl 4):S256-65.
- [2] Kim JT, Kim HJ, Ahn W, Kim HS, Bahk JH, Lee SC, et al. Head rotation, flexion, and extension alter endotracheal tube position in adults and children. *Can J Anaesth.* 2009;56(10):751-56.

### PARTICULARS OF CONTRIBUTORS:

1. Professor, Department of Pulmonary Medicine, Kasturba Medical College, Manipal Academy of Higher Education (MAHE), Manipal, Karnataka, India.

### NAME, ADDRESS, E-MAIL ID OF THE CORRESPONDING AUTHOR:

Dr. Rahul Magazine,  
Department of Pulmonary Medicine, Kasturba Medical College,  
Manipal Academy of Higher Education, Manipal -576104, Karnataka, India.  
E-mail: rahulmagazine@gmail.com

**FINANCIAL OR OTHER COMPETING INTERESTS:** None.

Date of Submission: **Dec 18, 2017**  
Date of Peer Review: **Feb 01, 2018**  
Date of Acceptance: **Apr 02, 2018**  
Date of Publishing: **Jul 01, 2018**