

# Malignant Extragastrintestinal Stromal Tumours: what are the Prognostic features to depend upon?

USHA DUBEY, RUMPA DAS, ASHA AGRAWAL, CHAYANIKA PANTOLA, NEELIMA VERMA

## ABSTRACT

Extragastrintestinal stromal tumours (EGISTs) are rare intra abdominal tumours which occur in the omentum, the mesentery and other intra abdominal sites. Their histogenesis is said to be from the interstitial cells of the Cajal, as these cells express CD-117. The differential diagnosis includes fibromatosis, smooth muscle and neural tumours, etc. We present a case of a 50 year old man, who presented with acute pain in the abdomen. Ultrasonography (USG) showed multiple, round, homogenous, hypoechoic masses in the mesentery, measuring 1.5 to 2.5 cm in diameter.

USG guided fine needle aspiration was performed. On the basis of the cytological findings, a diagnosis of malignant spindle cell lesion was made. On the basis of the histopathological findings, the tumour was diagnosed as an extragastrintestinal stromal tumour. The tumour showed CD-117 positivity, which confirmed the diagnosis. We are presenting this case to highlight the diagnostic features and the prognostic values of the different features which are mentioned in different literatures.

**Key Words:** Extragastrintestinal stromal tumour, Fibromatosis, Smooth muscle tumours, CD-117

## INTRODUCTION

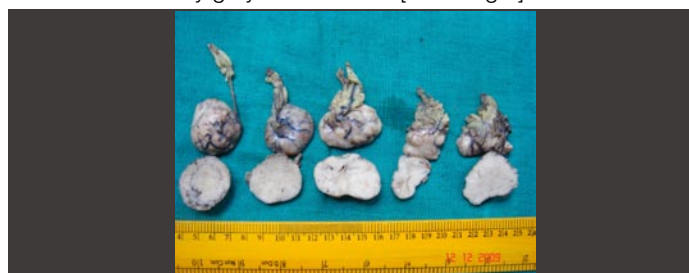Extra gastrointestinal stromal tumours are the rare intra abdominal tumours which occur in the omentum, the mesentery and other intra abdominal sites. By definition, they display no connection, however tenuous, to the wall or serosal surface of viscera [1]. With regards to their nomenclature, these tumours have a long list. Stout called them "leiomyoblastoma" [2]. It was in 1983, when Mazur and Clark documented the absence of the muscle markers and named these tumours as "stromal tumours" [3]. Their histogenesis is said to be from the interstitial cells of Cajal, as these cells express CD-117 [4].

## CASE REPORT

We present a case of a 50 year old man who presented with acute pain in the abdomen. Ultrasonography showed multiple, round, homogenous, hypoechoic masses in the mesentery, measuring 1.5 to 2.5 cm in diameter. USG guided fine needle aspiration was performed. On the basis of the cytological findings, a diagnosis of malignant spindle cell lesion was made. The surgical resection of the tumour was done. The tumour was composed of multiple mesenteric nodules which were 2.5 to 3.5 cm in diameter. These nodules were at no place connected to the wall or the serosal surface of the viscera. These nodules were resected and sent for histopathological examination.

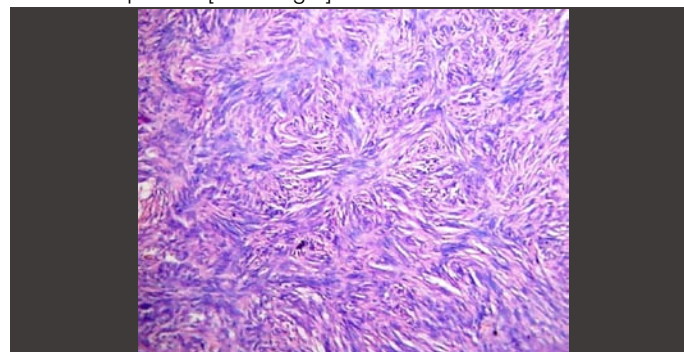
## RESULTS

Grossly, the tumour was composed of nodules of varying sizes which were 1.5 to 3.5 cm diameter. No part of the intestine was attached to the resected nodules. The cut surface of these nodules was firm and fleshy grey-red in colour [Table/Fig 1].



[Table/Fig 1]: Gross picture of excised tumour nodule

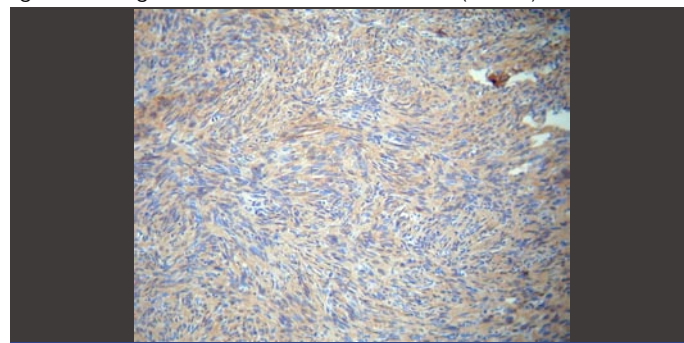
Microscopic examination revealed that the tumour was composed of short, fusiform spindle cells having centrally placed oval nuclei. These cells were arranged in short ill defined fascicles, thus forming a storiform pattern [Table/Fig 2].



[Table/Fig 2]: 400 X H& E Image of the tumour

High cellularity, a high mitotic count (>5/ 50 hpf) and marked nuclear atypia suggested the high risk nature of the tumour. However, necrosis was absent. A diagnosis of malignant extragastrintestinal stromal tumour was suggested.

Immunohistochemistry showed positivity for CD117(c-kit) [Table/Fig 3] and negativity for CD34. This confirmed the diagnosis of malignant extragastrintestinal stromal tumour (EGIST).



[Table/Fig 3]: Diffuse CD- 117 Positivity of the tumour

On continued follow-up, the patient developed a recurrence of a similar tumour within one year.

## DISCUSSION

EGISTs are histologically and immunohistochemically similar to their gastrointestinal counterparts but are rare and have an aggressive course. Their histogenesis is said to be from the interstitial cells of Cajal, as these cells express CD-117. EGISTs also show positivity for CD-34 in 50% of the cases. A recent observation that the interstitial cells of Cajal do not express CD34 whereas the fibroblasts of Auerbach's plexus do, suggests that the stromal tumours may display hybrid features [5].

EGISTs usually present during the adult life as enlarging masses of variable duration. Approximately 80% of them are located in the mesentery or the omentum and the remaining 20% develop in the retroperitoneum. The tumours vary in size from 2.1-32 cm, with most of them being greater than 10 cm. They usually present as masses with or without cystic changes [1], [6]. The tumours which present as multiple nodules are usually metastatic to primary GIST and are confused with peritoneal carcinomatosis [7]. In our case, the tumour presented as multiple nodules and there was no evidence of any primary tumour in the gastrointestinal tract.

The cytological picture usually reveals a highly cellular tumour, comprising of either a pure spindle or epithelioid cell pattern, or it might show a mixed pattern of cells [8], [9]. On histological examination, the tumours are found to be composed of either purely rounded epithelioid cells or short fusiform cells in a fine, fibrillary, collagenous background. Rarely, a mixed pattern is also encountered. As with GISTs, EGISTs also display varying amounts of stromal hyalinization, myxoid changes and cyst formations. However, skeinoid fibres, which are the common markers in GISTs of the small bowel, are absent in this tumour. Immunohistochemically, these tumours show diffuse positivity for CD117 in a diffuse cytoplasmic or membranous pattern [1], [4], [6].

Reith et al, in their study of 48 cases, found that the most common sites were the omentum and the mesentery, followed by the retroperitoneum. The features which were generally accorded with respect to the prognostic significance were cellularity, mitotic activity, size, nuclear atypia and necrosis. High cellularity, increased mitotic activity and necrosis were associated with a poor outcome. Twelve patients (39%) had an adverse outcome; of these, 10 died of the tumour and 2 developed metastasis. One patient developed a recurrent tumour in the general area of the original tumour [10]. The tumours with a mitotic count of >2/50 hpf are of the high risk category. In contrast to the studies on GISTs, those on EGISTs did not report any association between the tumour size and the outcome. This may be due to the large size of most of the tumours at the time of presentation. However, in the present case, the tumour size was small and necrosis was absent but the mitotic activity, cellularity and nuclear atypia suggested the high risk nature of the tumour. In their study on 92 cases, Lakshmi et al found GISTs to be high grade tumours (70.4% cases were found to be malignant) [13].

The main differential diagnoses which were considered in the present case were fibromatosis, smooth muscle tumours, neural tumours and malignant fibrous histiocytomas.

The distinction from fibromatosis is made primarily on the basis of morphology. Fibromatosis has low cellularity and it is composed of spindle cells lying in a collagenous stroma. Necrosis and mitotic activity is absent. Also, mesenteric fibromatoses are usually negative for CD-117 [11].

Smooth muscle tumours and neural tumours are differentiated from EGISTs on the basis of both morphology and immunohistochemistry. Both of these tumours are negative for CD-117 [12].

The storiform pattern of the tumour might be confused with that of malignant fibrous histiocytoma (MFH). But, there was an absence of giant cells and CD-117 positivity favoured the diagnosis of EGIST [1].

In the present case, despite being small in size, the tumour was not asymptomatic and the patient presented with an acute abdomen. Further, the absence of necrosis and the small size of the tumour were in favour of a better prognosis, but the high mitotic activity suggested the possibility of a high risk tumour. The patient had a recurrence of the tumour within one year. In this case of EGIST, the mitotic activity had a higher prognostic value than the other features.

GISTs are resistant to conventional chemotherapy and radiation. Surgical resection is still the best modality of treatment. However, the survival of the patients with metastatic and inoperable GISTs has improved dramatically since the introduction of imatinib mesylate into the treatment protocols.

## CONCLUSION

This case emphasises that though it is a rare tumour, EGIST must be considered in the differential diagnosis of the mesenchymal tumours and that immunohistochemistry should be done to confirm the diagnosis. The prognostic values of the different parameters need to be discussed and each case must be followed properly. The behaviour of these tumours varies from being benign to highly malignant and so the correct assessment of the behaviour of the tumour is a must for the proper management of the patient.

## REFERENCES:

- [1] Weiss SW, Goldblum JR. Extragastrointestinal stromal tumor. In: Enzinger FM, Weiss SW. Soft tissue tumors. 5th ed. St. Louis: Mosby;2008. p. 565-579.
- [2] Stout AP. Bizarre smooth muscle tumor of the stomach. *Cancer* 1962; 15:400.
- [3] Mazur MT, Clark HB. Gastric stromal tumors: reappraisal of histogenesis. *Am J Surg Pathol* 1983; 7:507.
- [4] Kim JH, Boo YJ, Jung CW, Park SS, Kim SJ, Mok YJ, Kim SD, Chae YS, Kim CS. Multiple malignant extragastrointestinal stromal tumors of the greater omentum and results of immunohistochemistry and mutation analysis: A case report. *World J Gastroenterol* 2007; 13(24): 3392-3395.
- [5] Vanderwinden J-M, Rumessen JJ, DeLaet M-H, Vanderhaeghen J-J, Schiffmann SN. CD34+ cells in human intestine are fibroblasts adjacent to, but distinct from, interstitial cells of Cajal. *Lab Invest* 1999; 79: 59-65.
- [6] Sahu SK, Srivastava P, Chauhan N, Kishore S, Bahl D, Sachan P. Extragastrointestinal Stromal Tumor: A Report Of A Rare Case. *The Internet Journal of Surgery*. 2007 Volume 10 Number1.
- [7] Sinha R, Verma R, Kong A. Mesenteric Gastrointestinal Stromal Tumor in a Patient with Neurofibromatosis. *AJR* 2004; 183:1844-1846.
- [8] Ortiz-Rey JA, Fernández GC, Magdalena CJ, Alvarez C, Antón I, San Miguel P, de la Fuente A. Fine needle aspiration appearance of extragastrointestinal stromal tumor. A case report. *Acta Cytol*. 2003 May-Jun;47(3):490-4.
- [9] Harindhanavudhi T, Tanawuttiwat T, Pyle J, Silva R. Extra-Gastrointestinal Stromal Tumor Presenting as Hemorrhagic Pancreatic Cyst Diagnosed by EUS-FNA. *JOP. J Pancreas (Online)* 2009 Mar 9; 10(2):189-191.
- [10] Reith JD, Goldblum JR, Lyles RH, et al. Extragastrointestinal (soft tissue) stromal tumors: an analysis of 48 cases with emphasis on histologic predictors of outcome. *Mod Pathol*. 2000; 13: 577-85.
- [11] Weiss SW, Goldblum JR. Fibromatoses. In: Enzinger FM, Weiss SW. Soft tissue tumors. 5th ed. St. Louis: Mosby;2008. p. 247-249.
- [12] Gupta N, Mittal S, Lal N, Misra R, Kumar L, Bhalla S. A rare case of primary mesenteric gastrointestinal stromal tumor with metastasis to the cervix uteri. *World J Surg Oncol*. 2007; 5: 137.
- [13] Lakshmi VA, Chacko RT, Kurian S. Gastrointestinal stromal tumors: A 7-year experience from a tertiary care hospital. *Indian J Pathol Microbiol*. 2010;53:628-33.

**AUTHORS:**

1. Dr. USHA DUBEY
2. Dr. RUMPA DAS
3. Dr. ASHA AGRAWAL
4. Dr. CHAYANIKA PANTOLA
5. Dr. NEELIMA VERMA

**NAME OF DEPARTMENT(S) / INSTITUTION(S) TO WHICH THE WORK IS ATTRIBUTED:**

Dept of Pathology, GSVM Medical College, Kanpur.

**NAME, ADDRESS, PHONE, E-MAIL ID OF THE CORRESPONDING AUTHOR:**

Dr. Usha Dubey, Dept of Pathology, G.S.V.M. Medical College, Kanpur-208002

Email: ushadubey@ymail.com, Phone: 9307667575

**DECLARATION ON COMPETING INTERESTS:** No competing Interests

Date of Submission: **Jan 19, 2011**  
Peer Review Completion: **Mar 04, 2011**  
Date of Acceptance: **Mar 19, 2011**  
Date of Publication: **Apr 11, 2011**