

# Clinical and Functional Significance of the Anomalous Insertion of the Brachialis into the Radial Tuberosity: A Case Report

MUTHU KUMAR T. SRIMATHI, ANANDA RANI V.S., AZHAGIRI R.

## ABSTRACT

The brachialis is a muscle of the front of the arm. It is a powerful flexor of the elbow. It gets originated from the lower half of the shaft of the humerus, becomes tendinous and gets inserted into the ulnar tuberosity and the coronoid process of the ulna. In an adult male cadaver, we found an accessory brachialis muscle which originated from the lateral intermuscular septa, blended with the main bulk of the muscle and both got inserted into the

radial tuberosity. The insertion of the brachialis into the radial tuberosity has been minimally reported in the Indian literature. Because of its insertion into the radial tuberosity, the ulnar component of the flexion of the elbow joint is minimal. The accessory muscle and its insertion narrows the space in the cubital fossa, they compress the median nerve, the brachial artery and the radial artery and they can cause neuro-vascular symptoms.

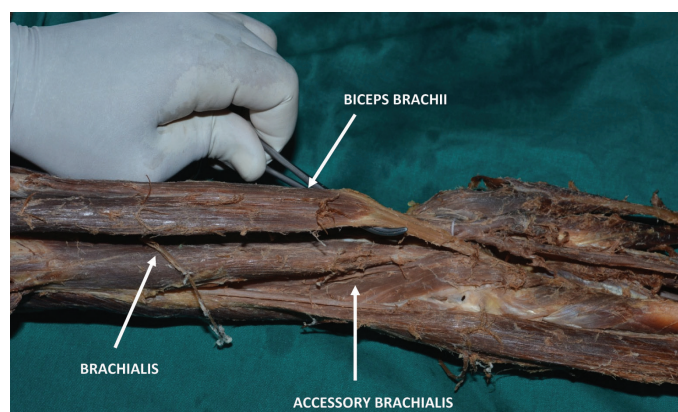
**Key Words:** Brachialis, Radial tuberosity, Median nerve, Brachial artery

## INTRODUCTION

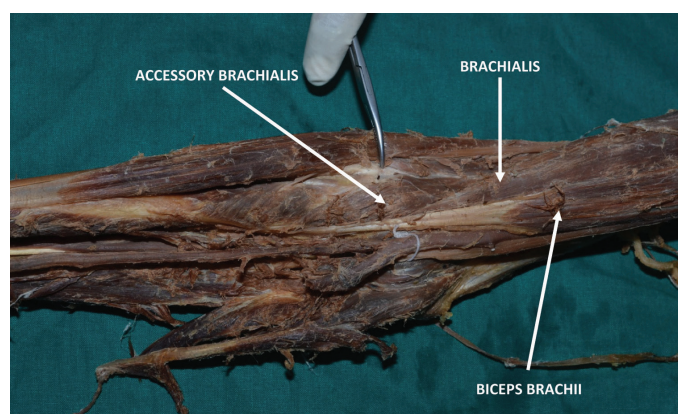
The brachialis is a large muscle of the front of the arm. It usually originates from the anteromedial and the anterolateral surfaces of the distal half of the shaft of the humerus, distal to the insertion of the deltoid muscle. Some fibres also originate from the medial intermuscular septa [1]. Between the brachialis and the biceps brachii muscle passes the musculocutaneous nerve. The muscle then crosses the cubital fossa, becomes tendinous and gets inserted chiefly into the ulnar tuberosity and into the anterior surface of the coronoid process of the ulna. It is a powerful flexor of the elbow joint and because of its prime function in the elbow, it is often referred to as the workhorse of the elbow joint [2]. The main motor supply of the muscle is the musculocutaneous nerve, which is the nerve of the front of the arm. It also receives few fibres from the radial nerve for proprioception. Variations in the brachialis muscle are common in the form of additional slips of origin, insertion into the ante-brachial fascia, etc., but its anomalous primary insertion into the radial tuberosity has rarely been reported in the literature.

## CASE REPORT

During the routine cadaveric dissection of the upper limb for the first MBBS students in the Department of Anatomy, Sri Ramachandra Medical College and Research Institute, Sri Ramachandra University, in an upper limb of an adult cadaver, we found the brachialis originating from the anteromedial and the anterolateral surfaces of the distal half of the shaft of the humerus and also from the medial inter-muscular septum. The accessory brachialis muscle was present [Table/Fig-1], taking origin from the anterolateral surface of the shaft of the lower humerus and also from the lateral intermuscular septum. The accessory brachialis muscle blended with the main brachialis muscle, it crossed the cubital fossa and both the main muscle and the accessory muscle blended with the tendon of the biceps and got inserted into the posterior aspect of the radial tuberosity [Table/Fig-2].



**[Table/Fig-1]:** Figure showing biceps, brachialis and accessory brachialis muscles



**[Table/Fig-2]:** Figure showing accessory brachialis along with brachialis blends with biceps for their insertion into radial tuberosity

## DISCUSSION

Leonella et al [3], in his study of the brachialis through loupe magnification, described two heads of origin of the brachialis, the superficial head and the deep head. The superficial head was larger and proximal and it was inserted into the ulnar tuberosity. The deep head was smaller and distal and it was attached to the

coronoid process of the ulna. Hatice Tuba et al [4], in his MRI study on cadaveric upper limbs, described the two heads of origin of the brachialis, the superficial and deep and all the specimens showed their insertion into the ulnar tuberosity and into the coronoid process of the ulna. There was no communication between the biceps and the brachialis and also with the joint capsule. Benjamin et al [5], in his histological study on the insertion of the brachialis, described that the coronoid process of the ulna, which was the main site of attachment of the brachialis, contained more cortical tissue, as it played a very important role in the mechanical stabilization of the elbow joint. In the present study, there were no separate superficial and deep heads of origin of the brachialis.

Loukas et al [6], described the accessory brachialis from the mid shaft of the humerus and from the medial inter-muscular septa which compressed the median nerve and the brachial artery inserted into the fascia which covered the flexors of the ante brachial compartment. Pai et al [7] described the accessory brachialis which originated from the lateral aspect of the brachialis and the lateral intermuscular septa inserted in the form of a tendon which splitted into two slips. The medial slip crossed the ulnar artery and merged with the deep fascia which covered the pronator teres and the lateral slip blended with the fascia which covered the supinator. Vandhana Mehta [8] described the anomalous origin of the accessory brachialis which originated from the shaft of the humerus, close to the inter tubercular sulcus. Proximally, the tendon expanded into an aponeurosis that blended with the pectoralis major. Rajinigandha Vadgoankar et al [9] and Biswas et al [10], described the accessory brachialis from the medial supracondylar ridge, which compressed the neurovascular structures which were inserted into the fascia which covered the common flexor origin. In this case, the accessory muscle originated from the lateral surface of the shaft of the humerus and the lateral intermuscular septa. The accessory slip compressed the median nerve and the brachial artery blended with the main muscle and they got inserted into the radial tuberosity.

The clinical significance here, is the compression of the median nerve, leading to entrapment neuropathy and the compression of the brachial and the radial arteries, leading to vascular symptoms [11].

In the present case, instead of its usual insertion into the ulna, the insertion of the brachialis into the posterior aspect of the radial tuberosity, compromises the ulnar component of the elbow flexion. The insertion of the biceps brachii into the posterior aspect of the radial tuberosity makes it a powerful supinator [12]. However, in the present case, the biceps inserted anteriorly and the brachialis inserted posteriorly, which made the biceps a weak supinator.

## REFERENCES

- [1] Williams PL, Dyson M. *Gray's Anatomy*. 37th edition. ELBS and Churchill Livingstone;p61.
- [2] Moore KL. *Clinically oriented anatomy*. 3rd edition. Williams and Wilkins;p54.
- [3] Leonello DT, Galley IJ, Bain GI. The brachialis muscle anatomy- A study in cadavers. *Journal of Bone and Joint Surgery*. 2007;89:1293.
- [4] Sanal TH, Chen L, Negrao P. Distal attachment of the brachialis muscle: an anatomic and MRI study in cadavers. *American Journal of Radiology*. 2009 Feb;19(2):468.
- [5] Benjamin M, Newell RLM, Ejevans. A study of the insertion of the tendon of the biceps brachii, the triceps and the brachialis in elderly dissection room cadavers. *Journal of Anatomy*;1992;180:327.
- [6] Lukas M, Louis RG Jr. A case of an accessory brachialis muscle. *Clinical Anatomy*. 2006 Sept; 19;6:550.
- [7] Pai MM, Nayak SR, Vadgaonkar R. Accessory brachialis muscle: a case report. *Morphologie* 2008 (Mar); 92:296
- [8] Mehta V, Suri RK, Arora J, Rath G. Peculiar tendinous origin of the brachialis muscle: an anatomic and clinical insight. *Romanian Journal of Morphology and Embryology*. 2009; 50(1):141
- [9] Vadgaonkar R, Rai R, Ranade AV, Nayak SR, Pai MM, Lakshmi R. A case report on the accessory brachialis muscle. *Romanian Journal of Morphology and Embryology* 2008;49(4):581
- [10] Biswas S, Adhigari A, Kundu P. Variations in the cubital fossa. *International Journal of Anatomical Variations*, 2010;3:122
- [11] Krishnamurthy A, David S, Bagoji IB. The accessory brachialis muscle associated with a high division of the brachial artery. *International Journal of Anatomical Variations*, 2010; 3:160
- [12] Romanes GJ. *Cunningham's Manual of Practical Anatomy*. 15th edition:vol.1. Oxford University Press; p71

### AUTHOR(S):

1. Dr. Muthu Kumar T.
2. Dr. Srimathi
3. Dr. Ananda Rani V.S.
4. Dr. Azhagiri R.

### PARTICULARS OF CONTRIBUTORS:

1. MD, Associate professor, Sri Ramachandra Medical College and Research institute, Sri Ramachandra university, Chennai, India.
2. MD, Assistant professor, Sri Ramachandra Medical College and Research institute, Sri Ramachandra university, Chennai, India.
3. MS, Associate professor, Sri Ramachandra Medical College and Research institute, Sri Ramachandra university, Chennai, India.

4. MD, Assistant professor, Sri Muthukumar Institute of Medical Sciences, Mangadu, Chennai, India.

### NAME, ADDRESS, TELEPHONE, E-MAIL ID OF THE CORRESPONDING AUTHOR:

Dr. Muthu Kumar T.

Department of anatomy

Sri Ramachandra Medical College and Research institute

Sri Ramachandra University, Porur, Chennai – 600116

Tamil Nadu, India.

Phone :9840467452

E-mail: godmuthulakshmi74@yahoo.co.in

### FINANCIAL OR OTHER COMPETING INTERESTS:

None.

Date of Submission: **Oct 27, 2011**

Date of Peer Review: **Dec 08, 2011**

Date of Acceptance: **Jan 14, 2012**

Date of Publishing: **Feb 15, 2012**