

Energy Status And Metabolism in Intracranial Space Occupying Lesions: A Prospective ^{31}P Spectroscopic Study

RAVINDRA BHIMRAO KAMBLE¹, JAYAKUMAR PERUVUMBA N², RAVISHANKAR SHIVASHANKAR³

ABSTRACT

Aim: Intracranial space occupying lesions can be infective or tumour. There are various advanced Magnetic resonance imaging techniques like perfusion, diffusion and proton spectroscopy which can differentiate between them. However, ^{31}P Phosphorus spectroscopy studies the energy status and the metabolism pattern of various tissues and can be used potentially to differentiate between them depending on their Metabolism pattern. Thus, we aimed to study energy status of various intracranial lesions and try to differentiate between them including grades of gliomas.

Materials and Methods: ^{31}P PMRS was done in 1.5T MRI in 43 patients prior to surgery or through/via stereo-tactic biopsy, of which 25 were men and 18 women with mean age 41.34 y ranging from 7-71 y. Single voxel phosphorus spectroscopy was done from the solid portion of the lesions and data was analysed and post processed.

Results: Study includes Lymphoma (n=6), Grade 1 and 2 glioma

(n=5), grade 3 glioma (n=9), grade 4 glioma(n=6), metastases (n=5), tuberculoma (n=7) and pyogenic abscesses (n=5). The integral values of PME, Pi, PDE, γ -ATP, α -ATP, β -ATP with reference to the position of PCr were calculated along with various ratios. Integral values of Pi and PDE were significantly increased in metastases but decreased in gliomas grade 1-2 compared to other pathologic conditions. Mean integral values of LEP (low energy phosphates) and total phosphates were significantly decreased in gliomas grades 1 and 2 and increased in metastases when compared with other pathologic conditions. PCr/Pi was increased in glioma grades 1, 2 and 3 but decreased in metastases; the significance was observed only in gliomas grade 3 and metastases. Metabolic ratios of PDE/ β ATP and Pi/ β ATP were decreased in glioma grades 1 and 2 and increased in metastases with statistical significance.

Conclusion: ^{31}P PMRS may help in differentiating primary from secondary lesions and assess grades of gliomas.

Keywords: Brain, Mass lesions, Phosphorus spectroscopy

INTRODUCTION

Imaging features of various intracranial space occupying lesions overlap on routine imaging techniques. However, advanced MRI techniques like proton MR spectroscopy and perfusion helps in differentiating between them [1,2]. However, other approach to study and characterise various intracranial mass lesions would be to study their energy status and metabolic profile. In vivo ^{31}P phosphorus MR spectroscopy is a tool to study phosphorus metabolism of tissues and tumours. It detects various metabolites like Phosphomonoesterase (PME), Phosphodiesterase (PDE), inorganic phosphates (Pi), Phosphocreatine (PCr), adenosine triphosphate (ATP) and their ratios like PME/PDE, PME/PCr etc which can be used to characterise tumours. These values may be potentially useful by complimenting the findings of other diagnostic modalities like proton spectroscopy [3-5].

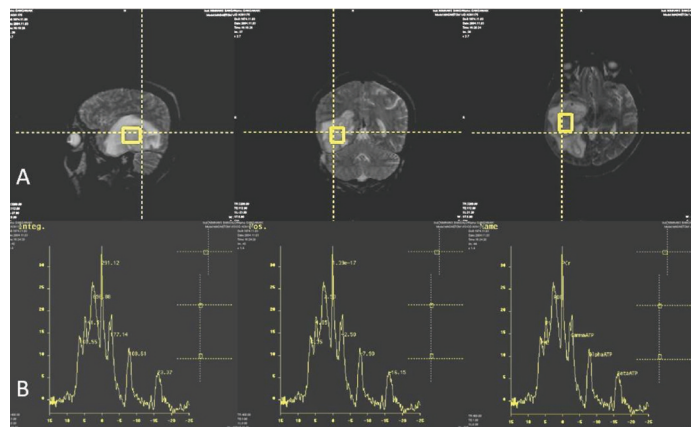
We prospectively studied in-vivo ^{31}P phosphorus spectroscopy in various intracranial space occupying lesions and tried to differentiate between them depending on their energy metabolism and also to grade gliomas.

MATERIALS AND METHODS

Consecutive 43 patients over a period of one year from January 2005 to January 2006 who underwent either stereo-tactic biopsy or surgery for diagnosis were studied. Twenty five were men and 18 were women in the age group of 7 to 71 y (mean=41.34 y). The pathologies included neoplastic conditions like lymphoma (n=6), grade 1 & 2 glioma (n=5), grade 3 glioma (n=9), grade 4 glioma (n=6), metastases (n=5) and non-neoplastic conditions like tuberculoma (n=7) and pyogenic abscess (n=5). All the patients underwent routine MRI imaging after informed consent using SET1W (672/12/1) and TSET2W(4800/22,90/1) sequences in three orthogonal planes using

1.5 T superconducting MR equipment. All the patients underwent single voxel *in-vivo* ^{31}P MR spectroscopy (TR = 400ms, TE=1ms, 512 acquisitions) using intravoxel in-vivo spectroscopy localization method with head quadrature dual-tuned coil. Care was taken to include mainly the solid portion of the lesion in the MRS voxel which ranged from 2 cm^3 - 4 cm^3 . The duration of spectroscopy examination was about 5 min. Spectroscopy data were transferred to an installed software programme (Numaris spectroscopy analysis package VB33A). All post-processing techniques like apodization, zero and first order phase corrections were performed and spectra were plotted, analyzed and fitted to Lorentzian lines shapes.

The following well resolved phosphorus metabolite peaks were observed in all patients- Phosphomonoesters (PME), Inorganic phosphate (Pi), Phosphodiesters (PDE), Phosphocreatine (PCr), γ , β , and α resonances of adenosine triphosphate (ATP). The chemical



[Table/Fig-1]: A- localizer of ^{31}P PMRS in sagittal, coronal and axial sections. B- Spectral maps of integral values(left), position(center) and name of metabolites(right)

	PME	Pi	PDE	PCr	γ ATP	α ATP	β ATP	HEP	LEP	Total phosphates
Glioma grade 1&2	127.62±42.62	59.30±25.04	419.09±95.09	226.04±47.19	119.40±16.63	86.88±11.09	65.41±15.43	497.75±55.61	606.02±124.11	1103.77±144.82
Glioma grade 3	189.63±59.29	96.7±35.21	591.15±108.23	263.76±52.77	150.40±15.02	114.94±22.56	72.16±12.25	601.28±82.10	877.48±154.81	1478.76±182.83
Glioma grade 4	188.72±59.26	108.95±27.91	594.66±102.71	222.05±31.13	148.17±16.30	102.60±13.90	82.31±14.87	555.14±46.31	892.33±176.22	1447.48±211.68
Lymphoma	159.22±34.26	95.37±26.78	626.12±89.79	262.71±24.29	154.96±11.86	99.17±40.44	79.45±8.73	596.30±54.73	880.73±123.63	1477.03±106.64
Metastases	172.43±90.95	153.95±24.24	811.9±334.04	324.1±134.88	182.55±63.60	127.73±53.53	74.83±15.94	709.22±264.43	1138.28±433.72	1847.51±698.06
Tuberculoma	155.84±66.66	117.37±39.52	649.67±37.76	224.10±49.03	153.13±11.24	106.71±10.69	85.68±4.29	589.62±62.58	922.89±102.86	1512.52±123.92
Abscess	180.33±34.63	113.26±36.89	649.46±126.66	249.01±70.99	153.61±34.86	95.51±31.11	78.86±11.46	577±142.32	943.06±172..57	1520.06±314.33

[Table/Fig-2]: Mean and standard deviation of integral values of metabolites, high energy phosphates, low energy phosphates and total phosphates

	PME/ PDE	PDE/ β ATP	PCr/ β ATP	HEP/LEP	β ATP/Pi	Pi/ β ATP	PCr/Pi.
Glioma grade 1&2	0.31±0.11	6.48±0.99	3.75±1.67	0.85±0.24	1.19±0.34	0.91±0.36	4.30±2.08
Glioma grade 3	0.32±0.10	8.22±1.02	3.77±1.13	0.70±0.14	0.81±0.23	1.34±0.44	3.05±1.18
Glioma grade 4	0.31±0.06	7.25±0.62	2.78±0.71	0.63±0.10	0.77±0.12	1.31±0.19	2.15±0.60
Lymphoma	0.25±0.04	7.93±1.26	3.35±0.64	0.69±0.14	0.88±0.27	1.20±0.30	2.99±1.07
Metastasis	0.20±0.04	10.69±2.51	4.26±1.01	0.62±0.01	0.49±0.10	2.10±0.43	2.08±0.66
Tuberculoma	0.23±0.10	7.58±0.40	2.85±0.59	0.64±0.10	0.78±0.19	1.36±0.43	2.28±0.84
Abscess	0.28±0.06	8.21±0.95	3.13±0.71	0.60±0.04	0.76±0.27	1.41±0.40	2.32±0.64

[Table/Fig-3]: Mean and standard deviation of metabolites ratios in all pathologic conditions

	glioma Grade1-2	glioma Grade3	glioma Grade4	Lymphoma	Meta-stases	Tuber-culoma	Abs-cess	Stati-stics
PME	↓↓	↑↑	↑↑	-	↑	-	↑	NS
Pi	↓↓	-	-	-	↑↑	-	-	p=0.003
PDE	↓↓	-	-	-	↑↑	-	-	p=0.011
PCr	↓↓	-	↓↓	-	↑↑	-	-	NS
β ATP	↓↓	-	↑↑	-	-	↑↑	-	NS
PME/PDE	-	↑↑	-	-	↓↓	-	-	NS
PCr/Pi	↑↑	↑	-	-	↓↓	-	-	p=0.028
PDE/ β ATP	↓↓	-	-	-	↑↑	-	-	p=0.000
LEP	↓↓	-	-	-	↑↑	-	-	p=0.015
HEP/LEP	↑↑	↑	-	-	-	-	↓↓	NS
PCr/ β ATP	-	-	↓↓	-	↑↑	↓↓	-	NS
β ATP/ Pi	↑↑	-	-	-	↓↓	-	-	p=0.004
Pi / β ATP	↓↓	-	-	-	↑↑	-	-	p=0.002
Total phos.	↓↓	-	-	-	↑↑	-	-	p=0.027

[Table/Fig-4]: Statistics of various metabolites and metabolite ratios in all pathologic conditions, ↓ - low, ↓↓ - very low, ↑ - high, ↑↑ - very high and NS- not significant

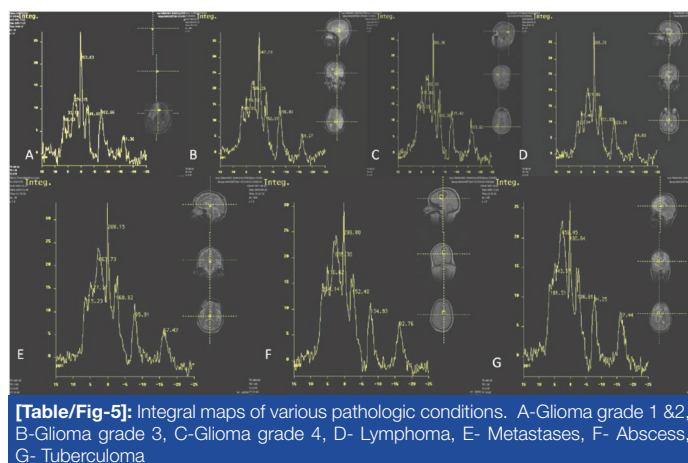
shifts of these metabolites were as follows: PME = 7.1 ppm, Pi = 5.3 ppm, PDE = 3.6 ppm, γ -ATP = -2.4 ppm, α -ATP = -7.7 ppm, β -ATP = -16.1 pp, referenced to the position of PCr at 0 ppm. Peak integral values of all metabolites were obtained. PCr and total ATP ($\gamma + \alpha + \beta$) represented high energy phosphates (HEP) and PME, PDE & Pi constituted low energy phosphates (LEP). The sum of integral values of all metabolites was calculated as total phosphates. Various metabolite ratios like PME/PDE, PCr/ β ATP, PDE/ β ATP, HEP/LEP, Pi/ β ATP, β ATP/Pi and PCr/Pi were also calculated.

STATISTICAL ANALYSIS

Statistical one-way Analysis Of Variance (ANOVA) with post hoc procedure of student-Newman-Keuls was performed between the groups. A p-value less than 0.05 was considered significant.

RESULTS

[Table/Fig-1A,B] shows 31 P MRS of a patient showing localiser. [Table/Fig-2] shows mean and standard deviation of integral values of all metabolites in the pathologies and [Table/Fig-3] shows mean and standard deviation of metabolic ratios. [Table/Fig-4] shows statistics of various metabolites and metabolite ratios in all pathologies. [Table/Fig-5] shows spectral maps of various lesions.



[Table/Fig-5]: Integral maps of various pathologic conditions. A-Glioma grade 1 & 2, B-Glioma grade 3, C-Glioma grade 4, D- Lymphoma, E- Metastases, F- Abscess, G- Tuberculoma

Significant findings include; Mean integral values of Pi and PDE were significantly increased in metastases but decreased in gliomas grade 1-2 compared to other pathologic conditions. Mean integral values of LEP and total phosphates were significantly decreased in gliomas grades 1 and 2 and increased in metastases when compared with other pathologic conditions. PCr/Pi was increased in glioma grades 1,2 and 3 but decreased in metastases; the significance was observed only in gliomas grade 3 and metastases. Metabolic ratios of PDE/ β ATP and Pi/ β ATP were decreased in glioma grades 1 and 2 and increased in metastases with statistical significance.

DISCUSSION

In-vivo 31 P MRS is an established technique for evaluating tumours of extremity, head, neck and liver [5-9]. It allows non invasive characterization of phosphate containing compounds within tumour cells and determination of energy status and pH [9-11]. It basically reflects three fundamental processes of the cell; like bioenergetics, cell membrane phospholipid turnover and intracellular pH. The phosphate metabolites imaged are probably intracellular as the extra cellular concentration of these metabolites is negligible [12]. The integral values obtained of each metabolites are not absolute but relative [4] and thus various metabolite ratios are used like PME/PDE, PDE/ATP, PCr/ATP etc in various studies [5, 13].

Phosphocholine and phosphoethanolamine are the main components of PME [14] and suggests cytoplasmic membrane synthesis and are intermediates in phosphoglycerides biosynthesis [15]. Our study showed reduced PME in low grade glioma

compared to rest of the group (statistically insignificant) probably due to increased cell turnover in the tumours [16]. High PME was observed in abscess compared to low grade glioma, probably due to presence of inflammatory cells and cellular turnover. A relationship between the elevated phospholipid precursors of Phosphocholine, phosphoethanolamine and cell proliferation in cancers has been suggested to signify an increased membrane turnover or increased phospholipase activity [6,12].

PDE contains mobile phospholipid compounds such as glycerol-3-phosphoethanolamine and glycerol-3-phosphocholine which contributes to cell wall structure and increased resonance indicates the presence of breakdown products of membrane metabolism [15,17]. Statistically significant increase in PDE was found in metastases and decrease in low grade glioma compared to rest of the lesions in our study.

This finding was in contradiction with earlier reports of Hiendel et al., and Arnold et al., who found low PDE in metastasis and high grade glioma [18,19]. Arnold et al., explained the low levels of PDE in their study due to contamination from adjacent normal brain parenchyma [19]. In addition, contrary to Arnold et al., findings we found significant difference of PDE between high grade and low grade gliomas. However, we did not find statistically significant difference in PME/PDE ratio in any of the group. Previous studies have found significantly high PME/PDE ratio in astrocytoma, metastases and lymphoma compared to controls [13]. But these findings are variable and have limitations as previous studies had also shown increase in both PME and PDE in most tumours , proliferating tissues like regenerating liver, benign tumours and embryo [5].

Free intracellular inorganic phosphates constitute the Pi resonance [20] and is produced from ATP which hydrolyzes to ADP and Pi, liberating large amount of free energy for cell functions [12]. This was found to be increased in conditions of hypoxia [21]. Significant high levels of Pi in metastases compared with other pathologies were probably due to presence of hypoxia. We also found high levels of PDE in metastases which suggested necrosis with hypoxia. The same metabolite was significantly low in grade 1, 2 gliomas.

PCr solely represents phosphocreatine molecule and is taken as chemical shift reference at 0 ppm and is pH independent [22]. Hubsch et al., have shown that in necrotic tissue, PCr is reduced and Pi is increased [23]. Animal studies have also shown that ischemia caused increase in Pi, ADP, AMP and decrease in ATP and PCr which were reversible with reperfusion [24]. We did not find any significant change in PCr levels across pathologies. This may suggest that the tumours including inflammatory lesions in our study were prevailing in the same state of energy at that point of examination.

However, PCr/Pi ratio (statistically significant) was low in metastases and high in grade 1-2 glioma as compared to other lesions. This can be attributed to increase in Pi due to hypoxia and necrosis in metastases but increase in PCr in metastases cannot be explained. PCr/Pi ratio can change rapidly during physiological stress and is proportional to phosphorylation [12]. It is called (thermo-dynamic) energy potential of the cell. We found significant reduction in metastases due to high levels of Pi in necrosis. This ratio was not different in various grades of gliomas similar to Arnold et al findings [19]. Significant increased ratio of PDE / β ATP in metastases may be attributed to increase in PDE from degraded cell membranes from accelerated catabolism [1,25,26].

For the same reason β ATP/Pi ratio was significantly reduced in metastases. This may suggest that metastases are more hypoxic than other pathologies.

Ha et al., had shown significantly lower ratios of PME/PCr and PDE/PCr in lymphoma compared to astrocytoma group thus differentiating them. However we did not find these changes [13].

β ATP contains only β phosphate of ATP and is often used as ATP reference for peak ratios. All cellular activities including membrane

transport and protein synthesis require energy supplied in the form of high energy phosphate bonds of ATP. When ATP is hydrolyzed to ADP and Pi, large amount of free energy is liberated. It is the index of energy reserve of the cell and is called phosphorylation potential [12]. The other sources of ATP are glycolytic pathway in anaerobic conditions, adenylate kinase reaction and creatine kinase reaction, the last being present only in excitable tissues (muscle, neurons) [27]. Tuberculoma and high grade glioma show higher levels of β ATP when compared to other pathologies in our study but was not statistically significant. This could be due to presence of more inflammatory cells in tuberculoma and high levels of lipid and glycogen in grade 4 glioma [25].

Tuberculomas are also hypoxic due to caseation and arteritis process occurring in and around the granuloma leading to poor energy status [28]. Thus a hypoxic internal milieu could contribute to Pi in inflammatory and neoplastic lesions and a significant overlap in energy ratios between these lesions [25].

High grade tumours and inflammatory/infective lesions such as tuberculomas and abscesses could not be differentiated based on energy status. Abscesses have mature collagen with lack of neovascularity which lead to hypoxia [29]. In present study abscess had lower ratio of HEP/LEP but was not statistically significant. It may be due to increase in LEP and Pi due to hypoxia.

However, HEP in our study did not demonstrate significant difference across pathologies but was low in low grade gliomas and high in metastases.

Tumours may have acidic pH due to hypoxia or alkaline pH due to good oxygenation. pH is influenced by ionic strength, metal ion binding, temperature and buffering action of tumour cells. Technical drawbacks in evaluation of pH peaks include contamination and difficulty to separate Pi and PCr resonances. Also tumours demonstrate a wide range of pH within them. Thus, pH may not be useful in determining the types of tumours [6,24]. Our study showed pH of all pathologies tending towards the acidic range, the values were not statistically significant to differentiate the grade or types of tumours and non-neoplastic lesions.

CONCLUSION

Increase in Pi and PDE in metastases and decrease in grade 1-2 glioma and corresponding ratios like PDE/ β ATP , Pi/ β ATP and PCr/ Pi can be useful marker in differentiating low grade glioma from high grade glioma and primary from secondary. Energy profiles of inflammatory lesions and neoplastic lesions are similar and they may not be differentiated based on energy ratios alone.

ACKNOWLEDGMENT

We acknowledge the efforts done to get the cases from Department of Neurosurgery and Neurology, NIMHANS and the technical staff of Department of Neuroradiology.

REFERENCES

- [1] Hartmann WM , Herminghaus S, Krings T, Marquardt G, Lanfermann H, Pilatus U. Clinical application of proton magnetic resonance spectroscopy in the diagnosis of intracranial mass lesions. *Neuroradiology*. 2002;44:371-81.
- [2] Cho SK, Na DG, Ryoo JW, Roh HG, Moon CH, Byun HS, et al. Perfusion MR Imaging: Clinical utility for the Differential Diagnosis of Various Brain Tumours. *Korean Journal Of Radiology*. 2002;3(3):171-79.
- [3] Park JM, Park JH. Human in-vivo 31P MR spectroscopy of benign and malignant breast tumours. *Korean J Radiol*. 2001;2:80-86.
- [4] Cohen JS. Phospholipid and energy metabolism of cancer cells monitored by 31P magnetic resonance spectroscopy: possible clinical significance. *Mayo Clin Proc*. 1988;63:1199-207.
- [5] Maintz D, Heindel W, Kugel H, Jaeger R, Lackner KJ. Phosphorus-31 MR spectroscopy of normal adult human brain and brain tumours. *NMR Biomed*. 2002;15:18-27.
- [6] Negendank WG, Crowley M, Ryan JR, Keller NA, Evenhock JL. Bone and soft-tissue lesions: diagnosis with combined H-1 MR imaging and P-31 MR spectroscopy. *Radiology*. 1989;173 (1):181-88.
- [7] Mckenna WG, Lenkinski RE, Hendrix RA, Voegelé KE, Bloch P. The use of magnetic resonance imaging and spectroscopy in the assessment of patients with head and neck and other superficial human malignancies. *Cancer*. 1989;64(10):2069-75.

- [8] Bell JD and Bhakoo KK, et al. Metabolic changes underlying 31P MR spectral alterations in human hepatic tumours. *NMR Biomed.* 1998;11(7):354-59.
- [9] Arnold DL, Shoubridge EA, Emrich JF, Fiendel W, Villemure JG. Early metabolic changes following chemotherapy of human gliomas in vivo demonstrated by phosphorus magnetic resonance spectroscopy. *Invest Radiol.* 1989;24(12):958-61.
- [10] Arnold DL, Shoubridge EA, Fiendel W, Villemure JG. Metabolic changes in cerebral gliomas within hours of treatment with intra-arterial BCNU demonstrated by phosphorus magnetic resonance spectroscopy. *Can J Neurol Sci.* 1987;14:570-75.
- [11] Gillies RJ, Raghunand N, Karczmar GS, Bhujwala ZM. MRI of the tumour microenvironment. *J Magn Reson Imaging.* 2002;16:430-50.
- [12] Cady EB, Hennig J, Martin E. Magnetic Resonance Spectroscopy In Imaging of the central nervous system of neonates Ed by Springer verlag NewYork.
- [13] Ha DH, Choi S, Oh JY, Yoon SK, Kang MJ, Kim KU. Application of 31P MR Spectroscopy to the Brain Tumours. *Korean J Radiol.* 2013;14(3):477-86.
- [14] Albers MJ, Krieger MD, Gonzalez-Gomez I, Gilles FH, McComb JG, Nelson MD Jr, et al. Proton-decoupled 31P MRS in untreated pediatric brain tumours. *Magn Reson Med.* 2005;53:22-29.
- [15] Aisen AM, Chenevert TL. MR spectroscopy: clinical perspective. *Radiology.* 1989;173:593-99.
- [16] Kleihues P and Cavenee WK. Pathology and genetics of tumours of the nervous system. *IARC press. Lyon, 2000.*
- [17] Podo F. Tumour phospholipid metabolism. *NMR Biomed.* 1999;12:413-39.
- [18] Heindel W, Bunke J, Glathe S, Steinbrich W, Mollevanger L. Combined 1H-MR Imaging and localized 31P-Spectroscopy of intracranial tumours in 43 Patients. *J Comput Assist Tomogr.* 1988;12(6):907-16.
- [19] Arnold DL, Emrich JF, Shoubridge EA, Villemure JG, Fiendel W. Characterization of astrocytomas, meningiomas, and pituitary adenomas by phosphorus magnetic resonance spectroscopy. *J Neurosurg.* 1991;74(3):447-53.
- [20] Petroff OA, Prichard JW, Behar KL, Alger JR, den Hollander JA, Schulman RG. Cerebral intracellular pH by 31p nuclear magnetic resonance spectroscopy. *Neurology.* 1985;35(6):781-88.
- [21] Steen G. Characterization of tumour hypoxia by 31P MR spectroscopy. *AJR.* 1991;157:243-48.
- [22] Jacobus WE, Pores IH, Lucas SK, Kallman CH, Weisfeldt ML, Flaherty JT. The role of intracellular pH in the control of normal and ischemic myocardial contractility: a 31P nuclear magnetic resonance and mass spectrometry study. *Kroc Found Ser.* 1981;15:537-65.
- [23] Hubesch B, Sappey-Mariniere D, Roth K, Meyerhoff DJ, Matson GB, Weiner MW. P-31 MR Spectroscopy of normal human brain and brain tumours. *Radiology.* 1990;174(2):401-09.
- [24] Kopp SJ, Kriegelstein J, Freidank A, Rachman A, Seibert A, Cohen MM. P-31 Nuclear Magnetic resonance analysis of brain: II Effects of oxygen deprivation on isolated perfused and nonperfused rat brain. *J. Neurochem.* 1984;43(6):1716-31.
- [25] Lowry OH, Berger SJ, Chi MM, Carter JG, Blackshaw A, Outlaw W. Diversity of metabolic patterns in human brain tumours-1. High energy phosphate compounds and basic composition. *Journal of Neurochemistry.* 1977;29(6):959-77.
- [26] Opstad KS, Murphy MM, Wilkins PR, Bell BA, Griffiths JR, Howe FA. Differentiation of metastases from high grade gliomas using short echo time 1H spectroscopy. *J Magn Reson Imaging.* 2004;20(2):187-92.
- [27] Erecinska M, Silver IA. ATP and brain function. *J Cereb blood flow metab.* 1989;9(1):2-19.
- [28] Dastur DK, Dave UP. Ultrastructural basis of the vasculopathy in and around brain tuberculomas. Possible significance of altered basement membrane. *Am J Pathol.* 1977;89(1):35-50.
- [29] Holmes TM, Petrella JR, Provenzale JM. Distinction between Cerebral Abscesses and High-grade Neoplasms by Dynamic Susceptibility Contrast Perfusion MRI. *AJR.* 2004; 183(5):1247-52.

PARTICULARS OF CONTRIBUTORS:

1. Head of Department, Department of Radiology, Bangalore, Karnataka, India.
2. Head of Department, Department of Radiology, Muscat, Oman.
3. Consultant Radiologist, Department of Radiology, Baltimore, Maryland.

NAME, ADDRESS, E-MAIL ID OF THE CORRESPONDING AUTHOR:

Dr. Ravindra Bhimrao Kamble,
Head of Department, Department of Radiology, First Floor, Vikram Hospital, Millers Road, Bangalore-560052, India.
Phone : 9845781307, E-mail : drravindra31@rediffmail.com

FINANCIAL OR OTHER COMPETING INTERESTS: None.

Date of Submission: **Jun 07, 2014**
Date of Peer Review: **Aug 18, 2014**
Date of Acceptance: **Sep 13, 2014**
Date of Publishing: **Nov 20, 2014**