

Fracture of the Medial Tibial Sesamoid Bone of the Foot-Case Report

RAVI MAHALINGAPPA DADDIMANI¹, SRINATH KADAGATTUR MADHAVAMURTHY², SANTOSH SOMAYYA JEEVANNAVAR³, CHIDENDRA MANOHAR SHETTAR⁴

ABSTRACT

The sesamoid bone ligament complex of foot contains two sesamoid bones one medial tibial sesamoid and other lateral fibular sesamoid bone, both embedded in the plantar ligament beneath first metatarsal head. The incidence of medial tibial sesamoid bone fracture is rare. Clinically they are often misdiagnosed as soft tissue injuries and often missed. We present a case of fracture medial tibial sesamoid bone in a young athlete who was diagnosed radiologically and treated conservatively with activity restriction and foot wear modification. Our case draws attention to this easily treatable fracture and outlines the investigative modalities in diagnosing this fracture.

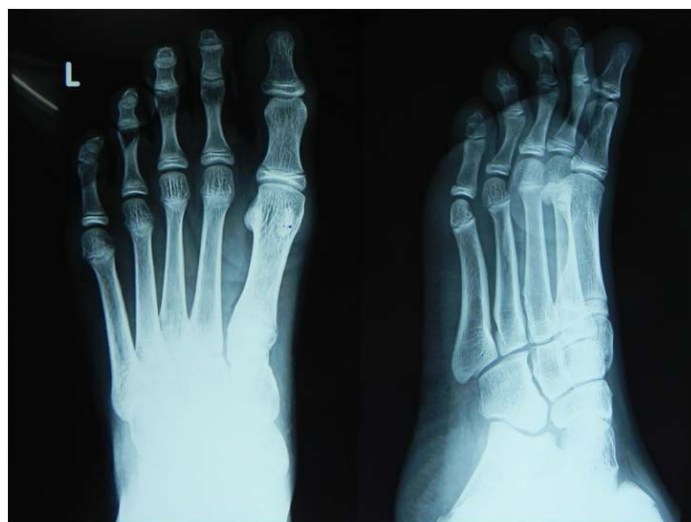Keywords: Bipartite sesamoid, Fracture, Ultrasonography

CASE REPORT

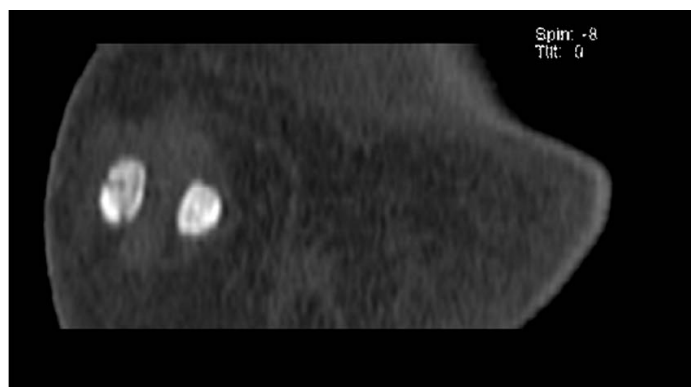
A 16-year-old male cricket player presented with pain in the left foot of two months duration. The pain was insidious in onset with no preceding history of trauma. The pain was aggravated with activities of weight bearing.

On clinical evaluation there was tenderness over the plantar aspect of the first metatarsal head with minimal swelling compared to normal foot [Table/Fig-1]. Pain and tenderness was aggravated on extending the great toe and on weight bearing. No distal neurovascular deficits were seen. Clinical diagnosis of soft tissue injury was done and radiographs ordered to rule out any bony injury. Radiographs of the foot revealed a fracture of the medial sesamoid bone [Table/Fig-2]. However, as fracture of the medial sesamoid bone is rare and bipartite sesamoid is a known entity, we decided to further investigate.

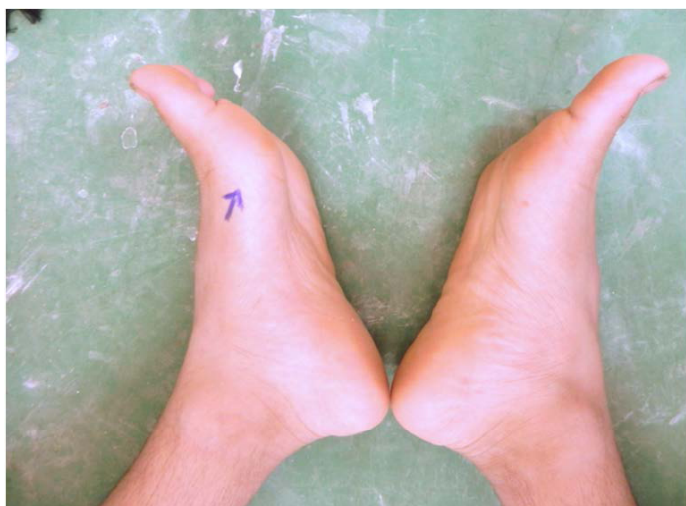A CT scan of the affected foot was done which confirmed the fracture of the medial tibial sesamoid bone [Table/Fig-3]. A comparative HRUSG (high resolution ultrasonography) of both the feet were done to rule out bipartite sesamoid [Table/Fig-4]. As there was a positive clinical correlation between the presenting symptoms and the radiological investigations, a diagnosis of fracture of the medial tibial sesamoid was made.



[Table/Fig-2]: Radiographs of the left foot showing fracture of the medial sesamoid bone

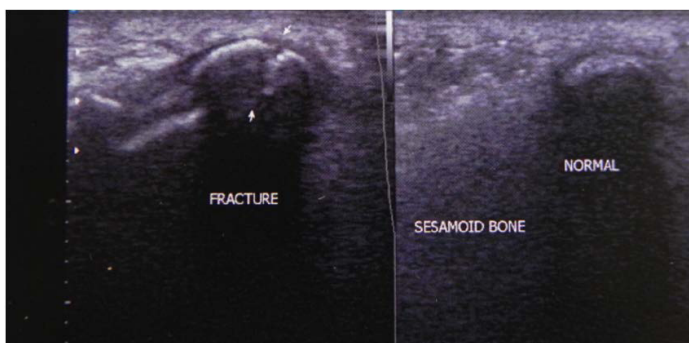


[Table/Fig-3]: CT scan of the foot showing fracture of the medial sesamoid bone

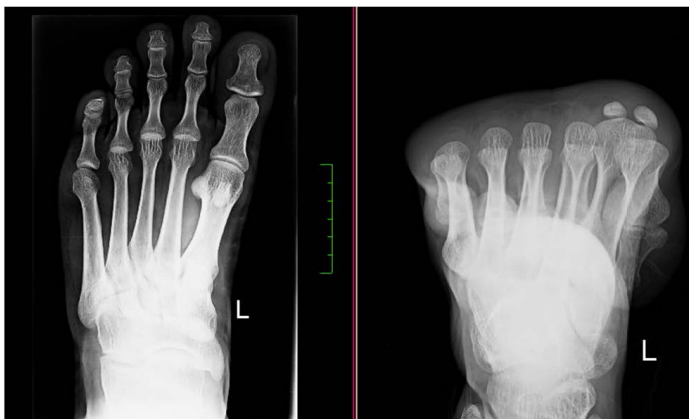

[Table/Fig-1]: Clinical photograph showing swelling overlying the plantar aspect of the first metatarsal head of left foot

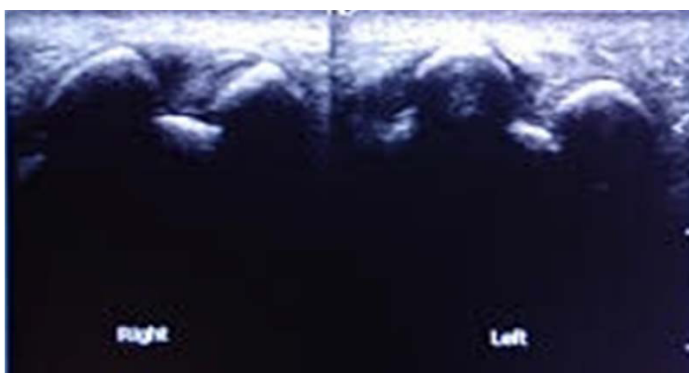
The patient was treated with analgesics, immobilisation and restricted weight bearing for six weeks. The patient's symptom gradually improved and was pain free at the end of six weeks. However, he was advised to avoid sporting activities for further six weeks. At the end of three months a repeat radiograph showed a healed and united fracture of the medial sesamoid bone. The patient was followed up for two years, and at the end of two years patient was asymptomatic repeat radiographs revealed a completely healed fracture of the medial tibial sesamoid.



[Table/Fig-4]: Comparative Ultrasound of the both feet showing normal sesamoid in right foot and fracture of sesamoid bone in the left foot



[Table/Fig-5]: Two years follow up radiographs showing healed fracture of the medial sesamoid bone



[Table/Fig-6]: Follow up HRUSG of both the feet showing healed fracture of medial sesamoid bone of the left foot

DISCUSSION

Medial tibial sesamoid bone fractures are rare and seen occasionally by a treating orthopaedic surgeon. The mechanism of injury is well described in the literature [1-5]. The mechanism of injury in most of the cases is forced hyperextension of the great toe [6,7]. In our case the mechanism of injury was unclear but there was history of repeated micro trauma to the plantar aspect of the affected foot while playing cricket.

Many of these suspected fractures are treated as soft tissue injuries as the radiographs advised are not specific for diagnosis of sesamoid fracture. Even when there are sesamoid fractures they are often missed by the treating surgeon as he is clinically looking for metatarsal and phalanges bone fractures rather than sesamoid fractures. The clinical presentation in our case was more specific to 1st MTP joint as the swelling was obvious [Table/Fig-1]. In our case there was an obvious fracture line seen in the medial tibial sesamoid, however lot of authors have emphasized the importance of recognising high incidence of bipartite medial sesamoids [8,9].

We decided to do a comparative HRUSG comparing both the feet to rule out bipartite sesamoid. HRUSG also showed the fracture line clearly [Table/Fig-4]. HRUSG as a mode to detect sesamoid fractures is not very well described, we feel it's an excellent tool to detect sesamoid fractures in the OPD and so also, in the follow-up after the fracture heals. So we recommend HRUSG as a modality to diagnose and to monitor the healing in case of sesamoid fractures. It also may have a role to differentiate bipartite sesamoid.

In our patient the sesamoid fracture was managed conservatively with activity restriction and NSAIDs apart from shoe wear modification with metatarsal bar. He had an uneventful healing which was confirmed with repeat radiographs [Table/Fig-5] and HRUSG [Table/Fig-6]. He was also followed up for two years and at the end of two years he was asymptomatic and back to his sporting activities. Surgical management of sesamoid bone fractures including internal fixation and excision have been well described in the literature [5,10].

CONCLUSION

Medial sesamoid bone fractures are often missed as they are treated as soft tissue injuries. Specific radiographic views are required to diagnose these injuries. HRUSG is a useful tool both for the diagnosis and to monitor the fracture healing. Congenital bipartite medial sesamoid should be kept in mind while diagnosing fracture of the medial sesamoid bone fracture.

REFERENCES

- [1] Boike A, Schnirring Judge M, McMillin S. Sesamoid disorders of the first metatarsophalangeal joint. *Clin Podiatry Med Surg*. 2011;28(2):269-85.
- [2] Lee DK, Mulder GD, Schwartz AK. Hallux, sesamoid, and first metatarsal injuries. *Clin Podiatry Med Surg*. 2011;28(1):43-56.
- [3] Maskill M, Mendicino R, Saltrick K, Catanzariti A. Traumatic dislocation of the first metatarsophalangeal joint with tibial sesamoid fracture: a case report of a type III B dislocation. *J Am Podiatry Med Assoc*. 2008;98(2):149-52.
- [4] Cohen BE. Hallux sesamoid disorders. *Foot Ankle Clin*. 2009;14(1):91-104.
- [5] Jones JL, Losito JM. Tibial sesamoid fracture in a softball player. *J Am Podiatry Med Assoc*. 2007;97(1):85-8.
- [6] Biedert R, Hintermann B. Stress fractures of the medial great toe sesamoids in athletes. *Foot Ankle Int*. 2003;24(2):137-41.
- [7] Parra E. Stress fractures of the sesamoid. *Clin Orthop*. 1960;18:281-85.
- [8] Dobas DC, Silver MD. The frequency of the bipartite sesamoids of the first metatarsophalangeal joint. *J Am Podiatry Assoc*. 1977;67(12):880-82.
- [9] Frankel J, Harrington J. Symptomatic bipartite sesamoids. *J Foot Surg*. 1990;29:318-23.
- [10] Blundell CM, Nicholson P, Blackney MW. Percutaneous screw fixation for fractures of the sesamoid bones of the hallux. *J Bone Joint Surg Br*. 2002;84(8):1138-41.

PARTICULARS OF CONTRIBUTORS:

1. Assistant Professor, Department of Orthopaedics, SDM College of Medical Sciences and Hospital, Sattur, Dharwad, Karnataka, India.
2. Assistant Professor, Department of Orthopaedics, SDM College of Medical Sciences and Hospital, Sattur, Dharwad, Karnataka, India.
3. Professor, Department of Orthopaedics, SDM College of Medical Sciences and Hospital, Sattur, Dharwad, Karnataka, India.
4. Professor, Department of Orthopaedics, SDM College of Medical Sciences and Hospital, Sattur, Dharwad, Karnataka, India.

NAME, ADDRESS, E-MAIL ID OF THE CORRESPONDING AUTHOR:

Dr. Ravi Mahalingappa Daddimani,
Assistant Professor, Department of Orthopaedics, SDM College of Medical Sciences and Hospital,
Sattur, Dharwad, Karnataka-580025, India.
E-mail: ravidaddimani@gmail.com

FINANCIAL OR OTHER COMPETING INTERESTS: None.

Date of Submission: Jan 07, 2015
Date of Peer Review: Mar 13, 2015
Date of Acceptance: Mar 20, 2015
Date of Publishing: Apr 01, 2015