

# Vasculitis as a Presenting Manifestation of Chronic Hepatitis B Virus Infection: A Case Report

HARPREET SINGH<sup>1</sup>, VIKRAM SINGH TANWAR<sup>2</sup>, GAGANDEEP SUKHIJA<sup>3</sup>, PARMINDER KAUR<sup>4</sup>, NIKHIL GOVIL<sup>5</sup>

## ABSTRACT

Hepatitis B virus is responsible for causing hepatic complications like acute and chronic hepatitis, cirrhosis and hepatocellular carcinoma along with some uncommon immune mediated extrahepatic manifestations. Vasculitis remains an uncommon extrahepatic complication of hepatitis B virus infection. Herein we report a case of hepatitis B infection that presented with leucocytoclastic vasculitis as an initial manifestation and managed successfully with entacavir therapy.

**Keywords:** Extrahepatic manifestations, Entacavir, Leucocytoclastic vasculitis

## CASE REPORT

A 60-year-old male, non-smoker, not a known case of any chronic illness presented in our Medicine OPD with one month history of blackish discoloration of hands and both lower limbs [Table/Fig-1, 2]. There was no history of fever/ cough/ shortness of breath/ haematuria/ loose stools/ loss of appetite/ weight loss/ jaundice/ recent history of any drug intake. On examination all peripheral pulses were well palpable but revealed loss of sensation over the discoloured areas. Rest of the systemic examination was normal including normal blood pressure. Based on clinical history and examinations following differentials were considered: Vasculitis, peripheral vascular disease, anti-phospholipid antibody syndrome (APS).

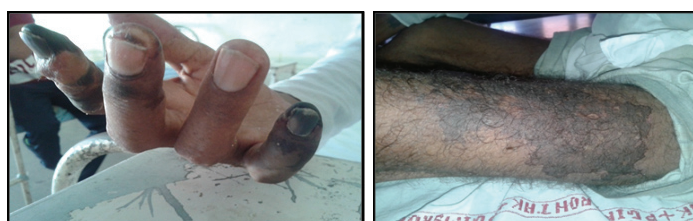On investigation: complete haemogram, renal parameters, urine examination, coagulation profile were normal. Test for Anti nuclear antibody was negative; serum for cryoprecipitates was negative. Liver enzymes were mildly elevated (AST=58U/L; ALT=66U/L); viral serology HIV and Anti HCV were negative. HCV RNA was negative. Hepatitis B profile was abnormal: HBsAg Positive; Anti HBc antibody total was raised (6.51 U/ml), anti HBc IgM titer

was normal (0.76 U/ml), Anti HBc IgG was raised (5.75 U/ml), HBV DNA was highly raised (39200000 IU/ml), HBeAg reactive (1406.62 U/ml). Biopsy from skin lesions revealed leucocytoclastic vasculitis (LCV) [Table/Fig-3]. After ruling out the other possible causes of LCV such as HCV infection, autoimmune disorders, cryoglobulinaemia and lymphoproliferative disorders by relevant investigations as stated above, diagnosis of chronic active hepatitis B associated LCV was entertained.

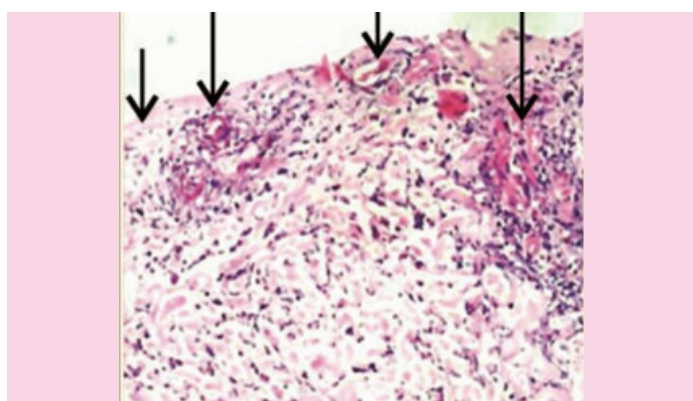
Treatment started was oral Entacavir 0.5mg per day along with oral Prednisolone 30 mg per day. With the treatment, patient showed significant improvement in his symptoms. Two months after the treatment, his serum HBV DNA was undetectable and his vasculitis was less intense with no fresh skin lesion reported [Table/Fig-4,5]. The dose of prednisolone was gradually tapered and was eventually stopped. At the last follow up in September 2015 (after 6 months of entacavir therapy) patient was asymptomatic without appearance of fresh skin lesions.

## DISCUSSION

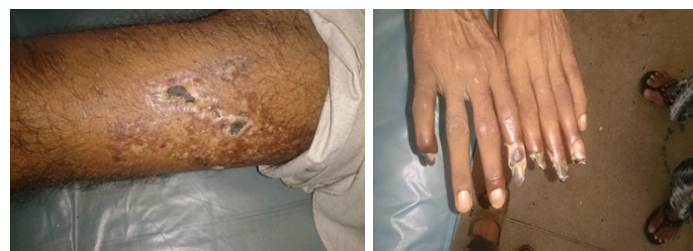Clinical manifestation of hepatitis B virus infection depends on patient's age, immune status at the time of infection and the stage at which disease is recognised. The most common persistent viral infection in human is the chronic HBV infection. Almost 360 million people in the world today are estimated to be persistently infected with HBV and 600,000 die each year from HBV-related liver disease or hepatocellular carcinoma [1]. Acute or chronic HBV infection are known to cause various extrahepatic manifestations which are thought to be immune complex mediated, which in turn lead to aggregation of platelets and activation of Hageman factor, thus initiating inflammatory reactions and microthrombi formation [2]. These complexes are deposited mainly in small arteries, renal glomeruli and the synovial of joints and clinically manifest as vasculitis, nephritis and arthritis [3]. Vasculitis is perhaps the most serious but uncommon extrahepatic manifestation of HBV infection



**[Table/Fig-1]:** Showing blackish discoloration of digits. **[Table/Fig-2]:** Showing cutaneous necrotizing lesions involving both lower limbs.



**[Table/Fig-3]:** Histopathological examination of skin biopsy showing inflammation of postcapillary dermal venules consisting of neutrophils with fragmentation of their nuclei (leucocytoclasia).



**[Table/Fig-4]:** Showing healing of skin lesions on lower limbs after 2 months of treatment. **[Table/Fig-5]:** Showing healing of vasculitic lesions of digits after 2 months of treatment.

[4]. Vasculitides associated with HBV infection are Polyarteritis nodosa [2], Cryoglobulinaemic Vasculitis [5] and Leucocytoclastic Vasculitis [4].

Polyarteritis nodosa (PAN) is an uncommon but life threatening complication of chronic HBV infection, which mainly affects the small and medium-sized vessels [2]. It commonly presents with constitutional symptoms, arthralgias, mononeuritis multiplex, hypertension and nodules in skin. It characteristically does not involve lungs. HBV related Cryoglobulinaemic Vasculitis (CV) is quite uncommon and usually associated with other clinical features of cryoglobulinaemia (arthralgia, glomerulonephritis). The serological findings of CV include mixed cryoglobulins (IgM and/or IgG), RF positivity and frequent low C4 [5,6]. CV and PAN are differentiated on the basis of vessel involvement where PAN produces arterial aneurysms and peripheral eosinophilia and CV is limited to only small vessels [6].

Leukocytoclastic vasculitis (LCV) is the most common form of vasculitis of the skin and usually results from deposition of immune complexes in the vessel wall [7,8]. It presents in different forms and in association with different diseases. A large number of conditions including infectious (bacterial, viral) and non-infectious diseases (inflammatory bowel disease, rheumatoid arthritis, lupus erythematosus, Sjögren syndrome, and less often malignancy) can produce LCV [8]. LCV due to HBV infection is very uncommon, only few case reports have been reported [4,9,10]. The disease can be confined to the skin (cutaneous) or it can affect many different organs of the body such as the kidneys, central nervous system, heart, gastrointestinal tract, and lungs. Systemic involvement is generally associated with a more severe disease course while cutaneous leukocytoclastic vasculitis is usually self-limited and has a better prognosis. When IgA is the dominant immunoglobulin in immune complexes, systemic involvement is more as in Henoch-Schönlein purpura (HSP). LCV due to IgG or IgM immune complexes carries better prognosis than HSP because of lesser systemic manifestations. Patients having mild disease usually have favourable course and hence do not require aggressive therapy [7]. It includes treatment of underlying cause and use of compression stockings to reduce purpura. In severe disease, recurrent cases or chronic cases, the treatment is more complex and includes the use of systemic corticosteroids and immunosuppressive agents [7].

Management of HBV related LCV includes antiviral agents to reduce the antigenic load and immunosuppressive agents e.g. steroids or cyclophosphamide, to control the immune complex formation and reactions leading to reduction of inflammation. However, treatment with steroid and immunosuppressive agents alone may worsen the hepatic disease because of enhanced viral replication; therefore concurrent use of immunosuppressants and antiviral agents is advised [4]. Previously reported cases of HBV related leukocytoclastic vasculitis also had associated HBV related liver disease and other extrahepatic manifestations like cryoglobulinaemia, either before or at the time of presentation [4,9,10]. But our case presented with leukocytoclastic Vasculitis as the initial manifestation of chronic HBV infection. No such case has been reported in the literature till date.

## CONCLUSION

Chronic antigenaemia in HBV infection can lead to immune complex formation and its deposition around small cutaneous vessels (uncommonly) may present as Leucocytoclastic Vasculitis. Entecavir therapy is effective against HBV-associated vasculitic syndrome. The report also suggests that viral hepatitis screening should be done routinely in all patients presenting with cutaneous vasculitis.

## REFERENCES

- [1] Shepard CW, Simard EP, Finelli L, Fiore AE, Bell BP. Hepatitis B Virus Infection: Epidemiology and Vaccination. *Epidemiol Rev.* 2006;28(1):112-25.
- [2] Baig S, Alamgir M. Extrahepatic manifestations of hepatitis B virus. *J Coll Physicians Surg Pak.* 2008;18(7):451-67.
- [3] Abbas AK. Diseases of immunity. In: Kumar V, Abbas AK, Fausto N, editors. *Pathologic basis of disease.* 7<sup>th</sup> ed. Philadelphia: W.B. Saunders; 2004. pp. 193-267.
- [4] Bankovsky HL, Liang TJ, Banner B. Chronic leukocytoclastic vasculitis complicating HBV infection. Possible role of mutant forms of HBV in pathogenesis and persistence of disease. *J Clin Gastroenterol.* 1995;21:42-47.
- [5] Enomoto M, Mikanishi T, Ishii M, Tamori A, Kawada N. Entecavir to treat hepatitis B-associated cryoglobulinaemic vasculitis. *Ann Intern Med.* 2008;149:912-13.
- [6] Kappus MR, Sterling RK. Extrahepatic manifestations of acute Hepatitis B virus infection. *Gastroenterology & Hepatology.* 2013;9(2):123-26.
- [7] Sunderkotter C, Bonsmann G, Sindrilaru A, Luger T. Management of leukocytoclastic vasculitis. *J Dermatolog Treat.* 2005;16(4):193-206.
- [8] Radotra BD. Pathology of cutaneous vasculitis. In: Sharma A, editor. *Textbook of systemic Vasculitis.* 1<sup>st</sup> ed. New Delhi: Jaypee; 2015. pp. 48-53.
- [9] Filer A, Hughes A, Kane K, Mutimer M, Jobanputra P. Successful treatment of hepatitis B-associated vasculitis using lamivudine as the sole therapeutic agent. *Rheumatology.* 2001;40(9):1064-65.
- [10] Gluck T, Weber P, Wiedmann KH. Hepatitis B associated vasculitis. Clinical course with glucocorticoid and alpha-interferon therapy. *Dtsch Med Wochenschr.* 1994;119(41):1388-92.

### PARTICULARS OF CONTRIBUTORS:

1. Senior Professor, Department of Medicine, PGIMS Rohtak, Haryana, India.
2. Senior Resident, Department of Medicine, PGIMS Rohtak, Haryana, India.
3. Senior Resident, Department of Medicine, PGIMS Rohtak, Haryana, India.
4. Senior Resident, Department of Medicine, PGIMS Rohtak, Haryana, India.
5. Senior Resident, Department of Medicine, PGIMS Rohtak, Haryana, India.

### NAME, ADDRESS, E-MAIL ID OF THE CORRESPONDING AUTHOR:

Dr. Vikram Singh Tanwar,  
Room no. 153, Doctor's Hostel, PGIMS Rohtak, Haryana-124001, India.  
E-mail: drvikrampgi@gmail.com

FINANCIAL OR OTHER COMPETING INTERESTS: None.

Date of Submission: **Oct 19, 2015**  
Date of Peer Review: **Nov 06, 2015**  
Date of Acceptance: **Dec 15, 2015**  
Date of Publishing: **Feb 01, 2016**