

Images in Medicine – An Atypical Presentation of Unilateral Tongue Angioedema Caused by Acetaminophen

ANGELINE DEEPTHI¹, SHAHEEN², HARI KUMAR³, SAJNA ASHRAF⁴, JOHN HEARTY DEEPAK⁵**Keywords:** Cyclooxygenase, Dexamethasone, Paracetamol, Tryptase

A woman in her 30s presented to our dental clinic, with one day history of an increasingly swollen tongue on the left side. Two days before presentation, the patient had taken acetaminophen (Paracetamol). The patient was recently diagnosed with tension headache and was prescribed tablet acetaminophen (Dolo-650) twice daily for two days by her general physician. She did not have any swelling in other part of her body and face. She had no associated airway obstruction but did have difficulty in talking due to the degree of tongue swelling. Her past medical and surgical histories were not significant. She had no family history of angioedema. She had no known history of drug intolerance and allergic responses. Her vital signs and remainder of physical examination were unremarkable; in particular there was no wheeze and rashes.

On examination she was afebrile with no respiratory distress. She had a diffuse, soft non tender swelling in the left posterior lateral border of tongue [Table/Fig-1a&b]. There was no cervical lymphadenopathy. There was no evidence of quinsy or tonsillitis, and no foreign body was seen.

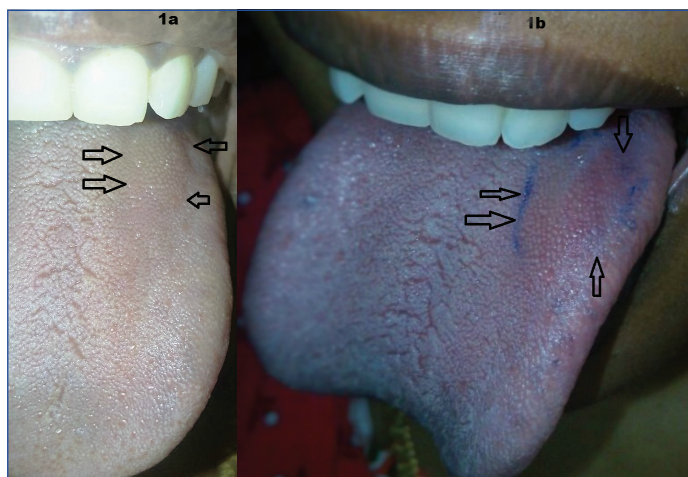
Laboratory investigations, including a complete haemogram, routine urine test, and renal and liver function tests were negative. Erythrocyte sedimentation rate and C reactive protein level were within normal limits. Thyrotropin and complement component levels (C1q, C3, and C4) were normal. Initial tryptase and 24 hour tryptase levels were within normal limits. As per Naranjo's Algorithm, a causality score of 5 was obtained.

From Naranjo's scale with causality assessment (WHO-UMC scale) the angioedema categorized as probable reaction to acetaminophen. Acetaminophen (Paracetamol) was discontinued, intravenous dexamethasone 8 mg and intravenous diphenhydramine 25 mg were given twice daily for two days. Patient symptoms and signs improved markedly overnight. The dexamethasone dosage was tapered and stopped over the next 2 days. Her tongue oedema resolved completely over the next 2 days [Table/Fig-2]. A prompt response to dexamethasone and diphenhydramine confirmed the diagnosis of angioedema. The patient was advised to have regular recall visits, for every two months.

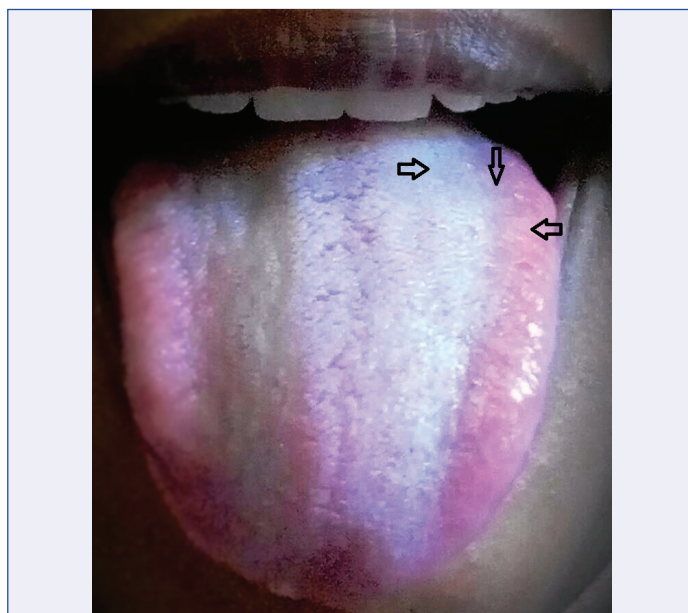
DISCUSSION

Angioedema is a localized self-limiting swelling in the dermis, lip mucosa and tongue. It occurs due to release of plasma and vasoactive mediators. Angioedema is generally subdivided into idiopathic angioedema, extrinsic factor induced angioedema and angioedema with C1-INH deficiency. The extrinsic factor induced angioedema includes angioedema associated with Non Steroidal Anti Inflammatory Drug (NSAID) such as aspirin, paracetamol [1].

Generally NSAID-induced angioedema considered as a non-allergic reaction. The pathogenesis of NSAID induced angioedema is by inhibition of Cyclooxygenase (Cox) which results in significant changes in arachidonic acid metabolism such as cysteinyl



[Table/Fig-1]: a) Angioedema of left tongue. Black arrows shows diffuse swelling in the left posterior lateral border of tongue; b) Blue line clearly delineate areas of angioedema. Black arrows show angioedema of left posterior lateral border of tongue.



[Table/Fig-2]: Disappearance of left tongue angioedema after treatment.

leukotriene excessive production. Recent research suggests that bradykinin play a vital role in the pathogenesis of most forms of non-allergic angioedema [1,2].

Patient with oropharyngeal angioedema may present with acute upper airway obstruction and this should be monitored for airway. Since, oedema from the site typically progresses rapidly and may end up in life-threatening complications [2].

Paracetamol (Acetaminophen) is a commonly used antipyretic agent and it act by preferentially inhibiting Cox-3 receptors. Angioedema to paracetamol is rare and likely to occur in children [3,4].

The important step in treatment of angioedema is to terminate the drug that suspected to trigger angioedema. Antihistamines and glucocorticoids often act as mainstay drugs in treatment of drug induced angioedema [1,2].

Ayonrinde OT, Saker BM stated higher prevalence of allergic reactions to acetaminophen in females than males [5].

Oral drug challenge is preferred test for acetaminophen allergy and this is due to non specificity of serum IgE test and intradermal skin test. Oral drug challenge for acetaminophen should be performed by a trained allergy officer and this test helps in widening therapeutic options in patients allergic to acetaminophen [6].

An exhaustive medical literature search revealed only one previously reported case of tongue angioedema secondary to paracetamol (Acetaminophen) in a four year old patient [4].

This is the first article in the medical literature reporting unilateral angioedema due to paracetamol in an adult. All healthcare professionals should be aware of such a possibility. Furthermore,

such an event should be recognized early and treated accordingly. This case report should alert physicians prescribing acetaminophen which consider one of the safest drugs available till date.

REFERENCES

- [1] Inomata N. Recent advances in drug-induced angioedema. *Allergy International*. 2012;61(4):545-57.
- [2] Ee YS, Sow AJ, Goh BS. Unilateral tongue angioedema caused by angiotensin converting enzyme inhibitor. *The Journal of Laryngology and Otology*. 2010;124(12):1337-39.
- [3] Boussetta K, Ponvert C, Karila C, Bourgeois ML, Blic J, Scheinmann P. Hypersensitivity reactions to paracetamol in children: A study of 25 cases. *Allergy*. 2005;60(9):1174-77.
- [4] Panchabhai TS, Gogtay NJ, Bavdekar SB. Paracetamol induced angioedema. *Indian journal of medical sciences*. 2008;62(10):420.
- [5] Ayonrinde OT, Saker BM. Anaphylactoid reactions to paracetamol. *Postgraduate medical journal*. 2000;76(898):501-02.
- [6] Dass K, Bose S, Ditto AM. An unusual case of immediate hypersensitivity reaction to a common medication. *Annals of Allergy, Asthma and Immunology*. 2016;117(1):14-16.

PARTICULARS OF CONTRIBUTORS:

1. Reader, Department of Oral Medicine and Radiology, Rajas Dental College (Under The M.G.R Medical University), Tirunelveli, Tamilnadu, India.
2. Assistant Professor, Department of Orthodontics, King Khalid University College of Dentistry Abha, Saudi Arabia, Abha, United Arab Emirates.
3. Senior Lecturer, Department of Oral Medicine and Radiology, Saveetha Dental College & Hospital, Saveetha University, Chennai, Tamil Nadu, India.
4. Assistant Professor, Department of Oral Medicine and Radiology, Sri Sankara Dental College, Varkala, Kerala, India.
5. Senior Lecturer, Department of Oral Medicine and Radiology, Rajas Dental College (Under The M.G.R Medical University), Tirunelveli, Tamilnadu, India.

NAME, ADDRESS, E-MAIL ID OF THE CORRESPONDING AUTHOR:

Dr. Hari Kumar,
Senior Lecturer, Department of Oral Medicine and Radiology, Saveetha Dental College & Hospital, Saveetha University,
Chennai-600077, Tamil Nadu, India.
E-mail: drhari.omrd@gmail.com

Date of Submission: **Nov 03, 2016**

Date of Peer Review: **Nov 18, 2016**

Date of Acceptance: **Dec 28, 2016**

Date of Publishing: **Apr 01, 2017**

FINANCIAL OR OTHER COMPETING INTERESTS: None.