

Management of Severely Dilacerated Mandibular Third Molar

AMBAR W. RAUT¹, VIJAY MANTRI², SHUBHAM KALA³, HARSHANK LAKHERA⁴

Keywords: Dilaceration, Procedural errors, Root canal curvature, Schneider's method

A 38-year-old woman reported to the Department of Conservative Dentistry and Endodontics with a complaint of pain in lower left back region of jaw since two weeks. Pain was continuous, severe and aggravated in night or on lying down. Clinical examination revealed a temporary restoration in relation to mandibular left third molar (38). The tooth was tender on percussion. The patient was referred from a local dentist in view of severely curved mesial and distal roots noticed by the dentist on working length Intraoral Periapical (IOPA) radiograph [Table/Fig-1]. From the clinical and radiographic findings, a diagnosis of previously initiated root canal treatment with chronic irreversible pulpitis and symptomatic apical periodontitis was made in relation to 38.

Prior to the initiation of root canal treatment, the degree of root canal curvature was determined by using the available IOPA radiograph with Schneider's method. It was 85° for mesial root and 80° for the distal root, indicating the 'severe' canal curvature in both roots [Table/Fig-2].

With informed consent, local anaesthesia was administered, temporary restoration was removed and access cavity was modified under rubber dam isolation. Three canals were located – mesiobuccal, mesiolingual and distal. The canals were instrumented using number 6 and 8 stainless steel K-files (Dentsply/ Maillefer, Ballagigues, Switzerland). The instruments were pre-curved, coated with EDTA gel (Glyde, Dentsply/ Maillefer, Ballagigues, Switzerland) and slowly advanced in watch-winding motion. The patency was verified. Working length was established radiographically and using electronic apex locator. Number 15 and 20 K-files were used to prepare glide path upto the working length. The estimated length till the curvature was marked on the engine-driven instrument and coronal flaring was done using ProTaper 'SX' file (Dentsply/ Maillefer, Ballagigues, Switzerland). The nickel titanium (NiTi) hand files No. 15, 20, and 25 (Dentsply/ Maillefer, Ballagigues, Switzerland) were

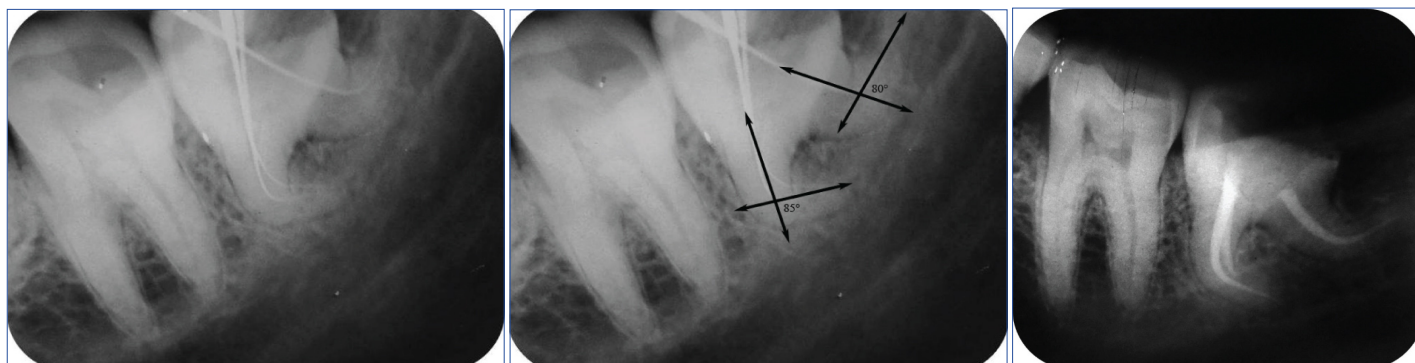
used for sequential filing of the curved canals to the working length. All the files were precurved before insertion in the canal. Canals were frequently irrigated to remove debris and recapitulation was done to prevent canal blockage by dentinal debris. Final cleaning and shaping was carried out using Mtwo rotary files (VDW, Munich, Germany) sequentially upto size 25/.06 taper. Calcium hydroxide (RC Cal, Prime Dental, Mumbai, India) was used as an intracanal medicament and closed dressing was given for a week.

In second visit, the canals were irrigated and dried. Obturation was done by cold lateral compaction technique using AH Plus sealer (Dentsply/ Maillefer, Ballagigues, Switzerland). The post-obturation restoration was done with composite resin [Table/Fig-3]. Postoperative instructions were given to the patient and recalled for subsequent follow up. The patient was completely asymptomatic at three months follow up visit and radiographic examination revealed absence of periapical lesion.

DISCUSSION

Dilaceration is the 90° or greater angulation of the tooth or root along the long axis of tooth or root towards mesial or distal direction. It may also be defined as apical deviation of the root by 20° or greater. Dilaceration is considered to result due to trauma to the developing tooth [1]. Third molars commonly present with aberrations in number or shape of root and root canals. Prevalence of anatomical variations is higher in mandibular third molars (3.3-30.92%) compared to maxillary third molars (1.33-8.46%) [2]. In third molars, root dilacerations may occur anywhere along the root length and can include one or all roots. They are generally directed distally [2].

Curved root canals pose a challenge to the clinician in terms of cleaning and shaping as well as obturation of root canal system [3]. Determination of degree of canal curvature before initiation of



[Table/Fig-1]: Preoperative Intraoral Periapical (IOPA) radiograph; **[Table/Fig-2]:** Measurement of root canal curvature using Schneider's method – angle formed by a line drawn parallel to the long axis of canal in the coronal third and a second line drawn from apical foramen to intersect the first line. The angle of curvature was 85° for mesial root and 80° for distal root, suggestive of severely dilacerated roots; **[Table/Fig-3]:** Postoperative Intraoral Periapical (IOPA) radiograph, showing smooth flowing tapered preparation and adequate obturation of root canals, along with preservation of original canal curvature. (Images left to right)

root canal treatment is essential to assess the level of difficulty. Knowledge of root canal curvature helps to plan the root canal preparation precisely as well as overcome the anatomic complexity and limitations of root canal instruments. It permits preservation of the curvature during root canal preparation and prevents deformation of root canal instruments [4]. Therefore, diagnosis of root dilaceration before initiation of endodontic treatment is crucial to ensure adequate canal preparation.

Root canal curvature may be determined by various methods with the help of periapical radiographs. Schneider described a technique to calculate canal curvature using an angle formed by two straight lines – a line drawn parallel to the long axis of canal in the coronal third and a second line drawn from apical foramen to intersect the first line. The angle of curvature may be classified as straight (5° or less), moderate (10-20°) and severe (25-70°) [4]. Thus, the canal curvature in our case was of 'severe' type.

The various factors which affect the preparation of curved root canals include technique of instrumentation, diameter and flexibility of endodontic instruments, location of apical foramen and dentin microhardness. Conventionally, 0.02 taper stainless steel instruments are used for preparation of root canal. However, instruments above #15/ 20 size tend to straighten in the canal owing to their inflexibility. Use of such instruments for preparation of curved canals may lead to iatrogenic alteration in the original shape of canal, especially in the apical third. Commonly encountered procedural errors are formation of ledges, elbows or zips; canal blockage, perforation, transportation of the apical foramen and instrument fracture [5].

Even contact of the file with root canal wall is necessary to prevent such errors.

The measures to avoid procedural errors in such cases include pre-curving of file, extravagant use of smaller files, use of intermediate size files, use of flexible files, anti-curvature filing, coronal flaring and balanced force technique. The high flexibility and fatigue resistance of Mtwo rotary instruments permits their efficient and safe use in severely curved root canals [6]. Hence, Mtwo rotary instruments were used for canal preparation in this case.

Thus, successful management of severely curved root canal requires careful preoperative assessment, sequential use of appropriate hand/rotary instruments, adequate glide path preparation and frequent irrigation. The degree of canal curvature acts as a guideline for treatment planning in these cases.

REFERENCES

- [1] Jafarzadeh H, Abbott PV. Dilaceration: review of an endodontic challenge. *J Endod.* 2007;33:1025-30.
- [2] Ahmed HM. Management of third molar teeth from an endodontic perspective. *Eur J Gen Dent.* 2012;1:148-60.
- [3] Sakkir N, Thaha KA, Nair MG, Joseph S, Christalin R. Management of dilacerated and S- shaped root canals-An endodontic challenge. *J Clin Diagn Res.* 2014;8:ZD22-24.
- [4] Estrela C, Bueno MR, Sousa-Neto MD, Pecora JD. Method for determination of root curvature radius using cone-beam computed tomography images. *Braz Dent J.* 2008;19(2):114-18.
- [5] Balani P, Niazi F, Rashid H. A brief review of the methods used to determine the curvature of root canals. *J Res Dent.* 2015;3:57-63.
- [6] Malagino VA, Grande NM, Plotino G, Somma F. The Mtwo NiTi rotary system for root canal preparation. *Roots.* 2006;3:59-62.

PARTICULARS OF CONTRIBUTORS:

1. Assistant Professor, Department of Conservative Dentistry and Endodontics, Swargiya Dadasaheb Kalmegh Smruti Dental College and Hospital, Nagpur, Maharashtra, India.
2. Professor, Department of Conservative Dentistry and Endodontics, Modern Dental College and Research Centre, Indore, Madhya Pradesh, India.
3. Assistant Professor, Department of Conservative Dentistry and Endodontics, College of Dental Science and Hospital, Rau, Indore, Madhya Pradesh, India.
4. Private Practitioner, Muskaan Dental Clinic, Indore, Madhya Pradesh, India.

NAME, ADDRESS, E-MAIL ID OF THE CORRESPONDING AUTHOR:

Dr. Ambar W. Raut,
19, Jalvihar layout, Nagpur-440036, Maharashtra, India.
E-mail: drambarraut@gmail.com

Date of Submission: **May 26, 2017**
Date of Peer Review: **Jun 06, 2017**
Date of Acceptance: **Jul 13, 2017**
Date of Publishing: **Aug 01, 2017**

FINANCIAL OR OTHER COMPETING INTERESTS: None.