

Spontaneous Renal Artery Thrombosis Successfully Intervened with Drug Eluting Stent: A Primary Renal Artery Angioplasty

BASANT KUMAR¹, SAVITA KUMARI²

ABSTRACT

Renal artery thrombosis is a rare medical emergency and needs to be diagnosed early and treated urgently to prevent irreversible renal injury. We report a case of 35-year-old male, who presented with the total thrombotic occlusion of right renal artery and was managed with percutaneous transluminal angioplasty with a drug eluting stent.

Keywords: Abdominal pain, Lumbar pain, Right renal artery

CASE REPORT

A 35-year-old male presented with a complaint of sudden onset unabating, lower abdominal pain and a right flank pain since last three days. There were no history of past trauma, vomiting, diarrhoea, chestpain, shortness of breath, syncope, dysuria, haematuria or melaena. There was no past history of major comorbidities like diabetes, hypertension or cardiac illness and illicit drug abuse. He occasionally took 20 to 30 ml of alcohol and smoked two to four cigarettes per day.

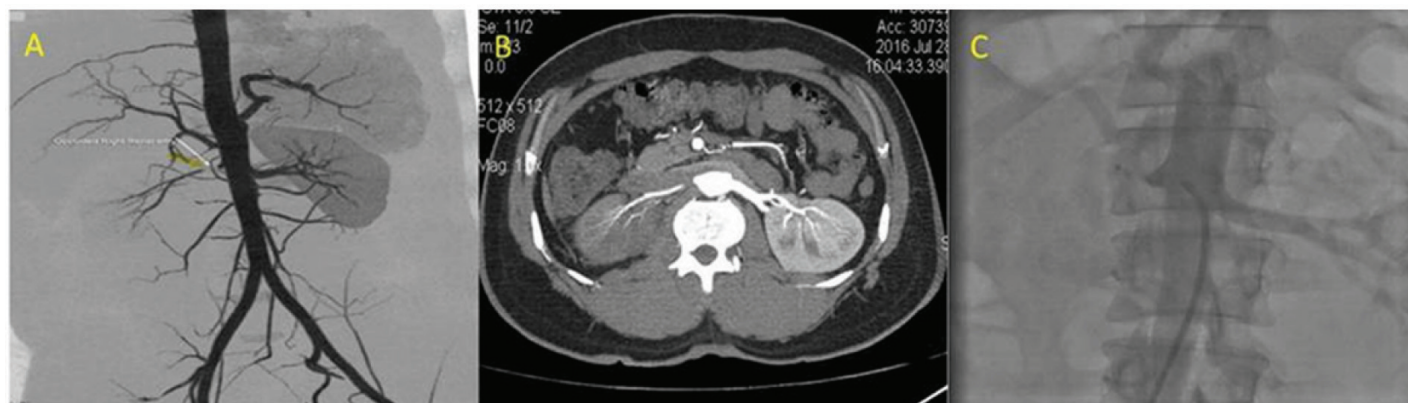
Physical examination revealed that patient had mild fever (38.5°C), blood pressure of 110/80 mmHg, heart rate of 90 beats per minute, respiratory rate of 18 breaths per minute and saturation of 98% on room air. He was conscious, but in the mild distress due to pain. His abdominal examination revealed tenderness on palpitation with no other marked abdominal signs of rebound, guarding, distension or organomegaly. Examination of other systems was un-remarkable and the patient was not on any medication.

The initial emergency department evaluation included an electrocardiogram and echocardiography, both of which were normal. Laboratory assessment revealed microscopic haematuria, no leukocytosis and serum creatinine of 2.0 mg/dL (normal range, 0.5–1.4 mg/dL). The coagulation profile was within normal limits. Serum lactate dehydrogenase was elevated to 1,479 U/L (normal range, 100 U/L).

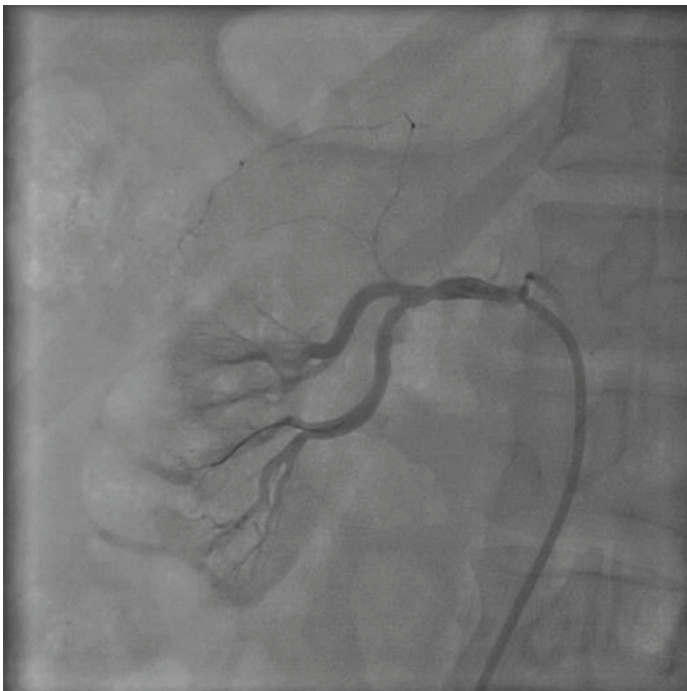Contrast-enhanced helical Computed Tomography (CT) images [Table/Fig-1a,b] were obtained, which showed total occlusion

of right renal artery. The patient was hydrated with normal saline before CT was performed. The left renal artery and parenchyma were normal. As he was having severe lumbar pain and other causes of pain were excluded by relevant investigations and CECT showed total occlusion of right renal artery, it was decided to open the artery through percutaneous intervention. Through right femoral artery, renal artery angiogram was done. It showed total thrombotic occlusion of right renal artery and left renal artery was normal [Table/Fig-1c] [Video-1].

Right renal artery was cannulated with 7F RCA guide catheter and a hydrophilic 0.014" guide wire (Whisper extra-support 0.014", Abbot Vascular) was passed through the lesion. A 6F thrombuster (Thrombuster II, Kaneka Medix Corporation) was passed, thrombosuction was performed and the lesion was sequentially pre-dilated with 2.0x10 mm and 3.0x10 mm semi-compliant balloon [Video-2]. Good flow was restored, but again renal flow diminished due to residual stenosis. So, it was decided to stent the artery and subsequently 4.0x24 mm drug eluting stent was deployed at high pressure and good end result was obtained [Table/Fig-2] [Video-3]. Patient was loaded with aspirin 325 mg, clopidogrel 300mg, and 5000 units unfractionated heparin was given before the procedure and Activated Clotting Time (ACT) was maintained around 300msec. After few hours, his lower abdominal pain completely relieved. The serum creatinine levels lowered from 2.0 mg/dL to 1.2 mg/dL. He was discharged on third day with dual antiplatelet and statin regimen (Atorvastatin). Also, hypercoagulable state work up was done, which was found to be negative.



[Table/Fig-1]: a) 3D reconstructed image of abdominal aorta and branches, white arrow showing total occlusion of right renal artery; b) Contrast-enhanced CT showing complete occlusion of right renal artery; c) Contrast aortogram showing occluded right renal artery and patent left renal artery.



[Table/Fig-2]: Post-procedural renal angiogram after percutaneous transluminal angioplasty with drug-eluting stent.

DISCUSSION

Renal artery thrombosis is extremely rare and often misdiagnosed condition, due to presentation as acute abdomen to surgeon rather than physician. Although, the exact prevalence is not known yet, most of the studies give the prevalence of 0.02/1000 [1,2]. The diagnosis is often critical due to variability in clinical presentation and symptoms. A high level of suspicion is needed for the practicing clinician in differential diagnosis of renal artery thrombosis.

This rare condition of renal artery thrombosis usually occurs in people of age 30 and 70 years, but may also occur in other groups [3]. Although the typical patient in most series tends to be older, the patient in our case report was young, just 35-year-old. As evidenced lumbar and flank tenderness are more likely in idiopathic and younger patients of renal infarction, the patient in our case also presented with sudden, sharp, unabating pain in lower abdomen. However, there were no other concurrent symptoms like fever, nausea and vomiting. Laboratory assessment revealed increased lactate dehydrogenase levels. Although, it is a commonly encountered sign of renal infarction, it cannot be relied upon due to report of case, where lactate dehydrogenase was normal, despite of sizeable renal infarct [3].

The salient feature of the case report is that, there is no comorbid disease condition triggering the formation of renal artery thrombus.

The patient did not have hypertension, diabetes, cardiac illness, and haematologic disorder. Our patient was not a high-risk or vulnerable subject for the development of renal artery thrombosis. An early and quick differential diagnosis is crucial in such cases like appendicitis, diverticulitis, and incarcerated hernia. Other surgical causes include mesenteric ischemia, nephrolithiasis and pyelonephritis, these should also be considered [2,4].

The symptoms of acute renal infarction and renal artery thrombosis are non-specific, so a high suspicion is advised in high risk-patients [5]. Thus, due to unclear presentation, it is often missed and delayed upto two days or more [6,7]. This may prove to be fatal owing to its common sequel of loss of renal function and persistent hypertension [8].

Moreover, currently, percutaneous endovascular intervention of severe renal artery stenosis achieves a 95-98% success rate, less than 5% major complication & 10% late stent restenosis [9]. There is no much literature on acute total thrombotic occlusion of renal artery and treatment with drug-eluting stent to prevent late stent restenosis. This is the first case report involving successful treatment of acute total thrombotic renal artery occlusion treated with drug eluting stent.

CONCLUSION

Renal artery thrombosis is a rare entity and its diagnosis require high index of clinical suspicion. Percutaneous transluminal renal angioplasty with drug eluting stent is a viable option in emergency situation to prevent renal loss and further stent restenosis.

REFERENCES

- [1] Korzets Ze, Plotkin E, Bernheim J, Zissin R. The clinical spectrum of acute renal infarction. *Isr Med Assoc J.* 2002;4(10):781-84.
- [2] Lopez VM, Glauser J. A case of renal artery thrombosis with renal infarction. *J Emerg Trauma Shock.* 2010;3(3):302.
- [3] Singh S, Wang L, Yao QS, Jyotimalika J, Singh S. Spontaneous renal artery thrombosis: An unusual cause of acute abdomen. *North American Journal of Medical Sciences.* 2014;6(5):234.
- [4] Saeed K. Renal infarction. *International Journal of Nephrology and Renovascular Disease.* 2012;5(9):119-23.
- [5] Ababneh B, Ali M. Acute abdominal pain due to spontaneous renal artery thrombosis. *J Am Coll Cardiol.* 2015;65(10_S).
- [6] Hazanov N, Somin M, Attali M, Beilinson N, Thaler M, Mouallem M, et al. Acute renal embolism: forty-four cases of renal infarction in patients with atrial fibrillation. *Medicine.* 2004;83(5):292-99.
- [7] Tsai SH, Chu SJ, Chen SJ, Fan YM, Chang WC, Wu CP, et al. Acute renal infarction: a 10 years experience. *International Journal Of Clinical Practice.* 2007;61(1):62-67.
- [8] Paris B, Bobrie G, Rossignol P, Le Coz S, Chedid A, Plouin PF. Blood pressure and renal outcomes in patients with kidney infarction and hypertension. *J Hypertens.* 2006;24(8):1649-54.
- [9] Safian RD, Textor SC. Renal-artery stenosis. *N Engl J Med.* 2001;344(6):431-42.

PARTICULARS OF CONTRIBUTORS:

1. Consultant Cardiologist, Department of Cardiology, Central Medical Centre Hospital, Hisar, Haryana, India.
2. Consultant Cardiologist, Department of Cardiology, Central Medical Centre Hospital, Hisar, Haryana, India.

NAME, ADDRESS, E-MAIL ID OF THE CORRESPONDING AUTHOR:

Dr. Basant Kumar,
Consultant Cardiologist, Department of Cardiology, Central Medical Centre Hospital, Hisar-125001, Haryana, India.
E-mail: basantvimal@gmail.com

FINANCIAL OR OTHER COMPETING INTERESTS: None.

Date of Submission: **Mar 29, 2017**
Date of Peer Review: **Apr 27, 2017**
Date of Acceptance: **Jul 27, 2017**
Date of Publishing: **Sep 01, 2017**