

Subcutaneous Cyst due to *Medicopsis romeroi* in a Diabetic Lepromatous Leprosy Patient: An Interesting Case Report and Review from India

BHAWNA SHARMA¹, PRADEEP KUMAR SINGH², KHUSHBU PANDEY³, GAJANAND MITTAL⁴, V. RAMESH⁵, MONORAMA DEB⁶

ABSTRACT

Medicopsis romeroi (*M. romeroi*) (syn. *Pyrenochaeta romeroi*) is a rare melanized fungus causing subcutaneous/localized invasive phaeohyphomycosis in immunocompromised patients. We present a rare case of subcutaneous phaeohyphomycotic cyst caused by *M.romeroi* in a diabetic male with lepromatous leprosy. Molecular identification was performed by sequencing of Internal Transcribed Spacer (ITS) region and D1/D2 region of Large Ribosomal Subunit (LSU).

Keywords: Dapsone, Diabetes, Mycosis

CASE REPORT

A 48-year-old diabetic male patient, resident of Bihar (India), daily wage construction labour by occupation was diagnosed with lepromatous leprosy in March 2016. He was on anti-leprosy treatment regimen of dapsone, rifampicin and glypazide. He was admitted in October 2016 to a tertiary care hospital in Delhi, with chief complaints of pain in knee joint, red scaly raised lesions all over the body since last one month. On admission, he was clinically diagnosed with Erythema Nodosum Leprosum (ENL). The patient also complained of a painless progressively growing nodule on the lateral aspect of the left foot since last three months. There was history of frequent contact with debris of construction material.

On examination, red macular lesions were observed all over the body. The leprosy status was reconfirmed by Slit Skin Smear (SSS) examination. Patient consent was taken for further diagnosis of the fluctuating cyst. The fluctuating cystic swelling was about 2x2 inches in diameter with ill defined margins [Table/Fig-1]. Routine investigations revealed Haemoglobin - 6.6 mg/dl, leukocyte count 12,200 cells/cumm, differential count; neutrophils 68%, lymphocytes 25%, monocytes 4%, eosinophils 3%, basophil 0%, platelets 2.1 L/cumm and Erythrocyte Sedimentation Rate (ESR) 48 mm/hour, fasting blood sugar 320 mg/dl, blood urea 21 mg/dL, serum creatinin 0.40 U/L, Serum Glutamic Pyruvic Transaminase (SGPT) 10 U/L, ALP 71 U/L and serum electrolyte (Na⁺ 139 mmol/L and K⁺ 4.4 mmol/L). The tests were negative for HIV and Hepatitis B.

On the day of admission (day1) the cyst aspirate was sent for microbiological examination to the Microbiology laboratory for Gram's stain, culture and sensitivity. Microscopic examination of Gram stain smear showed inflammatory cells and a few septate fungal hyphae in a background of necrotic material [Table/Fig-2]. The pus sample was also stained by Ziehl Neelsen stain and acid fast bacilli with characteristic cigar bundle arrangement were observed. A 20% KOH preparation of the sample revealed fungal elements [Table/Fig-3]. The sample was inoculated on 5% Sheep Blood Agar (SBA), Macconkey agar and incubated at 37°C. 2 set of tubes of Sabouraud's Dextrose Agar (SDA) were inoculated and 2 were incubated at 25°C and 2 were incubated at 37°C. A repeat sample was obtained on day 2 for confirmation of the above findings. Finally on day 4, incision and drainage of the cyst was carried out. All the above tests were repeated. Bacterial culture was sterile. A white, velvety growth was observed on SDA (at 25°C and 37°C) after eight

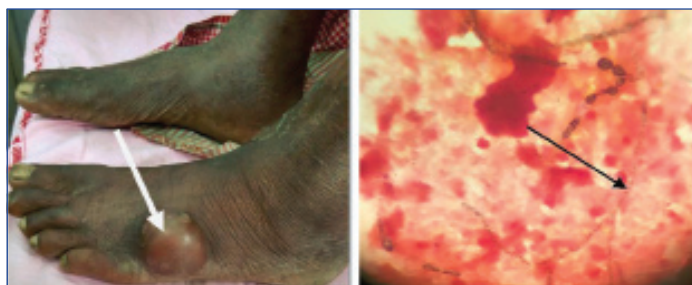
days of incubation of the first sample. The colour gradually turned brown after two weeks [Table/Fig-4]. Lactophenol Cotton Blue (LPCB) mount revealed brown/black colour, tortuous hyphae. No conidia were observed on hyphae on Potato Dextrose Agar (PDA) [Table/Fig-5]. Identical microscopic findings and growth on culture were observed from all the samples. Therefore, the culture was subjected to molecular identification.

Treatment should be started after molecular identification. Surgical incision and drainage of the lesion was carried out and antifungal therapy with itaconazole was started. The patient Left Against Medical Advice (LAMA) from the hospital on the 15th day of hospital admission day and the follow up of the patient was not continued.

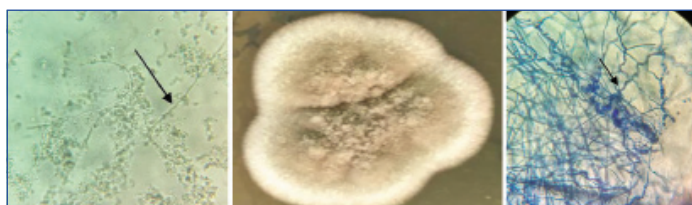Molecular Identification

Molecular identification was performed by sequencing of Internal Transcribed Spacer (ITS) region and D1/D2 region of Large Ribosomal Subunit (LSU). DNA was extracted from seven days old culture using tris-saturated phenol, chloroform and isoamyl alcohol (25:24:1) and ethanol precipitation. The DNA pellet was dried and suspended in 75 µl of sterile nuclease-free water and treated with 06 µl (10 mg/ml) of RNAase (Sigma-Aldrich, Co., St. Louis, USA) for 1 hour at 37°C. The purified DNA of the pathogenic organism was subjected to PCR amplification of ITS region using pan fungal primers ITS1 (5'-TCC GTA GGT GAA CCT GCG G-3') and ITS4 (5'-TCC TCC GCT TAT TGA TAT GC-3') and for D1/D2 region using primers NL1 (5'-GCA TAT CAA TAA GCG GAG GAA AAG-3'), NL4 (5'-GGT CCG TGT TTC AAG ACG G-3') [1,2].

The amplified fragments were purified (Wizard SV Gel and PCR Clean-up System, Promega) and sequenced using the cycle sequencing kit (BigDye Terminator v3.1 cycle sequencing kit RR100; Applied Biosystems, Foster City, CA, USA) and the final product was sequenced on an ABI 3130xL Genetic analyser (Applied Biosystems). DNA sequences were analysed with Sequencing Analysis 5.3.1 software (Applied Biosystems, Foster City, CA, USA) and the aligned sequences were subjected to GenBank Basic Local Alignment Search Tool (BLAST) searches (<http://www.ncbi.nlm.nih.gov/BLAST/Blast.cgi>) for species identification. BLAST searches confirmed the isolate as *M. romeroi* with 100% identity of both ITS and D1/D2 sequences to *M. romeroi* strains. ITS sequences of our isolate GenBank accession no. KU361135 matched with 100% identity with three strains (CNRMA9.134, Kw596 and IP 888.65)



[Table/Fig-1]: Showing fluctuating cystic swelling over left foot. **[Table/Fig-2]:** Gram's stain showing black coloured fungal hyphae (100X).



[Table/Fig-3]: A 20% KOH showing growth of filamentous fungal element (40X). **[Table/Fig-4]:** Phaeoid fungus after eight days of incubation on SDA media. **[Table/Fig-5]:** Showing tortuous fungal hyphae under LPCB stain (40X).

Author, year, Place	Area involved	Underlying condition	Treatment given	Outcome
Kulkarni M et al., India [9]	Left thigh, left calf, and right shin	Kidney transplant recipient	Surgical excision, voriconazole	Survived
Badali H et al., India [11]	Right forearm	Verrucous plaque	Incision and drainage alone	Survived
Thammayya A et al., India [24]	Foot	NA	NA	NA
Yadav S et al., India [28]	Left foot	Diabetes	Incision and drainage, itraconazole	Survived
Babu K, India [31]	Left eye	Immuno-competent	Intra-vitreal voriconazole and amikacaci	Survived

[Table/Fig-6]: Review of *Medicopsis romeroi* infection in patients from India. NA= Not available.

of *M. romeroi* (GenBank accession no. KP132405.1, DQ836803.1 and FN826905.2). However, the D1/D2 sequence of our isolate with Gene Bank accession no. KU361119 matched with 99%-100% identity with four strains (CBS 128765, CBS 123975, CBS 132878 and L2572) of *M. romeroi* (Gene Bank accession no. KF015621.1, KF015623.1, KF015622.1 and KC288120.1).

DISCUSSION

Opportunistic subcutaneous fungal infections are increasing in present time. Some of the highly recalcitrant, disseminated infections appeared to be associated with immunosuppression, namely Diabetes Mellitus (DM), AIDS, organ transplantation recipients, anticancer therapy etc., [3]. Phaeohyphomycosis is a heterogeneous group of superficial or deep fungus with black filaments that often causes opportunistic infections [4–6]. The members of the genus *Medicopsis romeroi* (syn. *Pyrenochaeta romeroi*) are widely distributed in soil and plant debris [7]. The fungus is generally inoculated through direct trauma and remains localized to cutaneous and sub-cutaneous tissue. *M.romeroi* is often isolated from mycetoma. Recently, it has also been found as a causative agent of phaeohyphomycotic cyst [8-15].

Leprosy is an immunocompromised condition leading to many superimposed opportunistic infections of bacterial and fungal origin [16-19]. Phaeohyphomycosis enrolls a heterogenous group of cutaneous, subcutaneous and systemic fungal infections caused by fungi with melanised hyphae or yeast cells [4,6,7,15]. *Medicopsis* is

a genus of Coelomycetes having conidial fruit bodies covered with setae. Recently, the genus has been reclassified into other genera. The species are characterized by the presence of rapidly growing flat, velvety or floccose colonies producing dark olive-gray, aerial hyphae with olivaceous black reverse. *Pyrenochaeta romeroi* and *Pyrenochaeta mackinnonii* were accommodated in the new genera *Medicopsis* and *Nigrograna*, respectively, based on the analysis of ITS, D1/D2, β -tubulin, and chitin synthase 1 gene sequences. They are saprophytic fungus found in soil and plants that can be introduced into deeper tissues by trauma [15].

The number of identified pathogenic agents has steadily increased with the growing number of immunocompromised hosts [6,20-23]. There are many reports of fungal infection in immunocompromised patients [24-33]. [Table/Fig-6] shows review of *M. romeroi* infections in patients from India.

Clinical lesions of deep phaeohyphomycosis are nonspecific, sometimes deceptive and usually present as subcutaneous indolent nodule. The literature shows that in absence of standard therapy, surgery is usually successful. Complete removal of the encapsulated structure can be curative in case of sub cutaneous cyst. Although occasionally medical therapy alone is successful, combined medical-surgical therapeutic approaches are preferable, and medical treatment is reserved for patients with multiple abscesses and where surgery is contraindicated.

M. romeroi has been shown to be resistant to broad spectrum anti fungal such as amphotericin B, fluconazole, itraconazole and caspofungin [11,13]. The treatment should be tailored according to the location and size of the lesion.

CONCLUSION

It was concluded that combined surgical and antifungal treatment can prevent early deep-tissue involvement. The present case was treated with itraconazole and surgical debridement. Increased awareness among clinician and microbiologist/mycologist of *Medicopsis romeroi* infection will go a long way in rendering timely patient care.

ACKNOWLEDGEMENTS

The authors gratefully acknowledge the help extended by Dr. Anuradha Chaudhary, Professor, Department of Medical Mycology, Vallabhnbhai Patel Chest Institute, University of Delhi, India, for the molecular characterization.

REFERENCES

- White TJ, Bruns T, Lee S, Taylor J. Amplification and direct sequencing of fungal ribosomal RNA genes for phylogenetics. In: Innis MA, Gelfand DH, Sninsky JJ, White TJ (eds), PCR Protocols: A Guide to Methods and Applications. San Diego, CA: Academic Press, 1990:315–22.
- Kurtzman CP, Robnett CJ. Identification of clinically important ascomycetous yeasts based on nucleotide divergence in the 5' end of the large-subunit (26S) ribosomal DNA gene. J Clin Microbiol. 1997;35:1216–23.
- Wang X, Wang W, Lin Z, Wang X, Li T, Yu J, et al. CARD9 mutations linked to subcutaneous phaeohyphomycosis and TH17 cell deficiencies. J Allergy Clin Immunol. 2014;133(3):905–08.
- Ajello L. in: Proceedings of the Third International Conference on Mycosis. Scientific publication no.304, Pan American Health Organization Washington DC; 1975;126–133.
- Rinaldi MG. Phaeohyphomycosis. Dermatol Clin. 1996;14(1):147–53.
- Borelli D. Opportunistic fungi producers of gray colonies and mycetomata. Dermatologica. 1979;159:168–74.
- Hoog GS, Guarro J, Gene J, Figueras MJ. Atlas of Clinical Fungi. 2000; 2nd ed.
- Abdoulrasouli A, Ximena G, Anita J, Gordon JM, Nicholas F, Berge S, et al. Subcutaneous phaeohyphomycosis cyst associated with *Medicopsis romeroi* in an immunocompromised host. Mycopathologia. 2016;181(9):717–721.
- Kulkarni M, Jamale T, Hase N, Ubale M, Keskar V, Jagadish PK. Subcutaneous phaeohyphomycosis caused by *Pyrenochaeta romeroi* in a kidney transplant recipient: a case report. Exp Clin Transplant. 2016;15(2):226–27.
- Chan YY, Tan AL, Tan BH. Subcutaneous abscess due to *Pyrenochaeta romeroi* in a renal transplant recipient. Singapore Med J. 2014;55(4):e64–66.
- Badali H, Chander J, Gulati N, Attri A, Chopra R, Najafzadeh MJ, et al. Subcutaneous phaeohyphomycotic cyst caused by *Pyrenochaeta romeroi*. Med Mycol. 2010;48(5):763–68.

- [12] Girard C, Dereure O, Rispaill P, Durand L, Guilhou JJ. Subcutaneous phaeohyphomycosis due to *Pyrenochaeta romeroi* in a patient with leprosy. *Acta Derma Venereol.* 2004;84:154-55.
- [13] Cerar D, Malallah YM, Howard SJ, Bowyer P, Denning DW. Isolation, identification and susceptibility of *Pyrenochaeta romeroi* in a case of eumycetoma of the foot in the UK. *Int J Antimicrob Agents.* 2009;34(6):617-8.
- [14] Khan Z, Ahmad S, Kapila K, Ramaswamy N, Alath P, Joseph L, et al. *Pyrenochaeta romeroi*: a causative agent of phaeohyphomycotic cyst. *Med Microbiol.* 2011;60:842-46.
- [15] Chowdhary A, Perfect J, Sybren GdH. Black molds and melanized yeasts pathogenic to humans. *Cold Spring Harb Perspect Med.* 2014;5(8):a019570.
- [16] Basílio FM, Hammerschmidt M, Mukai MM, Werner B, Pinheiro RL, Moritz S. Mucormycosis and chromoblastomycosis occurring in a patient with leprosy type 2 reaction under prolonged corticosteroid and thalidomide therapy. *An Bras Dermatol.* 2012;87(5):767-71.
- [17] Yang S, Makredes M, O'Donnell P, Levin NA. A case of Hansen disease presenting as tinea versicolour. *Dermatology Online Journal.* 2013;19(4):7.
- [18] Segundo JB, da Silva MA, Filho WE, Nascimento AC, Vidal FC, Bezerra GF, et al. Cerebral aspergillosis in a patient with leprosy and diabetes: a case report. *BMC Res Notes.* 2014;7:689.
- [19] Dashatwar D, Kar S, Gangane N, Pol V, Madke B, Kulkarni S, et al. Chromoblastomycosis in a resident of a leprosarium. *Lepr Rev.* 2015;86(1):102-07.
- [20] Andre M, Brumpt MV, Destombes P, Segretain G. Fungal mycetoma with black grains due to *Pyrenochaeta romeroi* in Cambodia. *Bull Soc Pathol Exot Fil.* 1968;61(1):108-12.
- [21] Serrano JA, Pisano ID, Lopez FA. Black grain mini-mycetoma by *Pyrenochaeta mackinnonii*, the first clinical case of eumycetoma reported in Barinas state, Venezuela-Clinical-histological features and case treatment. *J Mycol Méd.* 1998;8:34-39.
- [22] Young NA, Kwon-Chung KJ, Freeman J. Subcutaneous abscess caused by *Phoma* sp. resembling *Pyrenochaeta romeroi*: unique fungal infection occurring in immunosuppressed recipient of renal allograft. *Am J Clin Pathol.* 1973;59(6):810-16.
- [23] Foulet F, Duvoux C, de Bievre C, Hezode C, Bretagne S. Cutaneous phaeohyphomycosis caused by *Veronaea bothryosa* in a liver transplant recipient successfully treated with itraconazole. *Clin Infect Dis.* 1999;29(3):689-90.
- [24] Thammayya A, Sanyal M, Basu N. *Pyrenochaeta romeroi* causing mycetoma pedis in India. *J Indian Med Assoc.* 1979;73(3-4):66-67.
- [25] Thiyagarajan UM, Bagul A, Nicholson ML. A nodulo-cystic eumycetoma caused by *Pyrenochaeta romeroi* in a renal transplant recipient: a case report. *J Med Case Rep.* 2011;5:460-61.
- [26] Maiti PK, Haldar PK. Mycetomas in two different trauma-prone parts of body: a study of 212 cases. *Indian J Med Microbiol.* 1998;16:19-22.
- [27] Clancy CJ, Wingard JR, Hong Nguyen M. Subcutaneous phaeohyphomycosis in transplant recipients: review of the literature and demonstration of in vitro synergy between antifungal agents. *Med Mycol.* 2000;38:169-75.
- [28] Yadav S, Agarwal R, Singh S, Goel S. *Pyrenochaeta romeroi* causing subcutaneous phaeohyphomycotic cyst in a diabetic female. *Med Mycol Case Rep.* 2015;8:47-49.
- [29] Hasio Y-W, Chia J-H, Lu C-F, Chung W-H. Molecular diagnosis and therapeutic experience of subcutaneous *Pyrenochaeta romeroi* infection: a case report and review of the literature. *International Journal of Dermatology.* 2013;52(10):1237-40.
- [30] Babu K, Murthy PR, Prakash PY, Kattige J, Rangaswamy S, Murthy VR, et al. Chronic endophthalmitis due to *Pyrenochaeta romeroi* in an immunocompetent host-a case report from southern India. *Retin Cases Brief Rep.* 2014;8(3):197-99.
- [31] Ocampo MA, Kanitakis J, Bienvenu AL, Chauvet C, Euvrard S. Phaeohyphomycosis caused by *Pyrenochaeta romeroi* mimicking a plantar wart in a kidney transplant recipient. *Transpl Infect Dis.* 2012;14(6):E173-74.
- [32] Thiyagarajan UM, Bagul A, Nicholson ML. A nodulo-cystic eumycetoma caused by *Pyrenochaeta romeroi* in a renal transplant recipient: A case report. *J Med Case Reports.* 2011;5:460.
- [33] Ferrer C, Pérez-Santonja JJ, Rodríguez AE, Colom MF, Gené J, Alió JL, et al. New *Pyrenochaeta* species causing keratitis. *J Clin Microbiol.* 2009;47(5):1596-98.

PARTICULARS OF CONTRIBUTORS:

1. Specialist, Department of Microbiology, ESIC Hospital, Okhla, New Delhi, India.
2. Senior Research fellow, Department of Medical Mycology, Vallabhshai Patel Chest Institute, University of Delhi, Delhi, India.
3. Postgraduate Student, Department of Microbiology, Vardhman Mahavir Medical College and associated Safdarjang Hospital, New Delhi, India.
4. Senior resident, Department of Microbiology, Vardhman Mahavir Medical College and associated Safdarjang Hospital, New Delhi, India.
5. Head of the Department, Department of Dermatology, Veneorology and Leprosy, Vardhman Mahavir Medical College and associated Safdarjang Hospital, New Delhi, India.
6. Ex-Director and Professor, Department of Microbiology, Vardhman Mahavir Medical College and associated Safdarjang Hospital, New Delhi, India.

NAME, ADDRESS, E-MAIL ID OF THE CORRESPONDING AUTHOR:

Dr. Bhawna Sharma,
Specialist, ESIC Hospital, Okhla, New Delhi-110020, India.
E-mail: bhawna229150@gmail.com

Date of Submission: **May 15, 2017**
Date of Peer Review: **Jun 21, 2017**
Date of Acceptance: **Aug 01, 2017**
Date of Publishing: **Oct 01, 2017**

FINANCIAL OR OTHER COMPETING INTERESTS: None.