

Pancreatic Head Hydatid Cyst Masquerading Cystic Pancreatic Neoplasm in a Young Female

NEERAJ WADHWA¹, UDIT CHAUHAN², SACHIN AGRAWAL³, NEHA NISCHAL⁴, SUNIL KUMAR PURI⁵

ABSTRACT

Hydatid Cyst (HC) disease is a zoonotic infection caused by larval stage of *Echinococcus granulosus*. The disease poses an important public health hazard not only because it is endemic to many parts of the world but also because of migration and travel related spread. HC may develop in almost any part of the body, most commonly found in the liver, followed in frequency by the lung, kidney, brain and bone. Involvement of other organs is rare. In this case report, we describe a rare occurrence i.e., primary HC of pancreas along with review of literature and possible differential diagnosis. Pancreatic HC disease may be associated with complications such as jaundice, cholangitis, and pancreatitis which develop as a result of fistulization of the cyst content into pancreato-biliary ducts or external compression of those ducts by the cyst. Pancreatic HC may mimic pseudocyst or cystic neoplasm of pancreas such as cystadenoma, intraductal papillary mucinous neoplasm, cystic islet cell tumour etc.

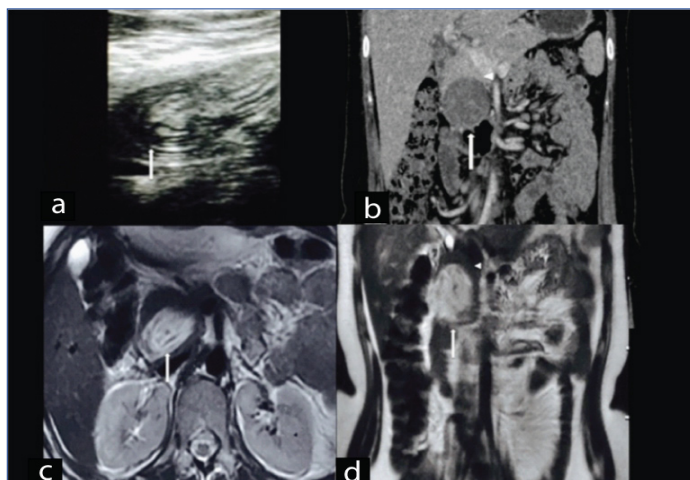
Keywords: Computed tomography, *Echinococcus*, Magnetic resonance imaging, Pancreas, Ultrasound

CASE REPORT

A 30-year-old woman presented to outpatient department with a history of epigastric pain since 2 months, which was intermittent in nature and radiated to the back. It was associated with frequent episodes of nausea and vomiting. General physical examination was unremarkable. No mass was palpable per abdomen. Based on the clinical findings a provisional diagnosis of pancreatitis was suggested and patient was referred to Radiology Department for further evaluation. Serum amylase was done and was found to be raised (252 U/L).

On ultrasound, there was a well defined ovoid heteroechoic lesion of size 5 x 6 cm occupying the head and uncinate region of pancreas with membranes like structure within it [Table/Fig-1a]. Based on

the above findings a possibility of pseudocyst, cystic pancreatic tumour and HC of pancreas was kept. Thus, further evaluation with cross-sectional imaging was asked for as a next line of investigation Contrast Enhanced Computed Tomography (CECT) of abdomen was done and showed a well defined hypodense lesion with internal hyperdense contents in dependent part without peripancreatic free fluid or fat stranding [Table/Fig-1b]. Magnetic Resonance Imaging (MRI) displayed well defined ovoid T2 hyperintense, T1 hypointense cystic lesion with internal membranes within it [Table/Fig-1c,d]. Main Pancreatic Duct (MPD) and Common Bile Duct (CBD) were unremarkable and no communication with cystic lesion was seen. Based on MRI findings pancreatic HC was suggested. ELISA serology for Hydatid Disease (HD) was positive (0.60 OD units). Patient was referred back to Surgery Department for excision of the HC. A cystopericystectomy was done followed by drainage of residual cavity. No communication with MPD or CBD could be seen during surgery. Histopathology confirmed the presence of hydatid membranes and scolices. Postoperative follow up is unremarkable.



[Table/Fig-1a-d]: a) Transverse high resolution sonographic image showed heterogeneously heteroechoic lesion with internal echogenic material (arrow); b) Coronal Contrast Enhanced Computed Tomography (CECT) reveals a well defined hypodense lesion with internal hyperdense contents (arrow); c) Axial; and d) coronal T2W magnetic resonance imaging revealed well defined oval lesion appearing hyperintense on T2W MRI with hypointense internal membrane like contents (arrow in 'c' and 'd'). Note the rim of normal pancreatic parenchyma surrounding the cyst (arrow head in 'b' and 'd').

DISCUSSION

HD is a significant health problem in underdeveloped areas whereas in developed countries, HD is uncommon and is seen only in immigrants or persons with a history of travel to endemic areas [1]. HD can occur anywhere in body, however most common site is liver followed by lung, kidney, brain and bone. HD of pancreas is rare; with reported incidence varying from 0.1% to 2% of patients with HD [2].

It is a slowly growing cystic mass with varying imaging features. HC of pancreas may mimic various pancreatic cystic tumours and may cause complications like secondary pancreatitis, jaundice and cholangitis [3,4]. HC at such unusual locations may pose diagnostic difficulty; therefore early recognition may help in timely diagnosis and treatment.

HD is caused by four types of *Echinococcus* infections, most common being *E. granulosus*, whereas *E. multilocularis* is less common but invasive form, mimicking a malignancy [2]. *Echinococcus vogeli* or Polycystic HD (PHD) is the rarest clinical form. Recently, a new strain

has been identified on the Tibetan plateau, *Echinococcus shiquicus*, but no human infection has been described until date [5].

Primary host is usually a dog and intermediate host may be sheep, cows or pigs and man being an accidental intermediate host [6]. After ingesting vegetables contaminated with infected dog's faeces, ova hatch in the jejunum and embryos cross the intestinal mucosa into the portal system. In most cases, liver (59 to 75%) is the final destination of the intermediate host and lung is the second most frequently involved organ (27%). If the embryo continues through the pulmonary capillary bed, the HC may develop at any site in the body-kidney (3%), bone (1-4%), brain (1-2%) and pancreas (0.1-2%). The most probable route of pancreatic infestation is haematogenous dissemination. Other less common routes include migration of embryos down the bile duct into the pancreatic duct, via the lymphatic circulation from the intestinal mucosa to the pancreas, or by portal blood into pancreatic veins [2,6]. The most common location for HC within pancreas in descending order is the head (57%) followed by body (24%) and tail (19%) of pancreas [7].

A HC has three layers. The outer layer or pericyst, representing host response to the parasite, it is a rigid few millimeters thick layer, consisting of fibroblasts, modified host cells, eosinophils and giant cells. The middle laminated membrane is acellular, it permits the passage of nutrients and disruption of this membrane predisposes to infection. The inner germinal (or generative) layer is thin. Scolices, develop from an outpouching of the germinal layer known as the brood capsule which are the infectious embryonic tapeworms [8,9]. The thickness of these layers depends on the location of the cyst. The layers tend to be thick in the liver, less developed in muscle, absent in bone and sometimes visible in the brain [8,9].

Clinically, presentation of pancreatic HC is variable, depending upon location and mass effect of cyst. However, HC in head of pancreas usually presents with jaundice due to external compression of CBD, while HC in body/tail of pancreas are usually asymptomatic or rarely present as portal hypertension and splenomegaly [10]. In the present case patient came with suspicion of acute pancreatitis with no jaundice, which is a rare presentation associated with pancreatic HC.

Serological tests that can be used for detection of HD are available such as serum IgG antibodies to *Echinococcus* sp. such as indirect haemagglutination test, Enzyme Linked Immunosorbent Assay (ELISA), latex agglutination test, complement fixation, agar gel diffusion. Reported sensitivity of these tests ranges between 85-98% for liver cysts, 50-60% for lung cysts and 90-100% for multiple organ cysts. Specificity of these serological tests is dependent upon cross reactivity of antigen with other cestode infections (*Taenia solium*), helminth diseases, malignancies, cirrhosis and presence of anti-P1 antibodies [7]. Cyst fluid analysis can also be done with markers such: 1) Amylase levels which are raised (more than thousand units per liter) in pseudocyst; and 2) Carcinoembryonic antigen whose values (more than 200 ng/ml) are raised in cystic pancreatic tumour particularly in mucinous epithelial lined cyst [11].

Various imaging modalities are available (USG, EUS, CT, MRI, MRCP, ERCP) that provide morphological information about cystic lesions. These help in delineating characteristic findings for HC such as floating membranes, daughter cyst, hydatid sand and also allow simultaneous guided aspiration cytology for biochemical and cytological analysis which help in differentiating HC from cystic lesions of pancreas [10].

Imaging features of HC involving any tissue may vary ranging from simple cyst to locally invasive mass mimicking malignancy, however imaging findings of liver hydatid have been classified by WHO and Gharbi [Table/Fig-2] [12].

Classical imaging findings of pancreatic HC published in the literature include-multivesicular cyst containing internal daughter cysts, hydatid sand-layering of scolices within cyst, water lily sign- floating internal membranes and cyst wall calcification along with positive

hydatid serology [3,11,13]. In the present case, imaging revealed a large well-defined cystic lesion within head of pancreas with internal membrane like structure though not typical for diagnosis of HC but was possible because of high index of suspicion along with laboratory evidences.

Differentiation of cystic lesions of pancreas is important as 80% are pseudocysts and only 10% are the cystic neoplasms which requires surgical excision [2]. The differential diagnosis of cystic lesions of the pancreas is broad and is tabulated below [Table/Fig-3] [14-19].

As primary HC of pancreas is rare and characteristic radiological findings are often not present, so differentiation of pseudocyst and cystic pancreatic lesions from HC is important for appropriate patient treatment [10].

The current definitive treatment of HD is surgical excision. If there is no communication between the cyst cavity and the bile

WHO	Gharbi	US Characteristics
CE 1	Type I	Pure fluid collection, unilocular non complicated cyst ± internal echogenicities.
CE 3	Type II	Cyst with internal floating membranes, representing detached endocyst.
CE 2	Type III	Cyst with internal daughter cyst and septations-Multivesicular, multiseptated cyst.
CE 4	Type IV	Cyst with heterogenous solid pattern consisting on thick membranes ± few daughter cyst.
CE 5	Type V	Calcified cyst with thick reflecting walls, non viable involuted cyst.

[Table/Fig-2]: WHO and Gharbi Classification of HC of liver –US findings.

*WHO- World Health Organisation; CE- Cystic Echinococcosis

Neoplastic Lesions	Non Neoplastic Lesions
Cystadenoma–Serous/mucinous	Pseudocyst of pancreas.
Cystadenocarcinoma	Syndromic association with cysts (VHL), Autosomal dominant polycystic disease, Cystic fibrosis.
Intraductal papillary mucinous neoplasm	Infections: HC, Abscess.
Cystic islet cell tumour	
Papillary cystic and solid tumours	
Miscellaneous cysts: Cystic acinar cell carcinoma, Cystic teratoma, Epidermoid cystic metastasis, Vascular tumours (haemangioma, lymphangioma) etc.	Miscellaneous cysts: Lymphoepithelial cysts, duplication cysts, congenital epithelial cysts, cystic hamartoma etc.

[Table/Fig-3]: Differential diagnosis of cystic pancreatic lesions.

or pancreatic ducts, scolical agents are injected to sterilize the cyst contents before excision. However, if the cyst is located in the vicinity of vital anatomical structures, removal of cyst contents with or without partial cystectomy is done [2]. PAIR (Puncture, Aspiration, Injection and Re-aspiration) is a minimally invasive technique used in the treatment of HC in the liver and other abdominal locations, indicated for inoperable patients and those who refuse surgery or in cases of relapse after surgery [20,21]. Complications such as pancreatic fistula may develop after partial cystectomy when there is communication between the cyst and the pancreatic duct. In such cases, a Roux-en-Y pancreaticojejunostomy is advisable [2].

CONCLUSION

HC can occur in pancreas and may lead to secondary pancreatitis. On imaging it may simulate pseudocyst or cystic pancreatic neoplasm. Strong imaging suspicion along with laboratory aid and high index of suspicion may help in early diagnosis and management so as to avoid fatal life threatening complications.

REFERENCES

- [1] Bouree P. Hydatidosis: dynamics of transmission. World J Surg. 2001;25:04-09.
- [2] Krige J, Mirza K, Bornman P, Beningfield S. Primary hydatid cysts of the pancreas. S Afr J Surg. 2005;43:37-40.
- [3] Lemmer ER, Krige JEJ, Price SK, Girdwood AH. Hydatid cyst in the head of the pancreas with obstructive jaundice. J Clin Gastroenterol. 1995;20:136-38.

- [4] Coskun T, Kama NA, Dener C, Gözalan U. Primary hydatid disease of the pancreas. *Am J Gastroenterol*. 1997;92:899-900.
- [5] Xiao N, Qiu J, Nakao M, Li T, Yang W, Chen X, et al. *Echinococcus shiquicus*, a new species from the Qinghai – Tibet plateau region of China: Discovery and epidemiological implications. *Parasitol Int*. 2006;55:S233-36.
- [6] Engin G, Acunas B, Rozanes I, Acunas G. Hydatid disease with unusual localization. *Eur Radiol*. 2000;10:1904-12.
- [7] Shah OJ, Robbani I, Zargar SA, Yattoo GN, Shah P, Ali S, et al. Hydatid cyst of the pancreas. An experience with six cases. *Journal of the Pancreas*. 2010;11(6):575-81.
- [8] Pedrosa I, Saiz A, Arrazola J, Ferreiros J, Pedrosa CS. Hydatid disease: radiologic and pathologic features and complications. *Radiographics*. 2000;20(3):795-817.
- [9] Polat P, Kantarci M, Alper F, Suma S, Koruyucu M, Okur A. Hydatid disease from head to toe. *Radiographics*. 2003;23:475-94.
- [10] Ahmed Z, Chhabra S, Massey A, Vij V, Yadav R, Bugalia R, et al. Primary hydatid cyst of pancreas: Case report and review of literature. *International Journal of Surgery Case Reports*. 2016;27:74-77.
- [11] Basturk O, Coban I, Adsay NV. Pancreatic cysts: pathologic classification, differential diagnosis, and clinical implications. *Archives of Pathology & Laboratory Medicine*. 2009;133(3):423-38.
- [12] Dusak A, Onur MR, Cicek M, Firat U, Ren T, Dogra VS, et al. Radiological imaging features of fasciola hepatica infection – a pictorial review. *J Clin Imaging Sci*. 2012;2:2.
- [13] Alizadeh AH. Primary hydatid cyst of the pancreas: a review. *J Pancreas (Online)*. 2016;17(3):250-56.
- [14] Le Borgne J. Cystic tumours of the pancreas. *Br J Surg*. 1998;85(5):577-79.
- [15] Astiz JM, Astiz L, Buzzi A. Primary hydatid cyst mistaken for carcinoma of the pancreas. *J R Soc Med*. 1997;90:334.
- [16] Box JC, Douglas HO. Management of cystic neoplasms of the pancreas. *Am Surg*. 2000;66(5):495-501.
- [17] Martin I, Hammond P, Scott J, Redhead D, Carter DC, Garden OJ. Cystic tumours of the pancreas. *Br J Surg*. 1998;85:1484-86.
- [18] Panieri E, Krige JE, Bornman PC, Graham SM, Terblanche J, Cruse JP. Operative management of papillary cystic neoplasms of the pancreas. *J Am Coll Surg*. 1998;186:319-24.
- [19] Worrall NK, Drebin JA. Pancreaticoduodenectomy for lymphoepithelial cyst of the pancreas. *Am Surg*. 2000;66:732-34.
- [20] Gupta N, Javed A, Puri S, Jain S, Singh S, Agarwal AK, et al. Hepatic hydatid: PAIR, drain or resect? *Journal of Gastrointestinal Surgery*. 2011;15(10):1829-36.
- [21] Corona M, Cannavale A, Bruni A, Boatta E, Allegritti M, Lucatelli P, et al. Case report: Percutaneous treatment of multiple honeycomb-like liver hydatid cysts (type III CE2, according to WHO classification). *The Indian Journal of Radiology & Imaging*. 2012;22(1):23.

PARTICULARS OF CONTRIBUTORS:

1. Senior Resident, Department of Radiology, GB Pant Hospital, New Delhi, India.
2. Senior Resident, Department of Radiology, GB Pant Hospital, New Delhi, India.
3. Senior Resident, Department of Radiology, GB Pant Hospital, New Delhi, India.
4. Senior Resident, Department of Radiology, GB Pant Hospital, New Delhi, India.
5. Director, Professor and Head, Department of Radiology, GB Pant Hospital, New Delhi, India.

NAME, ADDRESS, E-MAIL ID OF THE CORRESPONDING AUTHOR:

Dr. Neeraj Wadhwa,
BA-66, Shalimar Bagh (West), New Delhi-110088, India.
E-mail: drneerajwadhwa@yahoo.in

Date of Submission: **May 08, 2017**

Date of Peer Review: **Jun 16, 2017**

Date of Acceptance: **Aug 18, 2017**

Date of Publishing: **Oct 01, 2017**

FINANCIAL OR OTHER COMPETING INTERESTS: None.