

Odontoma Associated With Non-Syndrome Multiple Supplemental Supernumerary Teeth

Meetkamal and Parwinder Kaur

ABSTRACT

Odontomes are considered as developmental anomalies resulting from the growth of completely differentiated epithelial and mesenchymal cells that give rise to ameloblasts and odontoblasts. These tumours are formed of enamel and dentin, but they can also have a variable amount of cementum and pulp tissue. Odontomes are defined as tumours of odontogenic origin. They are considered to be hamartomatous malformations rather than true neoplasms and are generally asymptomatic. Here, we report a case of a 20 year old female patient who visited a private dental clinic with a chief complaint of pain in the lower left

back tooth region since 15 days. Familial, medical, and dental history or extra oral findings did not reveal any abnormality. Intra oral examination revealed pericoronitis in relation to 38. The patient was sent for OPG, which revealed a classic picture of impacted 38, along with numerous small radio-opaque masses surrounded by radiolucent border. A provisional diagnosis of odontome was made. The odontome were surgically removed and sent for histopathological examination, which revealed features which were suggestive of odontoma of the compound composite type.

INTRODUCTION

Odontomes are benign tumours containing all the various components of the odontogenic tissue [1]. They are considered as hamartomatous malformations of both ectodermal and mesodermal cell origin [2]. They seem to result from a budding of extra odontogenic epithelial cells from the dental lamina [1],[3]. Odontomes frequently go undetected because they are asymptomatic, depending on the size, location and their unlimited growth potential. They are often diagnosed in the 2nd or 3rd decades of life during routine radiographic examinations [4].

The lesions are composed of more than one type of tissue and are called as composite odontomes [5].

According to the different degrees of their histodifferentiation and morphodifferentiation, they are divided into two types of malformations which have been described so far as [5],[6] :-

1. Complex composite odontoma – wherein the dental tissue mass is totally disorganized.
2. Compound composite odontoma- wherein the dental tissue bears some anatomical resemblance to a normal tooth.

Supernumerary teeth are those that are an excess of the normal complement and mimic the shape [7] of normal teeth. These teeth have been reported in the literature over the years as a well recognized clinical phenomenon [8]. Multiple supernumerary teeth are commonly associated with the variable syndrome [9]. However, the presence of multiple supernumerary teeth in the absence of any systemic condition/syndrome is unusual [10].

A case of an asymptomatic odontogenic tumour- Odontome in the posterior of the maxilla, along with non syndrome multiple supernumerary teeth in the mandible of a 20 year old female patient is presented here.

CASE REPORT:

Here, we report a case of a 20 year old female patient who visited a private dental clinic with a chief complaint of pain in the lower left back tooth region since 15 days. Familial, medical, and dental

history was not of any significance. Extra oral findings did not reveal any abnormality.

Intra oral examination revealed pericoronitis in relation to 38. The patient was sent for OPG.

OPG revealed a classic picture of impacted 38, along with numerous small radio-opaque masses, surrounded by radiolucent border [Table/Fig 1].

Also, many unerupted supernumerary teeth were seen [Table/Fig 1] and [Table/Fig 2]. They appeared as four distinct, separate calcified structures resembling mandibular premolars as seen in [Table/Fig 2].

The developing premolars were observed to be lying in their respective dental sacs with partially developed roots. A general physician was consulted, who confirmed that there was no associated syndrome. 38 was extracted. A provisional diagnosis of odontome was made. No invasive treatment was done for the supernumerary teeth, but for the odontome, the patient and her mother were educated and counselled about the radiographical findings. The odontome was surgically removed. The lesion was removed in totality and was sent for histopathology.

HISTOPATHOLOGY

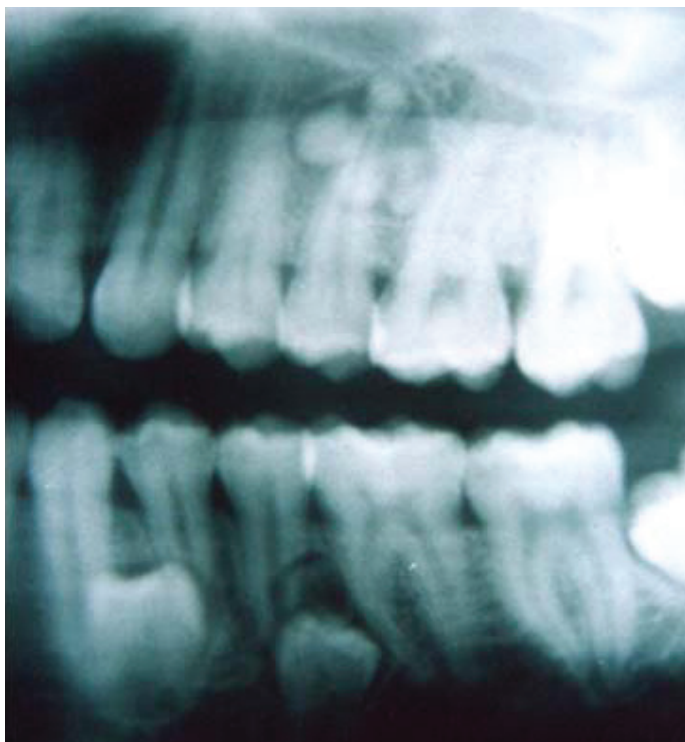The decalcified section, when stained with H/E, showed the loss of the enamel cap of the tooth like structure [Table/Fig 3] and [Table/Fig 4].

A varying amount of enamel matrix, dentin and pulp like tissue was seen in the coronal portion of the tooth like structure [Table/Fig 5].

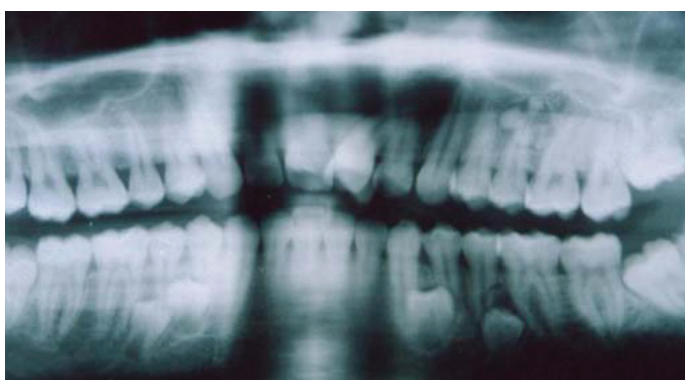A very thin layer of cementum like tissue was seen on the root portion. The connective tissue stroma was normal and resembled that of the normal follicles which surrounded the tooth. These features were suggestive of odontoma which was of the compound composite type.

DISCUSSION

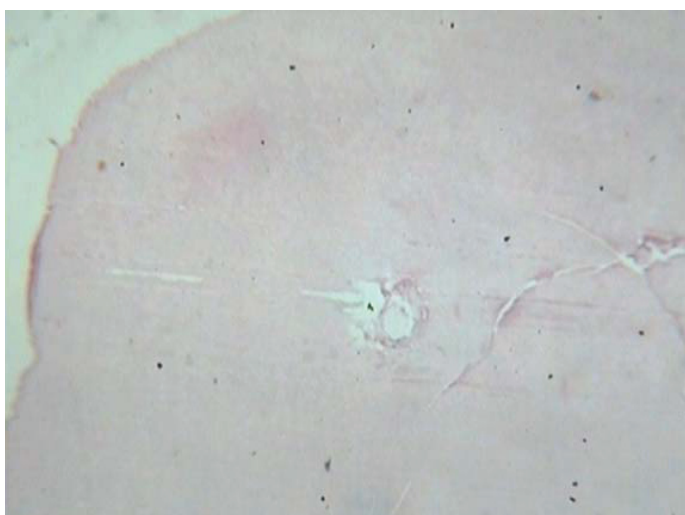
Odontoma arises in 22% of the cases, with a predilection for compound composite odontoma in the anterior of the maxilla and more so, in males [11]. Some authors prefer to refer it as a



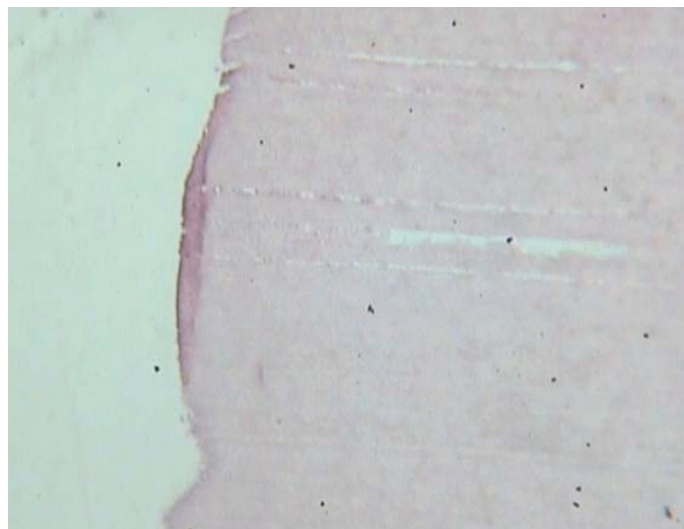
[Table/Fig 1]: IOPA shows 2 unerupted supernumerary teeth in the mandible and numerous small radio-opaque masses in the maxilla.



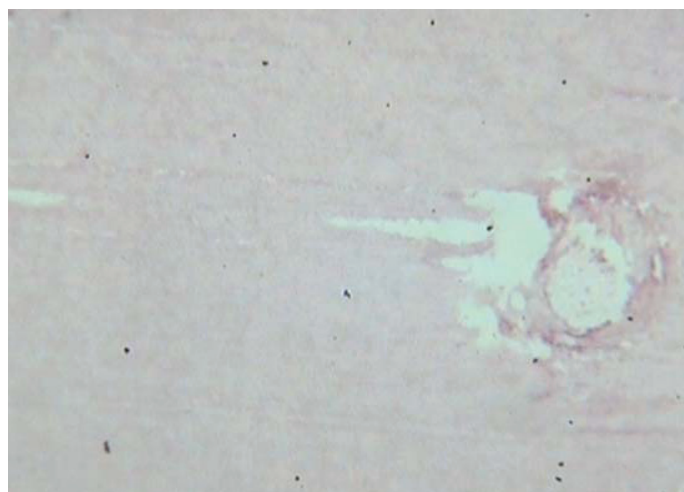
[Table/Fig 2]: OPG shows presence of 4 distinct, separate calcified structures resembling mandibular premolars were observed and numerous small radio-opaque masses in the maxilla.



[Table/Fig 3]: Decalcified stained tissue section when seen under scanner shows varying amount of dentine and pulp in the coronal portion of the tooth like structure.



[Table/Fig 4]: Decalcified stained tissue section under 10x shows loss of enamel cap of the tooth like structure.



[Table/Fig 5]: Decalcified stained tissue section under 10x shows varying amount of dentin, and pulp like tissue is seen in coronal portion of tooth like structure.

hamartoma and not a true tumour[12]. Paul Broca, in 1867, first used the term "odontome" [13]. Odontoma in its early formative stage is known as Odontoblastoma, which is made up of neoplastic epithelial and mesenchymal cells, which are in the process of differentiating into cells that are able to produce calcified tooth-like tissue, namely enamel, dentin and cementum. This tissue continues to form in an abnormal arrangement until the growth of the tumour cell becomes exhausted and only the calcified tooth-like substance is seen in the form of denticles. At this stage, the soft tissue ceases its activity and remains as a fibrous capsule around the tumour mass. This final stage is known as 'Odontoma'[14].

In 1914, Gabell, James and Payne grouped odontomes according to their developmental origin: epithelial, composite (epithelial and mesodermal) and connective tissue.

In 1946, Thoma and Goldman formulated a classification for odontomes [15]

- **Geminated composite odontomes:** Two or more, more-or-less well-developed teeth fused together.
- **Compound composite odontomes [CpdCO]:** Made up of more-or-less rudimentary teeth.

- **Complex composite odontomes [CpxCO]:** Calcified structure which bears no great resemblance to the normal anatomical arrangement of the dental tissues.
- **Dilated odontomes:** The crown or the root part of the tooth shows marked enlargement.
- **Cystic odontomes:** Odontomes that are normally encapsulated by fibrous connective tissue in a cyst or in the wall of a cyst. According to the WHO classification, odontomes can be divided into three groups [16]
 - ◆ Complex odontomes: When the calcified dental tissues are simply arranged as an irregular mass, bearing no morphological similarity to the rudimentary teeth.
 - ◆ Compound odontomes : Composed of all odontogenic tissues in an orderly pattern that result in many teeth -like structures, but without any morphological resemblance to normal teeth.
 - ◆ Ameloblastic fibro-odontomes: Consist of varying amounts of calcified dental tissues and dental papilla- like tissue, the latter component resembling an ameloblastic fibroma. The ameloblastic fibro-odontome is considered to be an immature precursor of a complex odontome.

A new type known as 'hybrid odontome' has also been reported by some authors [17].

Odontomas are also classified as intraosseous and extraosseous odontomas. The intraosseous odontomas occur inside the bone and may erupt into the oral cavity (erupted odontomas). The extraosseous or peripheral odontomas are odontomas occurring in the soft tissue, covering the tooth bearing portion of the jaws and having a tendency to exfoliate [18], [19].

CpdCO has a predilection for the maxilla, then the mandible and that also in the anterior region whereas, CpxCO is seen in the posterior of the maxilla and then the mandible. All Odontomas develop during the period of normal odontogenesis and eruption. As they do not show any symptoms, they remain undetected for years and once removed, they seldom reoccur [5],[6],[8].

The CpdCOs can be diagnosed by radiographical examination. Whereas, the CpxCOs usually present a typical radiographical appearance because of their solid opacification with relationship to teeth. So, a differential diagnosis might include other opaque jaw lesions such as focal sclerosing osteitis, osteoma, periapical cemental dysplasia, ossifying fibroma and cementoblastoma.[20]

The literature reports a 0.2-0.9% prevalence of supernumerary teeth within the mandible and the maxilla [21]. They may occur in any region of the dental arch with a particularly predictions for the maxilla [22],[23]. They may occur singly, in multiples, unilaterally or bilaterally and in one or both the jaws. The presence of single supernumerary teeth associated with the permanent dentition is usually seen in the anterior maxilla [24].

Multiple supernumerary teeth are commonly associated with variable syndromes like [9]:

- a. Cleido's cranial dysplasia
- b. Gardner's Syndrome
- c. Orodigito's Facial Dystosis
- d. Down's Syndrome
- e. Crouzon's Disease
- f. Hallermann Streiff's Syndrome

However, such teeth are rare in the absence of any syndromes / systemic conditions [9],[10].

The exact aetiology of supernumerary teeth is still uncertain, as many theories have been proposed. The two most accepted theories are:

- The dichotomy theory of the tooth germ states that the tooth bud splits into two equal or different sized parts, resulting in two teeth of equal size or in one normal and one dysmorphic tooth, respectively. This hypothesis is supported by animal experiments in which split germs have been cultivated in vitro [25],[26].
- The localized and independent hyperactivity of the dental lamina is the other accepted theory, which suggests that supernumerary teeth are formed as a result of local, independent and conditioned hyperactivity of the dental lamina [22],[26]

Different classifications of supernumerary teeth have been proposed by various authors, based on their location in the dental arch or on their morphology. Terms like hyperdontia or accessory teeth have been used, but there exists minute distinguishing features. Accessory teeth do not have a normal form and have a morphology that deviates from the normal appearance of the teeth [7]. The term 'supplemental teeth' is however used when the teeth are extra, but have the shape and size of normal teeth [27].

The presence of multiple supernumerary teeth is usually associated with problems of displacement, rotation, ectopic eruption of the adjacent teeth, resorption of the adjacent teeth and even the formation of primordial cysts [10].

In this case, a CpdCO was present in the posterior of the maxilla and it was seen in a female patient, which is quite contrary to the normal documented site and sex of the lesion, along with Non Syndrome multiple unerupted supplemental teeth. The full complement of the permanent dentition was present in the normal occlusion with none of the associated potential problems as stated above, which was an unexpected and a rare finding, as the patient was completely asymptomatic and the presence of the Odontoma along with multiple supplemental teeth was an incidental finding.

CONCLUSION

A case of CpdCO occurring in the posterior of the maxilla in 20 year old female patient with characteristic histopathological features which were associated with unerupted multiple supplemental teeth, has been reported.

The Odontoma was removed in totality, since it did not invade the bone locally. The prognosis was excellent and recurrence is rare in such lesions.

For the multiple supplemental teeth, each case must be therefore considered individually, concerning its treatment, taking into account untoward developments like displacement, rotation, resorption of the adjacent teeth, formation of primordial cysts, etc. Close observation with regular radiographical controls is recommended in such cases.

Conflict of Interest : None

Funding : Nil

REFERENCES:

- [1] Wood NK and GOAZ PW Differential diagnosis of oral and maxillofacial lesions. Har court Brace and company Asia Pt Ltd 1998 ;467-469.
- [2] Swant RH.Odontomas: a review, case presentation and periodontal considerations in treatments". J. Periodontal. 1987;58(12):856-860.
- [3] Jacobson JK.. "The Odontomas". Am .J. Ortho. 1946;32:147-152.

- [4] Rad AS and Reid J Delayed eruption of permanent molars associate with complex Odontoma: report of case". J DENT. Child; July – Aust;1996;299-301.
- [5] Stasin Poulous M MIXED CALCIFIED ODONTOGENIC TUMOR. Brit J. Oral Surg. 1970;8:93-100
- [6] De Visscher Jan G.A.M. COMPOUND ODONTOMA WITH DISPLACED TOOTH BUDS: REPORT OF CASE WITH 4 YR FOLLWUP. J. Oral Surg. 1981;39:359-361
- [7] Bhaskar SN .Synopsis of Oral Pathology. C. V. Mosby St Louis : 1961;p17
- [8] Shafer's text book of oral pathology- 5th edition; 2006;404-407.
- [9] Moore SR, Wilson DF, Kibble J. Sequential development of multiple supernumerary teeth in the mandibular premolar region – a radiographic case report. Int. J Pediatric. Dent2002; 12:143-5.
- [10] Hegde SV, Munshi AK .Late development of supernumerary teeth in premolar region: A case report. Quintessence Int. 1996;27:479-81
- [11] SAMRAJ. T, RAVI H.R. and SHIELA NAIR. Cystic complex composite odontome J. Ind. Dent. Asso. 1985;57:57-60
- [12] Cohen DM ,Bhattacharyya I.Ameloblastic fibroma ,ameloblastic fibro-odontoma and odontoma .Oral Maxillofac Surg Clin North Am 2004;16:375-84
- [13] Batra P ,Gupta S , Rajan K,Duggal R Hariparkash. Odontomes - Diagnosis and Treatment: A 4 Case Report. J Pierre Fauchard Acad 2003;19:73-6.
- [14] Lucas R.B. Pathology of tumors of oral tissue 4th edition, Chruchill Livingstone Edin Burg. 1984 ;82-89
- [15] Thoma KM, Goldman HM. Oral Pathology. 5 th ed. The CV Mosby Company: St Louis; 1960. p. 1221-2.
- [16] Kramer IR, Pindborg JJ, Shear M. Histological Typing of Odontogenic Tumour. WHO. International Histological Classification of Tumours. 2nd ed. Berlin Springer: 1992. p. 16-21.
- [17] Singh S, Singh M, Singh I, Khandelwal D. Compound composite odontome associated with an unerupted deciduous incisor - A rarity. J Indian Soc Pedod Prev Dent. 2005;23:146-50.
- [18] Vengal M, Arora H, Ghosh S, Pai KM. Large erupting complex odontoma: A case report. J Can Dent Assoc. 2007;73:169-72.
- [19] Reichart PA, Philipsen HP. Odontogenic tumors and Allied lesions. Quintessence: London; 2004. p. 149-53
- [20] Regezi JA , Scinbba JJ and Jordan RCK . Oral Pathology:Clinical pathologic correlations. ed 5th ,saunders ,Elsevier 2008;p 279-281
- [21] Sani T, Keene JJ Jr, Whetten J .Radiographic diagnosis of supernumerary premolars: Case reviews. ASDC J Dent Child. 2002;69:184-90
- [22] Primosch R. Anterior supernumerary teeth: Assessment and surgical intervention in children. Pediatric Dent. 1981;2:204-15.
- [23] Nasif MM, Ruffalo RC, Zullo T. Impacted supernumerary teeth: A survey of 50 cases. J Am Dent Assoc. 1983;106:201-4.
- [24] Zhu JF, Marcushamer M, King DL, Henry RJ. Supernumerary and congenitally absent teeth: A literature review. J Clin. Pediatric. Dent. 1996;20:87-95.
- [25] Tylor GS. Characteristics supernumerary teeth in primary and permanent dentition. Dental Practioner and Dental Records 1972;22:203-8.
- [26] Liu JF. Characteristics of pre maxillary supernumerary teeth: A survey of 112 cases. ASDC J Dent Child. 1995;62:262-5.
- [27] Pindborg JJ. Pathology of the Dental Hard Tissues. WB Saunders : Philadelphia; 1970. p. 27.

AUTHORS:

1. Dr. Meekamal: MDS, Prof and head of the department of Oral Pathology, Gian Sagar Dental College Banur
2. Dr. Parwinder Kaur: MD, Astd. Prof. PATHOLOGY, Gian Sagar Medical College Banur

NAME, ADDRESS, TELEPHONE, E-MAIL ID OF THE CORRESPONDING AUTHOR:

Dr. Meet Kamal, House no.1059, Sect.2, Panchkula-134112, Haryana, Phone no: (0)9417003548, 9779574202
E-mail: meetmeet2000@yahoo.com

DECLARATION ON COMPETING INTERESTS: No competing Interests.

Date of Submission: **09/21/2010**
Peer Review Completion: **10/19/2010**
Date of Acceptance: **10/19/2010**
Date of Publish: **02/06/2011**