

# Bilateral Chondroepitrochlearis Muscle: Incidence, Phylogenetic And Clinical Significance

S Aruna, R Hannah Sugirthabai Rajila and Vaithianathan G

## ABSTRACT

To study the incidence and the phylogenetic and the clinical implications of a rare variant muscle slip arising from the pectoralis major muscle in the Indian population. In this article, we have described a muscle slip which is present bilaterally, which originates from the lower ribs along with the lower fibres of the pectoralis major muscle. This muscle slip arches across the axilla and then inserts to the medial epicondyle of the humerus.

The phylogenetic relationship of the muscle to the abdomino humeralis or to the xiphohumeralis in quadrupeds and to the patagii muscle in birds is discussed. The clinical significance of this muscle is also discussed, as the chondro epitrochlearis muscle forms an important differential diagnosis for ulnar nerve entrapment. It is also an important but a rare cause of the restriction of movements at the shoulder joint.

**Key Words:** Pectoralis major, Chondroepitrochlearis, Ulnar nerve, Phylogeny

## INTRODUCTION

The muscle mass of the pectoral region exhibits a variety of variations in the form of anomalous slips. The pectoralis major muscle is a thick triangular muscle that usually arises from the medial half of the clavicle, the sternum, and the first six costal cartilages. These three heads, the clavicular, the sternocostal and the abdominal, combine to form a tendon that inserts into the lateral lip of the bicipital groove of the humerus, after undergoing a twist. The pectoralis major muscle is innervated by the medial and the lateral pectoral nerves. The most common variations of the pectoralis major muscle include the absence of the abdominal slip, the decussation of the fibres across the midline and the absence of the sternocostal head [1], [2]. Mosconi and Ka-Math [3] have described a case in which the sternocostal head of the pectoralis major muscle was absent on the left and the entire pectoralis major muscle was absent on the right. Several cases of an additional musculature in the axillary region have also been reported. These include the following: a sternalis muscle which runs parallel to the sternum [4],[5] and a pectoralis quartus muscle which arises from the rectus sheath [6] runs parallel to the pectoralis major muscle and inserts into the tendon of the pectoralis major [1].

The chondroepitrochlearis (thoracoepicondylaris) muscle arising from the lateral edge of the pectoralis major muscle and inserting into the medial epicondyle of the humerus, has been reported by Chiba [7] as a unilateral variation and by G. Flaherty [8] as a bilateral variation, but its incidence has yet to be reported. The co-existence of both the chondroepitrochlearis and the muscular arch muscle has been reported. In the present study, the authors have tried to learn the incidence and the phylogenetic and the clinical significance of this anomalous muscle slip in the Indian population.

## MATERIALS AND METHODS

A total of forty cadavers which were embalmed with a 40% formalin solution were taken up in the Department of Anatomy, Chettinad Hospital and Research Institute, Kelambakkam, Tamil Nadu, Chennai, to study the chondroepitrochlearis muscle in detail. Out of the forty cadavers, thirty were males and ten were females. The study period was four years. Hence, a total of eighty upper limbs

were studied in detail. The well preserved cadavers were taken and an uppermost incision was made directly over the clavicle. Another incision was made in the midline from the suprasternal notch to the xiphisternum. From the xiphisternum to the base of the axilla, another curved incision was made till the middle of the forearm, making an encircling cut around the nipple and areola, leaving them in place for future reference, reflecting the flaps of skin and the superficial fascia downwards and laterally. A midline incision was made in the arm reflecting the flaps on both sides till the middle of the forearm. The fascia from the anterior parts of the pectoralis major were removed and the attachments of the same were defined.

The clavicular head of the pectoralis major below the clavicle was cut across and was reflected towards its insertion. The branches of the lateral pectoral nerve and the thoracoacromial artery pierced the clavipectoral fascia to enter it. The remainder of the pectoralis major was cut across about 5cm from the sternum. A branch of the medial pectoral nerve pierced the pectoralis minor to enter the pectoralis major. In the level of the lowermost origin of the pectoralis major, the small muscle slip, namely the chondroepitrochlearis, was looked for. The slip, as described before, as originating from the lower costal fibres and arching over the base of the axilla was searched for, in the eighty study specimens. The course and its tendinous change, along with its insertion into the medial epicondyle, was studied in detail by measuring the length of the muscle and the tendon in centimetres. Its dimensions, attachments and nerve supply and the extent and its relations with the neurovascular bundle of the arm were studied.

## RESULTS

Out of the eighty upper limbs which were dissected and studied, we came across the chondroepitrochlearis muscle slip in two upper limbs, with an incidence of 2.5% in the total study population. The muscle slip was present in a male cadaver bilaterally, as against the more common unilateral variation. The unilateral chondroepitrochlearis has been reported more often than the bilateral variant. The findings by different authors regarding the chondroepitrochlearis, has been enumerated in [Table/Fig 1]. In our study, the incidence of the unilateral variant was zero and the incidence of the bilateral variant was 2% of the total study population.

S.No	Authors	Years	UNI/Bilateral
1	Di Gennaro G L et al.[13]	1998	Bilateral
2	G. Flaherty et al. [8]	1998	Bilateral
3	R. J. Spinner et al. [12]	1991	Unilateral
4	Loukas Marios et al. [4]	2004	Unilateral
5	Levent Sarikcioglu et al. [22]	2004	Unilateral
6	P Jaijesh [23]	2005	Unilateral
7	Vijay Paul Samuel et al [14]	2008	Unilateral
8	Nakijima et al [11]	1999	Unilateral with axillary arch muscle

[Table/Fig 1]: Findings by different authors regarding the chondroepitrochlearis

Similarly, the incidence of the chondroepitrochlearis in the male cadavers was two out of the sixty upper limbs, as against 0 in twenty female upper limbs. Hence, the incidence in males is derived as 3.3%, as compared to the absence of such a variation in the female study population, as shown in [Table/Fig 2].

S.No	Sex	Total Specimens	Presence of Chondroepitrochlearis
1	Male	60	2
2	Female	20	0

[Table/Fig 2]: Incidence in males and Females

A Z calculate was used to compare the means from different normally distributed sets of data. The actual score indicates how many standard deviations above or below the mean an observation is. The Z calculated value for male and female incidence was  $0.6818 \pm 0.05$ . This value was less than 1.96, which gave us no reason to reject the null hypothesis. The null hypothesis is a hypothesis about a population parameter. The purpose of the hypothesis testing was to test the viability of the null hypothesis in the light of experimental data. Depending on the data, the null hypothesis either would or would not be rejected as a viable possibility. Hence, the 0 incidence in the females in our present study doesn't rule out the occurrence of this variant in females, provided the sample size is bigger than the one which was used for this present study.

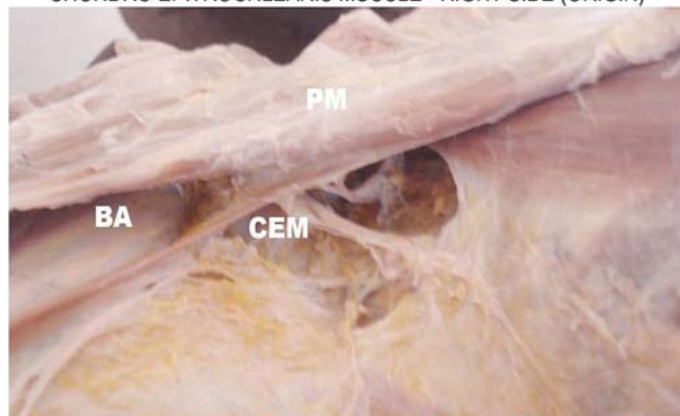
## DISCUSSION

The pectoralis major is a thick, fan-shaped muscle. Its origin is from the anterior surface of the sternal half of the clavicle, to half of the breadth of the anterior surface of the sternum, to the first to the seventh costal cartilages, to the sternal end of the sixth rib and to the aponeurosis of the external oblique. It gets inserted as a bilaminar tendon into the lateral lip of the intertuberosus sulcus of the humerus. The anterior lamina is composed of the clavicular and the manubrial fibres. The posterior lamina has the costal fibres which insert without twisting and the sternal and the aponeurotic fibres which undergo a twisted insertion.

Bergman et al. (1988) in their book on anatomical variations, were the first to refer to this variant as 'costoepitrochlearis, chondroepitrochlearis, or chondrohumeralis'. The chondroepitrochlearis is an extremely rare anomaly which arises as a small muscle slip of 1cm diameter from the lowermost muscle costal fibres of the pectoralis major ([Table/Fig 3], [Table/Fig 4]).

This muscle slip which is present bilaterally, is a finding which has been reported earlier by only by two authors till date. This slip arched over the base of the axilla and travelled on the medial most part of the anterior compartment of the arm. It was seen embedded within the

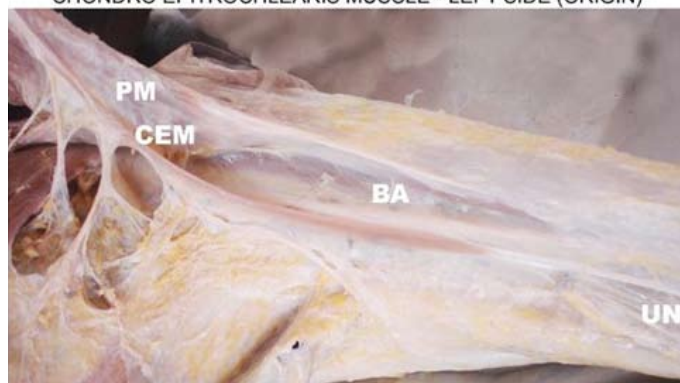### CHONDR OEPITROCHLEARIS MUSCLE - RIGHT SIDE (ORIGIN)



PM - PECTORALIS MAJOR BA - BRACHIAL ARTERY  
CEM - CHONDR OEPITROCHLEARIS MUSCLE

[Table/Fig 3]: Chondroepitrochlearis muscle- Right side (Origin)

### CHONDR OEPITROCHLEARIS MUSCLE - LEFT SIDE (ORIGIN)



PM - PECTORALIS MAJOR BA - BRACHIAL ARTERY  
CEM - CHONDR OEPITROCHLEARIS MUSCLE UN - ULNAR NERVE

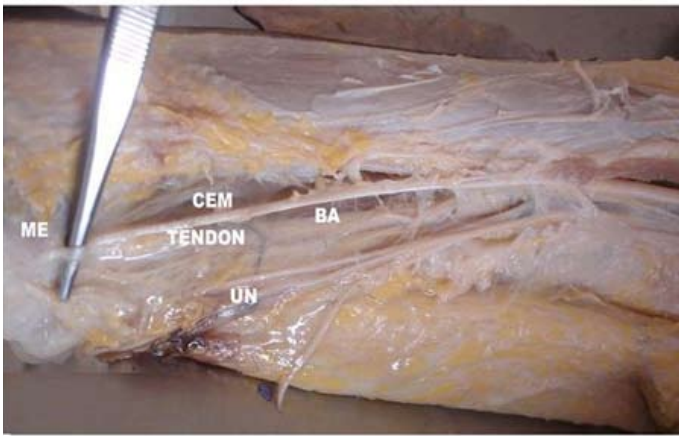
[Table/Fig 4]: Chondroepitrochlearis muscle- Left side (Origin)

brachial fascia, with the brachial artery related on its lateral side. The muscle slip turned tendinous at about 15cm from its origin ([Table/Fig 5], [Table/Fig 6]). It continued its course as a tendon for 21cm medially to get inserted into the medial epicondyle of the humerus. The ulnar nerve is closely applied to the posteromedial aspect of the tendon in the middle of the arm before it pierces the medial intermuscular septum ([Table/Fig 7]). The pectoralis major muscle never underwent the normal twisting before its insertion. ([Table/Fig 3], [Table/Fig 4]). The medial pectoral nerve and the lateral thoracic artery supplied the muscle slip. This pattern of innervation confirms to its embryological origin from the ventral muscle mass.

Embryologically, the pectoral musculature is derived from the ventral limb bud masses which arise from the myoblasts that migrate out of the last five cervical and the first thoracic myotomes into the developing limb buds during the fifth week of the intrauterine life [9]. The pectoral muscles assume their final forms through a combination of migration, fusion and apoptosis of the muscle cell precursors [10]. The failure of apoptosis to occur at the right time in the myoblasts, can result in the persistence of a muscle slip in the form of the chondroepitrochlearis.

Phylogenetically, the chondroepitrochlearis is regarded as an atavistic anomaly which is a trait which reappears after having disappeared generations before. It is an equivalent of the abdominoor xiphohumeralis of the quadrupeds, a muscle which is now considered as a part of the pectoralis minor (Howell, 1937). Also, it is regarded to be homologous to the extensor plicae alaris

## CHONDRO EPITROCHLEARIS MUSCLE - RIGHT SIDE (COURSE &amp; INSERTION)

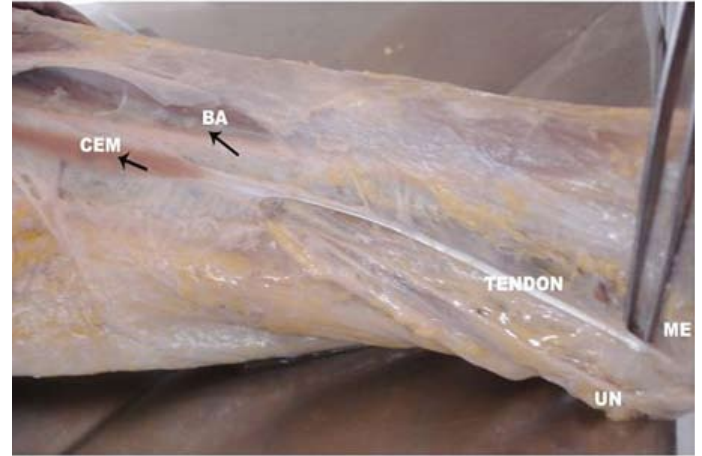


CEM - CHONDRO EPITROCHLEARIS MUSCLE  
UN - ULNAR NERVE

BA - BRACHIAL ARTERY  
ME - MEDIAL EPICONDYLE

[Table/Fig 5]: Chondroepitrochlearis muscle- Right side (Course & Insertion)

## CHONDRO EPITROCHLEARIS MUSCLE - LEFT SIDE (COURSE &amp; INSERTION)

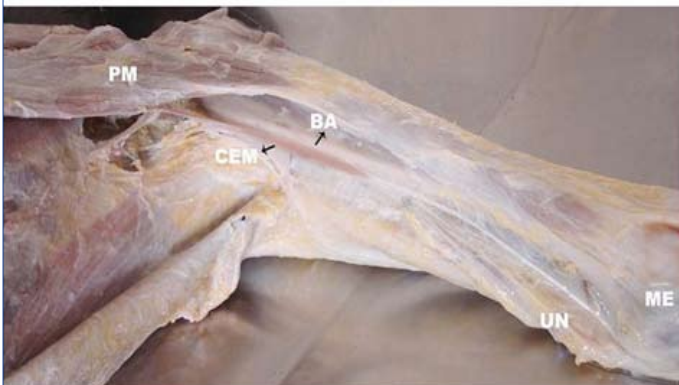

CEM - CHONDRO EPITROCHLEARIS MUSCLE  
UN - ULNAR NERVE

BA - BRACHIAL ARTERY  
ME - MEDIAL EPICONDYLE

[Table/Fig 7]: Chondroepitrochlearis muscle- Left side (Course & Insertion)

## CHONDRO EPITROCHLEARIS MUSCLE - LEFT SIDE



PM - PECTORALIS MAJOR BA - BRACHIAL ARTERY  
CEM - CHONDRO EPITROCHLEARIS MUSCLE  
UN - ULNAR NERVE ME - MEDIAL EPICONDYLE

[Table/Fig 6]: Chondroepitrochlearis muscle- Left side

in birds, thus tightening the skin extending from the humerus to the carpal joint. (Perrin 1871). The extensor plicae alaris is now termed as the tenores patagii longus and the brevis in birds (Fischer, 1946). But, the patagii muscles are derived from the dorsal muscle mass and are innervated by the posterior division of the brachial plexus. An anomalous chondroepitrochlearis muscle, having two heads, one ventral and one dorsal, was reported by Nakajima et. al in 1999 [11]. The pectoral nerve first innervated the ventral head and then, the greater part of the dorsal head. The intercostobrachial nerve (Th2) innervated a small part of the dorsal head. Hence, judging from the muscular origin, the insertion and the innervation,

the ventral head was considered to be the chondroepitrochlearis muscle, whereas the dorsal head was an aberrant type of the muscular arch of the axilla. According to the above observation, the relationship of the chondroepitrochlearis to the patagii muscles is of no relevance.

The absence of the normal twisting pattern denotes that the chondroepitrochlearis is an atavistic anomaly. In quadrupeds,

the pectoralis minor muscle has an insertion in the upper end of the shaft of the humerus. In humans, while the insertion of the pectoralis minor shifted to the coracoid process, the lower fibres of the pectoralis major moved up in the lateral lip of the intertubercular sulcus. The absence of the twisted insertion of the pectoralis major is the result of the presence of the chondroepitrochlearis muscle slip. This muscle slip which is formed from the lower fibres of the pectoralis major gets inserted into the normal insertion site at the lower end of the humerus, as it is the case in the quadrupeds. Hence, the lower fibres are compelled to insert without the twist, in the lower end of the lateral lip of the intertubercular sulcus.

In the present case, the muscle slip is seen to be closely related to the ulnar nerve along the medial intermuscular septum [Table/Fig 5, 6]. Every possibility of the compression of the ulnar nerve, either before or immediately after it pierces the medial intermuscular septum, exists. Spinner RJ et .al [12] have reported the first ever known neurological complication due to the crossing of the chondroepitrochlearis muscle over the neurovascular bundle of the arm. Di Gennaro GL et al[13] have reported a case of an 11-year-old boy who was affected bilaterally, who underwent surgical treatment to lengthen the chondroepitrochlearis muscle. There was a significant cosmetic and functional improvement. Samuel et.al [14] reported an added problem of the limitation of the abduction of the humerus because of the presence of the chondroepitrochlearis muscle.

Ulnar nerve entrapment is the second most frequent entrapment neuropathy in the upper extremity. Pressure or injury to the ulnar nerve along its anatomic course may cause denervation and the loss of the intrinsic muscle function in the hand. Because of the anatomical arrangement of the structures, the area around the elbow is the most common area for the entrapment. In the above elbow causes, the arcade of Struthers (a musculofascial band, about 8 cm proximal to the medial epicondyle), the medial intermuscular septum (which the nerve pierces to reach the olecranon groove), and the medial head of the triceps muscle (which can be hypertrophied or can chronically snap over the medial epicondyle, thus causing a neuritis) are the common reasons [15]. The chondroepitrochlearis muscle also comes under the above elbow cause of the ulnar nerve entrapment syndrome. Depending on the level and the severity of the ulnar nerve compression, the signs and symptoms may vary from mild transient paraesthesiae in the ring and small fingers to the clawing of these digits and severe intrinsic muscle atrophy [16],[17].

Landry (1958) [18] concluded that chondroepitrochlearis is an atavistic anomaly which demonstrates the distal extent of the insertion in ancestral forms. The chondroepitrochlearis muscle has been found at autopsy in infants with chromosomal defects, namely, trisomy 13 with a D)D translocation (Aziz, 1980) [19] and trisomy 18 (Bersu and Ramirez-Castro, 1977) [20]. Barash et al. (1970) [21] postulated that the genetic code for such atavistic muscles is normally repressed during embryogenesis and that trisomy 18 causes the derepression of these genetic loci.

## CONCLUSIONS

This article delineates a bilateral example of the rare supernumerary muscle, the chondroepitrochlearis. It is usually associated with an axillary arch muscle, which was not observed in the present study. The normally twisted insertion of the pectoralis major was also not present. This anomaly has attracted clinical attention because of its potential to cause cosmetic defects, to restrict the abduction of the arm, and to cause ulnar nerve entrapment. Thus, it may be of particular interest to plastic surgeons, orthopaedic surgeons, and neurologists.

## REFERENCES

- [1] BONASTRE V, RODRIGUEZ-NIEDENFUHR M, CHOI D, SANUDO JR Coexistence of a pectoralis quartus muscle and an unusual axillary arch: case report and review. 2002, 15: 366–370.
- [2] STANDRING S, ELLIS H, HEALY C, JOHNSON D, WILLIAMS A Editors Grays anatomy. 39th ed. Elsevier Churchill Livingstone, 2002 p.834.
- [3] MOSCONI T, KAMATH S. Bilateral asymmetric deficiency of the pectoralis major muscle Clin Anat., 2003 16: 346–349.
- [4] LOUKAS M, BOWERS M, HULLETT J Sternalis muscle: a mystery still. Folia Morphol, 2004 a. 63: 147–149.
- [5] O'NEILL MN, FOLAN-CURRAN J Case report: bilateral sternalis muscles with a bilateral pectoralis major anomaly. J Anat, 1998 193: 289–292.
- [6] BONASTRE V, RODRIGUEZ-NIEDENFUHR M, CHOI D, SANUDO JR Coexistence of a pectoralis quartus muscle and an unusual axillary arch: case report and review. 2002 Clin Anat, 15: 366–370.
- [7] CHIBA S, SUZUKI T, KASAI T. A rare anomaly of the pectoralis major--the chondroepitrochlearis Okajimas Folia Anat Jpn. 1983 ;60(2-3):175-85
- [8] G. FLAHERTY, M. N. O'NEILL, AND J. FOLAN-CURRAN. Case report: bilateral occurrence of a chondroepitrochlearis muscle J Anat. 1999; 194 (Pt 2): 313–315.

## BOOK

- [9] SWEENEY LJ Basic concepts in embryology. McGraw-Hill, 1998 pp. 136–138.

## PERIODICALS

- [10] CARLSON BM Human embryology and developmental biology. Mosby, 2004 pp. 224–225.
- [11] NAKAJIMA K, CHIBA S, KOBAYASHI K, WAKATUKI E, KUMAKI K, HOSHINO T KAIBOGAKU ZASSHI A rare muscular anomaly in the upper arm--the chondroepitrochlearis muscle with an aberrant type of the muscular arch of axilla. Journal of anatomy. 1999 Apr; 74(2):209-13.
- [12] SPINNER RJ, CARMICHAEL SW, SPINNER M. Infraclavicular ulnar nerve entrapment due to a chondroepitrochlearis muscle. J Hand Surg [Br]. 1991 Aug;16(3):315-7.
- [13] DI GENNARO GL, SONCINI G, ANDRISANO A, VALDISERRI L. The chondroepitrochlearis muscle: case report. Chir Organi Mov. 1998 Oct-Dec;83(4):419-23.
- [14] SAMUEL, VIJAYA PAUL • VOLLALA, VENKATA RAMAN, Unusual pectoralis major muscle: The chondroepitrochlearis, Anatomical science international / Japanese Association of Anatomists 2008 Volume 83 Issue 4, Pages 277 - 279
- [15] OSNER MA. Compressive ulnar neuropathies at the elbow: I. Etiology and diagnosis. J Am Acad Orthop Surg. 1998; 6(5):282-8.
- [16] ZIMMERMAN NB, KAYE MB, WILGIS EF, ZIMMERMAN RM, DUBIN NH. Are standardized patient self-reporting instruments applicable to the evaluation of ulnar neuropathy at the elbow. J Shoulder Elbow Surg. 2009;18(3):463-8.
- [17] DUNSELMAN HH, VISSER LH. The clinical, electrophysiologic and prognostic heterogeneity of ulnar neuropathy at the elbow. J Neurol Neurosurg Psychiatry. 2008 79(12):1364-7.
- [18] LANDRY SO The phylogentic significance of the chondroepitrochlearis muscle and its accompanying pectoral abnormalities. Journal of Anatomy 1958; 92:57-64.
- [19] AZIZ MA Anatomical defects in a case of trisomy 13 with a D)D translocation. Teratology 1980; 22:217- 227.
- [20] BERSU ET, RAMIREZ-CASTRO JL Anatomical analysis of the developmental defect of aneuploidy in man ± the 18-trisomy syndrome: I. Anomalies of the head and neck. American Journal of Medical Genetics 1977; 1: 173-193.
- [21] BARASH BA, FREEDMAN L, OPITZ JM Anatomical studies in the 18-trisomy syndrome. Birth Defects, Original Article Series, 1970;V1(4): 3-15.
- [22] LEVENT SARIKCIOGLU , FATOS BELGIN YILDIRIM , SHOJI CHIBA Unilateral occurrence of a chondroepitrochlearis muscle Clinical Anatomy 2004; 17(3): 272-5.
- [23] P JAJJESH, Unilateral appearance of Chondroepitrochlearis muscle – A case report. Indian J Plast Surg July- December 2005 Vol 38 Issue 2.

## AUTHORS:

1. Dr. S Aruna: M.S., Professor and Head of the department, Department of Anatomy, Chettinad Hospital & Research Institute, IT Highway, Kelambakkam, Kanchipuram District, Tamil Nadu – 603103, India.
2. Dr. R Hannah Sugirthabai Rajila: M.S., Assistant Professor, Department of Anatomy, Chettinad Hospital & Research Institute, IT Highway, Kelambakkam, Kanchipuram District, Tamil Nadu.
3. Dr. Vaithianathan G: M.Sc, Assistant Professor, Department of Anatomy, Chettinad Hospital & Research Institute, IT Highway, Kelambakkam, Kanchipuram District, Tamil Nadu – 603103, India.

## NAME, ADDRESS, TELEPHONE, E-MAIL ID OF THE CORRESPONDING AUTHOR:

Dr. S Aruna, Assistant Professor, Department of Anatomy, Chettinad Hospital & Research Institute, IT Highway, Kelambakkam, Kanchipuram District, Tamil Nadu – 603103, India. Email- ashrajsanada@gmail.com, Phone- 9791178269

**DECLARATION ON COMPETING INTERESTS:** No competing Interests.

Date of Submission: **15/12/2010**  
Peer Review Completion: **12/01/2011**  
Date of Acceptance: **20/01/2011**  
Date of Publication: **06/02/2011**