

# A Morphometric Anatomical Study Of The Ethmoidal Foramina On Dry Human Skulls

Ashwini Mutalik, Sanjeev Kolagi, Chandrashekhar Hanji, Mahesh Ugale, G B Rairam

## ABSTRACT

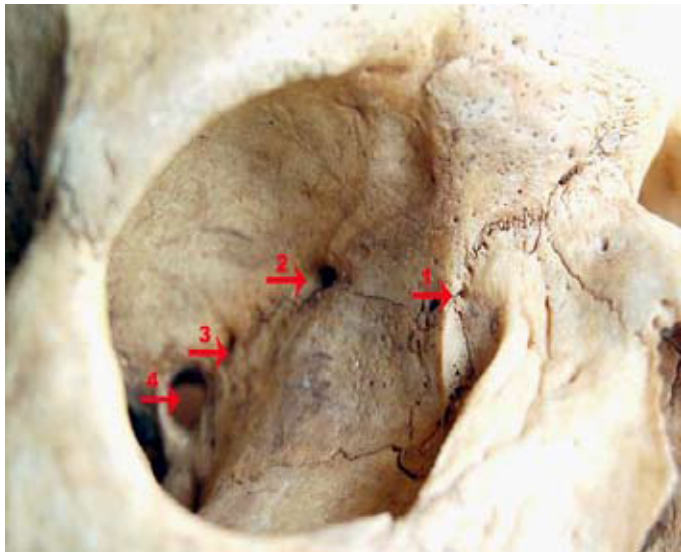
Study of ethmoidal foramina are important in orbital surgeries, surgeries of anterior cranial fossa and in endonasal micro surgeries of ethmoidal region. The present study was undertaken to provide anatomical morphometric data which will guide

surgeons in locating these foramina during different surgeries. We measured the distances between all the ethmoidal foramina and the optic canal from the frontomaxillary suture. We also noted the number, location and presence or absence of these foramina.

**Key Words:** Anatomy, Human, Ethmoid, Foramina

## INTRODUCTION

The medial orbital wall is surgically very important as it is very thin and as it separates the contents of the orbit from the ethmoidal labyrinth. On this wall, the anterior and the posterior ethmoidal foramina are located along the fronto ethmoidal sutures and so also, more posteriorly, the optic canal [Table/Fig 1]. These foramina are important in orbital surgeries, in surgeries of the anterior cranial fossa and in endonasal micro surgeries in the ethmoidal region.



**[Table/Fig 1]:** Normal ethmoidal foramina fronto maxillary suture.

Key to photos:

1. Fronto maxillary suture.
2. Anterior ethmoidal foramen.
3. Posterior ethmoidal foramen.
4. Optic canal
5. Middle ethmoidal foramen.
6. Extra foramen.

The anterior and the posterior ethmoidal arteries are important anatomical structures which have to be recognised during endoscopic sinus surgery [1]. The anterior ethmoidal artery, a branch of the ophthalmic artery, leaves the orbit via the anterior ethmoidal foramen, crosses the roof of the anterior ethmoidal sinus, and supplies the anterior ethmoidal cells and the frontal sinus. The

artery then enters the anterior cranial fossa, gives off the meningeal branches and turns downward into the nasal cavity through slit like apertures at the side of the crista galli. The anterior ethmoidal artery supplies the anterior one third of the lateral wall of the nasal cavity and a similar portion of the nasal septum [2].

The posterior ethmoidal artery, a branch of the ophthalmic artery, takes a similar course along the roof of the posterior ethmoid and it enters the nasal cavity through the cribriform plate. It is normally much smaller than the anterior ethmoidal artery. The posterior ethmoidal artery supplies the posterosuperior portion of the lateral nasal wall and a corresponding portion of the nasal septum [3].

The ethmoidal vessels and the nerves pass through these foramina and the study of these foramina can guide us to expose and ligate the vessels during haemorrhages or in preventing / treating the anterior ethmoidal nerve syndrome and also in cases of optic nerve decompression.

The present study was undertaken as not much literature is available on the study of the ethmoidal foramina, particularly in the Indian population.

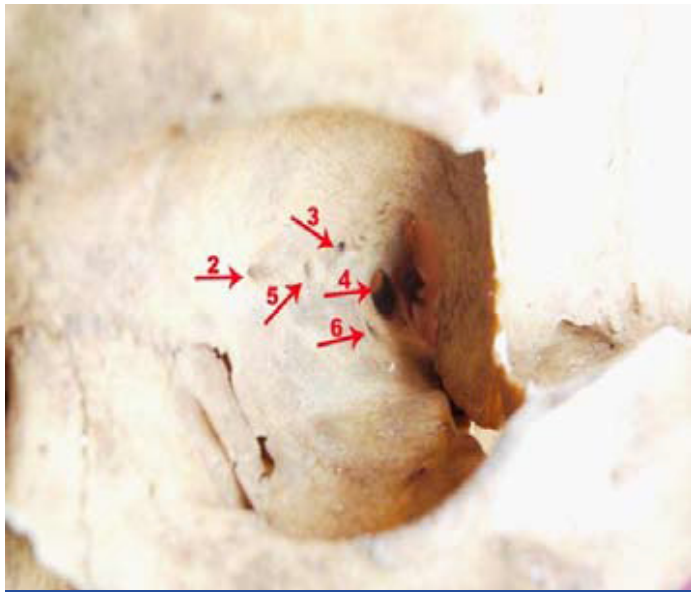## MATERIALS AND METHODS

This study was carried out at S. N. Medical College, Bagalkot, on 100 dry human skulls which were collected from the Department of Anatomy. The location, number, presence or absence of the ethmoidal foramina and also the optic foramen, were observed on both the sides. The following measurements were done with the help of a compass, scale, calipers and magnifying glass.

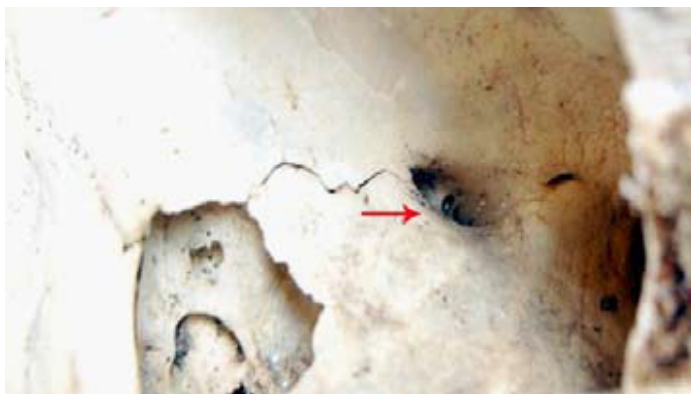The distances between the frontomaxillary sutures and the optic canals were measured. Then, the distance between the frontomaxillary sutures and the ethmoidal foramina were measured and the rest of the parameters were calculated.

We calculated the distance between the middle ethmoidal foramen and the posterior ethmoidal foramen by subtracting the distance between the frontomaxillary sutures to the middle ethmoidal foramen from the frontomaxillary sutures to the posterior ethmoidal foramen. Similarly, the distance between the posterior ethmoidal foramen and the optic canal was measured by subtracting the distance between the frontomaxillary sutures to the posterior ethmoidal foramen from the frontomaxillary suture to the optic canal. When the

middle ethmoidal foramen and the posterior ethmoidal foramen were absent, we measured the distance between the anterior ethmoidal foramen to the optic canal by subtracting the distance between the frontomaxillary sutures to the anterior ethmoidal foramen from the frontomaxillary suture to the optic canal [Table/Fig 2].



[Table/Fig-2]: Middle ethmoidal foramen and extra foramen.



[Table/Fig-3]: MEF divided in to two parts.

- |    |                                    |                             |  |
|----|------------------------------------|-----------------------------|--|
| 1. | Distance between Posterior edge of | FMS-AEF<br>MEF<br>PEF<br>OC | FMS-Frontomaxillary sutures<br>AEF-Anterior Ethmoidal Foramen<br>MEF-Middle Ethmoidal Foramen<br>PEF-Posterior Ethmoidal Foramen<br>OC-Optical Canal |
| 2. | Distance between                   | AEF-MEF<br>PEF<br>OC        | OC-Optical Canal<br>EF-Extra Foramen   |
| 3. | Distance between                   | MEF-PEF<br>OC and           |  |
| 4. | Distance between                   | PEF-OC                      |  |

(We also noted an extra foramen below the optic foramen in few skulls).

## RESULTS

All the 100 skulls had the anterior ethmoidal foramina. The middle ethmoidal foramen was observed on the right side in 35 skulls and on the left side in 41 skulls. The posterior ethmoidal foramina were present in 98 skulls, both on the right and the left sides. We noted 20- 22 extra foramina below the optic canal on the right and left sides respectively. The presence of only the AEF was found in 2 skulls on the right and left sides. On the right side, the MEF was divided into two parts in 1 skull.

After the detailed study of the measurements from the FMS to the different ethmoidal foramina and also to the OC, the average distance between the FMS and the OC was found to be 39.91mm and 40.35mm on the right and left sides respectively and the average distance between the FMS to the AEF was 21mm and 21.7mm on the right and left sides respectively. The average distance between the AEF to the MEF on the right and left sides was 7.24mm and 7.65mm, and that of the MEF to the PEF was 4.74mm and 4.5mm on right and left sides of the skull. The maximum distance between the AEF and the PEF was 18 and 17mm and the maximum distance between the PEF to the OC was 14 and 18mm on the right and left sides respectively. The average distance between the AEF to the OC was 19 and 20mm on the right and left sides respectively.

In our study, the distance between the AEF to the FMS ranged between 14-32 mm, that between the AEF to the PEF ranged between 3-18 mm and that between the PEF to the OC ranged between 2-18 mm [Table/Fig 4-6].

	FM-OC		FM-AEF		AEF-MEF		MEF-PEF		AEF-PEF		PEF-OC		AEF-OC	
	R	L	R	L	R	L	R	L	R	L	R	L	R	L
Min	34	33	15	14	2	2	2	1	6	3	2	2	14	15
Max	46	50	31	32	12	14	9	12	18	17	14	18	24	25
Avg	39.91	40.35	21	21.17	7.24	7.65	4.74	4.5	12.3	12	6.95	6.57	19	20

[Table/Fig 4]: The distances measured on medial wall of orbit in mm

[R-Right Side; L- Left Side]

AEF		MEF		PEF		EF	
R	L	R	L	R	L	R	L
2	2	35	41	98	98	20	22

[Table/Fig 5]: Prevalence of Foramina

[R-Right Side; L- Left Side]

	FMS-AEF	AEF-PEF	PEF-OC
R Average	21	12.3	6.95
L	21.7	12	6.97
Range	14-32	3-18	2-18

[Table/Fig 6]: Locations of foramina on medial wall of orbit ( in mm)

[R-Right Side; L- Left Side]

## DISCUSSION

The anterior and the posterior ethmoidal nerves are the branches of the nasociliary nerve which pass through the respective foramina and supply the mucosa of the nasal cavity [4], while the anterior and the posterior ethmoidal arteries are the branches of the ophthalmic artery which supply the anterior, middle and the posterior ethmoidal sinuses along with the lateral wall of the nose and the nasal septum [5].

The position and the number of these foramina are variable, but a ratio of 24-12-6mm has been suggested, based respectively on the average distance from the anterior lacrimal crest to the AEF, from the AEF to the PEF and from the PEF to the OC [6].

In a study which was conducted by Kirchner JA (1961), the distance between the AEF and the PEF was found to be approximately 10mm, while the distance between the PEF to the optic canal was between 4 to 7 mm in 84% of the skulls which were studied [7].

In a study which was done by Shin HM (2006) on cadavers, it was concluded that the distance from the posterior lacrimal crest to the AEF was  $16.10 \pm 1.07$ mm, from the posterior lacrimal crest to the PEF, it was  $30.35 \pm 4.08$  and from the posterior lacrimal crest

to the optic canal, it was  $37.4 \pm 2.03$  mm. The distance was  $13.95 \pm 1.06$  mm between the AEF and the PEF and it was  $6.45 \pm 1.86$  mm between the PEF and the optic foramen [8].

In one of the studies done by P. Karakas (2002) on 62 orbits of the male skull, the midpoint of the anterior lacrimal crest was taken as the reference point. From this point, the distance was measured to the AEF, the PEF, the midpoint of the optic foramen and the posterior lacrimal crest, which were 23.9-3.3mm, 35.6-2.3mm, 41.7-3.1 mm and 6.9-1.5 mm respectively [9].

A study was carried out on 20 dry human skulls by P.R. Singh and it was observed that all the skulls had AEF and that in 2% of the skulls, the AEF was present on only one side. The PEF was present bilaterally in all the skulls and in 19% of the skulls, the PEF was multiple [10].

In a study which was done by Mc Donald SE (2008) on routine coronal sinus CT scans, it was observed that the AEF was present in 95% of the cases bilaterally and that it was present unilaterally in the remaining 5% of the cases. This study also measured the distance between the lacrimal crest to the AEF, which was 22.4mm [11].

## CONCLUSION

Morphometric anatomical studies on the ethmoidal foramina are few in number. Our study on dry bones provides anatomical

morphometric data which will guide surgeons in locating these foramina during surgeries of the orbit, the anterior cranial fossa and the ethmoidal region and also in endonasal microsurgies.

## REFERENCES

- [1] Stammberger H. Functional Endoscopic Sinus Surgery. The Messerklinger Technique. Philadelphia: B.C. Decker, 1991:70-4.
- [2] Ohnishi T, Yanagisawa E. Endoscopic anatomy of the anterior ethmoidal artery. Ear Nose Throat J. 1994;73:634-6.
- [3] Hollinshead WH. Anatomy for Surgeons. 2nd ed. Vol.1. New York: Harper and Row, 1968:467-560.
- [4] Ranganathan T.S. Text Book of Human Anatomy. 5th Edition; New Delhi: S. Chanda and company Ltd., 1993: 542.
- [5] Dutta AK. Essentials of Human Anatomy (Head & Neck) Part II, 3rd Edition, Calcutta: Current books international, 1999: 255.
- [6] Kerr AG. Scott Browns otolaryngology, Basic Sciences, 6th edition, Vol 1, Oxford: Butterworth Heinemann, 1997: 26.
- [7] Kirchner JA, Yanagisawa E, Crelin ES. Surgical anatomy of the ethmoidal arteries- A laboratory study of 150 orbits. Arch Otolaryngol. 1961;74:382-6.
- [8] Shin HM, Lew H, Yun YS. Anatomical Study of Medial Orbit in Human Cadavers. J Korean Ophthalmol Soc. 2006; 47(7): 1093-1099.
- [9] Karakas P, Bozkar MG, Oguz O. Morphometric measurements from various reference points in the orbit of male Caucasians. Surg Radiol Anat. 2002; 24: 358-362.
- [10] Singh PR, Ananda MK, Raibagkar CJ. Study of ethmoidal foramen in dry human skull: Journal of Anatomical Society of India. 2005; 54(1): 32.
- [11] Mc Donald SE, Robinson PJ, Nunez DA. Radiological anatomy of the anterior ethmoidal artery for functional endoscopic sinus surgery. J Laryngol Otol. 2008; 122(3): 264-7.

### AUTHORS:

1. Dr. Ashwini Mutalik
2. Dr. Sanjeev Kolagi
3. Dr. Chandrashekhar Hanji
4. Dr. Mahesh Ugale
5. Dr. G B Rairam

### NAME OF DEPARTMENT(S)/INSTITUTION(S) TO WHICH THE WORK IS ATTRIBUTED:

Department of Anatomy S.N. Medical College & HSK Hospital, and Research center, Bagalkot

### NAME, ADDRESS, TELEPHONE, E-MAIL ID OF THE CORRESPONDING AUTHOR:

Dr. Ashwini Mutalik, Asst. Professor, Dept of Anatomy, S.N. Medical College & HSK Hospital, Navanagar

Bagalkot-587103, Karnataka State, INDIA  
Tel (Office): 08354-235400 # 1154 (with STD code)  
Tel (Residence): 08354- 220434 (with STD code)  
E-mail address: ashwinimutalik@rediffmail.com  
Mobile Number: +919900130146

**DECLARATION ON COMPETING INTERESTS:** No competing Interests.

Date of Submission: 27/11/2010  
Date of Peer Review Completion: 27/12/2010  
Date of Acceptance: 10/01/2011  
Date of Publish: 06/02/2011