

The atypical presentation of Multicystic Dysplastic Kidney In Nigerian Adults: Two Case Reports

AREMU A ADEGOKE, OSIATUMA VICTOR A, OLAJIDE ABIMBOLA,
ASALEYE C M, FAMUREWA O C, ADEILOYE VICTOR A

ABSTRACT

Multicystic dysplastic kidney, an uncommon congenital cystic renal disease, is often diagnosed by prenatal ultrasound in the third trimester of pregnancy or in infancy when it commonly presents as an abdominal mass. The typical presentation in childhood is hypertension and/or abdominal mass. However, to the best of our knowledge, the presentation as an abdominal mass in adulthood has not been previously reported, since the renal mass characteristically regresses and is not detectable by age five. Also, the only two cases of this rare condition which were seen in our centre in the past five years, were not found in fetuses or infants, but were rather found in adults and they presented with abdominal masses rather than the common adulthood presentation of abdominal pain and/or hypertension. The imaging features were also not characteristic of multicystic dysplastic kidney.

Both patients were Nigerian females of the Yoruba tribe, from the Southwestern part of Nigeria, with ages fifty-five and twenty-four and they presented with abdominal masses. Also, the imaging features were not characteristic of multicystic dysplastic kidney; though they had cystic renal masses, the cysts were communicating. The diagnosis was eventually made on the basis of histology after nephrectomy.

Multicystic dysplastic kidney should be considered as one of the differential diagnoses of renal /abdominal masses in adults. Also, all communicating centrally located renal cysts are not dilated calyces. These facts should be noted by urologists and radiologists.

Key Words: Multicystic Dysplastic Kidney In Nigerian Adults

INTRODUCTION

Multicystic dysplastic kidney (MCDK) is a non genetic, congenital, cystic renal disease in which the cortex is replaced by numerous cysts of multiple sizes. The term multicystic and polycystic were used interchangeably before until 1955, when Spence stressed that the terms were different entities.

MCDK is typically a unilateral disorder, since the bilateral condition is not compatible with extra-uterine life. Although MCDK is unilateral, the contralateral kidney has an increased incidence of congenital anomalies which may be mild or as severe as renal agenesis, which is also not compatible with life. It has an incidence of 1 in 4,300 (for unilateral MCDK) and 1 in 10,000 (for bilateral MCKD) live births and a male to female ratio of 2:1 (for unilateral MCKD). It presents as an abdominal mass in neonates and infants, if not diagnosed by prenatal ultrasound and reported to regress and become undetectable even by imaging by five years of age. The two cases of Multicystic dysplastic kidneys which were seen at our centre in five years, were not children, but adults with an unusual presentation. We hereby discuss these cases and review the relevant literature.

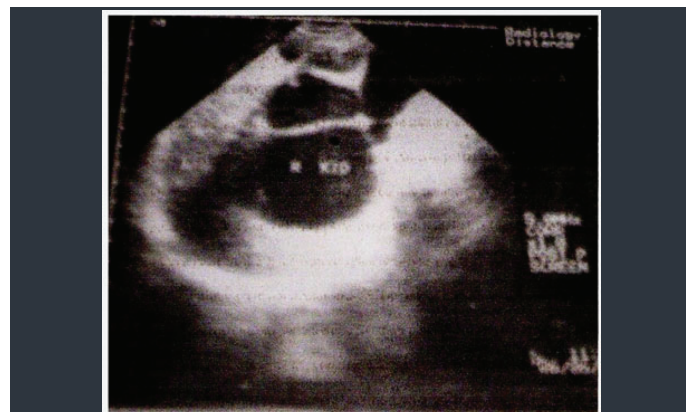
CASE REPORT A

Case A was a 55yr old female teacher who was referred from a secondary health care centre to a urologist with a 15 years history of recurrent, severe, dull ache in the right loin and a 4 months history of progressive right sided abdominal swelling. There was no history of haematuria or facial or pedal swelling, no change in urinary flow and no history of jaundice or haematochezia. There was a positive history of weight loss. Physical examination revealed a middle aged woman, afebrile, not pale, anicteric, well hydrated and with no pedal oedema.

However, there was a persistent elevation of blood pressure which varied between 170/110 and 190/140mmHg. The central nervous

and the pulmonary systems were normal. Abdominal examination revealed a firm, ballotable, non tender, slightly mobile, right lumbar mass with well defined edges. The percussion over the mass was resonant. An initial clinical diagnosis of right renal tumour with secondary hypertension was made. The full blood count, platelet count, estimation of electrolytes and urea with creatinine, chest radiograph, urinalysis, echocardiography and liver function tests were all within normal limits.

The abdominal ultrasound [Table/Fig 1] revealed a markedly enlarged, non calcified, right kidney measuring 16.0x7.2cm in the bipolar and the anteroposterior diameters, which was filled with moderately to markedly dilated communicating cystic lesions with no definite parenchymal tissue. The liver, spleen, and left kidney were normal. No cysts were seen in the liver, spleen, pancreas and the left kidney. However, the renal pelvis and the ureter were not demonstrable. There was no ascites. [Table/Fig 1]

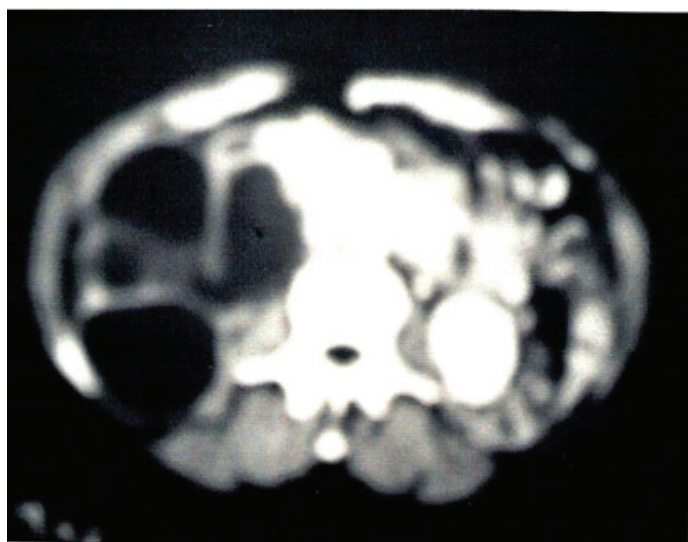


[Table/Fig 1]: Abdominal ultrasound showing dilated communicating cysts in the right kidney

A diagnosis of severe hydronephrosis, secondary to pelviureteric junction obstruction, was made.

The preliminary film of an intravenous urography which was done revealed a soft tissue mass in the right lumbar region. However, there was no excretion from the right kidney after 48 hours, while the left kidney, the left ureter and the urinary bladder were within normal limits.

An enhanced abdominal CT was done [Table/Fig 2]; the scanogram showed a right cystic lumbar mass with no evidence of calcification. Serial axial cuts revealed normal liver, spleen, pancreas and left kidney. A ring calcification due to atherosclerosis from hypertension and aging was seen in the abdominal aorta. [Table/Fig 2]



[Table/Fig 2]: Enhanced Abdominal computerized axial tomography (CT) showing communicating right renal cysts; the left kidney is normal

The serial axial cuts and the sagittal and the coronal reformats revealed multiple, dilated, non-enhancing, communicating, cystic, right kidney masses, with no renal parenchyma seen. The right ureter and the pelvis were not demonstrated. There was no calcification within the mass. The left ureter and the urinary bladder were normal.

The diagnosis which was then made, still was of hydronephrotic right kidney, with a differential diagnosis of multicystic kidney disease.

Urethrocystoscopy revealed normal urethra and bladder mucosa. The left ureteric orifice was observed and was found to be normal, while the right ureteric orifice was not seen or cannulated. She was placed on antihypertensives to control the blood pressure and was prepared for laparotomy.

The operative findings included: a cystic, right kidney mass measuring 14x10x6cm, with absent right ureter and friable right adrenal; a hypertrophied left kidney with normal texture and consistency; other abdominal organs were normal. The right renal mass was completely removed and was sent for histology.

The post operative period was uneventful and the PCV before discharge was 34%; the average blood pressure (without antihypertensives) was 140/90mmHg. She was discharged on the 7th day, post operation. The histology reports confirmed a diagnosis of multicystic dysplastic kidney.

CASE REPORT B

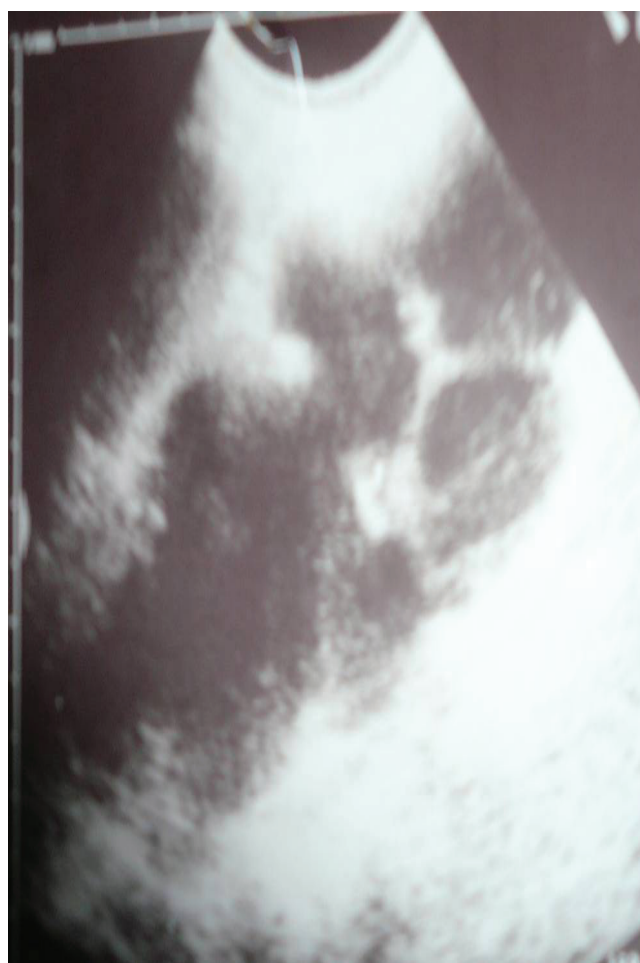Case B was a 24 year old polytechnic student who was referred to the Obafemi Awolowo University Teaching Hospitals' complex from a private hospital on account of septicaemia. Her presenting

complaints were a left sided abdominal mass of two years' duration, which became painful two weeks before presentation, with associated fever. There was a history of nausea but no vomiting. There was no history of haematuria, jaundice, facial or pedal swelling; nor was there any change in urine flow or weight loss. She had to be referred to the teaching hospital because she was not responding to the treatment.

On examination, she was found to be a young lady who was acutely ill-looking, pale, anicteric, febrile, and dehydrated, but was not in any obvious distress. Her blood pressure was 120/80 mmHg and her pulse rate was 90beats/min. Her abdominal examination revealed a firm, ballotable, tender, mobile, left lumbar mass with well defined margins. The other systems which were reviewed were essentially normal.

A provisional diagnosis of an abdominal mass was made and laboratory investigations and abdominal ultrasound were requested. The PCV was 24%, with a raised WBC count. The platelet count, electrolytes, urea, creatinine and urinalysis were all normal.

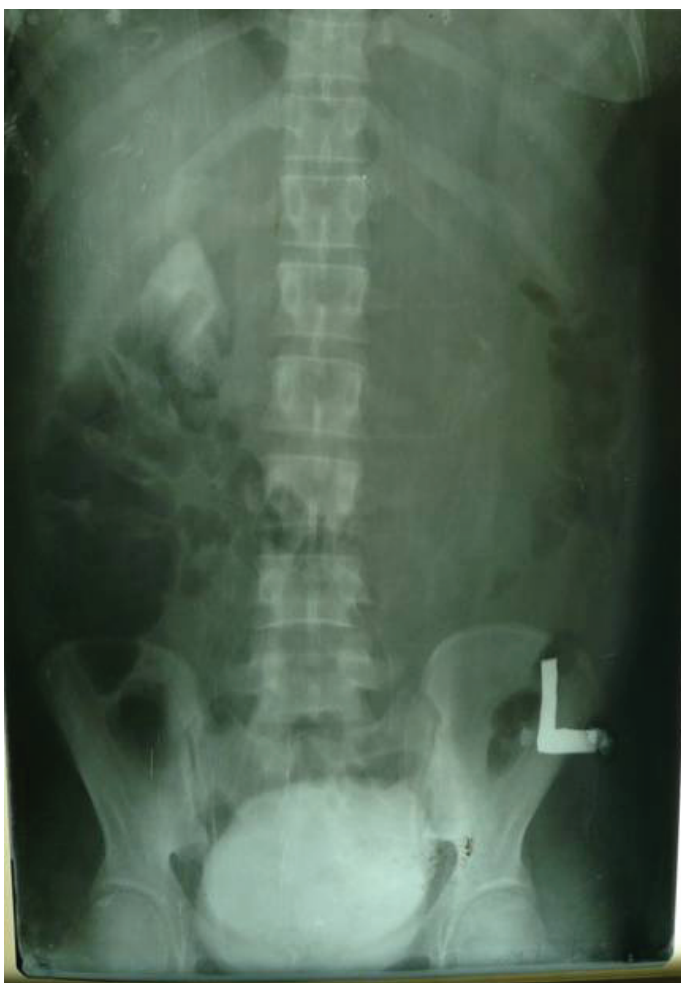Abdominal ultrasound [Table/Fig 3] revealed an enlarged, non calcified, left kidney measuring 16cm x 7cm in its bipolar and antero-posterior diameters, with multiple communicating cysts of varying sizes. No normal renal parenchyma tissue was seen. The renal pelvis and the ureter were not visualized. In addition, the numerous cysts contained fine internal echoes. The liver, gallbladder, pancreas, spleen and the right kidney were normal. There was no ascites. A diagnosis of cystic renal mass with infection or bleeding into the cyst was made. [Table/Fig 3]



[Table/Fig 3]: Abdominal ultrasound

An emergency intravenous urography was ordered for to ascertain the functional state of the kidneys. The plain film revealed a soft tissue density mass in the left lumbar region, which displaced the bowel loops to the right. No calcification was seen. Contrast films

showed no excretion from the left kidney after 48 hours, while the right renal outline was faintly demonstrated because of poor bowel preparation. The right renal pelvis was baggy and extrarenal. [Table/Fig 4].



[Table/Fig 4]: Intravenous urography

The right ureter was normal, while the left ureter was not visualized. The urinary bladder was within normal limits.

Emergency surgery (laparotomy) was done. At surgery, an enlarged left kidney was found, which contained multiple cysts which were filled with pus. The left ureter was atretic. A total of 550ml of pus was drained before the left nephrectomy was done. The specimen was sent for histology.

The patient was transfused with two pints of blood before discharge on the 7th post-operation day.

Histopathological tests confirmed a diagnosis of multicystic dysplastic kidney.

DISCUSSION

Multicystic dysplastic kidney (MCDK) is a non genetic, congenital, cystic renal disease in which the cortex is replaced by numerous cysts of multiple sizes. The terms 'multicystic' and 'polycystic' were used interchangeably until 1955, when Spence stressed that the two terms were different entities [1].

The cysts were anchored by the dysplastic parenchymal and the arrangement was said to resemble a bunch of grapes; with the calyceal drainage system often absent.

MCDK is typically a unilateral disorder; the bilateral condition is not compatible with extrauterine survival. Furthermore, the appearance

of MCDK with contralateral renal agenesis does not support life. The two patients had unilateral MCDK with normal contralateral kidneys.

The renal size (in MCDK) varies from slightly less than normal to enormous, filling most of the abdomen; the cysts may even be small (microscopic) with predominating stroma – this condition is referred to as solid cystic dysplasia. The hydronephrotic form of multicystic kidney is diagnosed when an identifiable renal pelvis is seen in association with what appears to be a multicystic kidney. The renal pelvis was not identified in any of the imaging modalities which were used to assess these patients.

Competing theories for the aetiology of MCDK have been proposed. Felsen and Gussen (1975) suggested that multicystic kidney is an extreme form of hydronephrosis which is secondary to atresia of the ureter or the renal pelvis. The fact that the left kidney is more often affected, supports this view, because the kidney is often associated with the primary obstructive megaureter and ureteropelvic junction obstruction [2]; only one of our cases had a left sided lesion.

This hypothesis was confirmed in some animals by ligating the ureter at various points of gestation. Although it is found to be effective when the ligation took place in the first trimester, it however induced dysplasia and not multicystic dysplastic kidney.

Congenital renal dysplasia may also be explained by an abnormal induction of the metanephric blastema by the migrating ureteric bud. Disruption in this molecular interaction can produce congenital anomalies which are similar to MCDK or other forms of renal dysplasia.

One of the most recent explanations is that dysplastic renal tubules are poorly branched derivatives of the ureteric bud that terminate in the cystic bud. It is therefore possible that the mutation of ICAL-1, a transcript that is expressed in the embryonic human central nervous system and the urinary tract, can generate renal dysplasia as well as agenesis [3].

Exposure to teratogens and some genetic mutations have been reported as the causes and are found to be associated with syndromes like Brachio-oto-renal, Renal-coloboma [4], 49XXXX, Alagille and Beckwith Weilderman.

Several forms of MCDK have been described. Both the classic type and the less common hydronephrotic type have cysts of various sizes which are connected by loose, insubstantial fibrous tissues. No functional renal tissue is identifiable. The classic type has a random configuration of cysts, whereas the latter variant presents with a discernible, dilated renal pelvis which is surrounded by cystic structures. The third condition is known as solid cystic dysplasia –made up of small cysts with a greater amount of non functional parenchyma. The discussed cases were not likely to be of the classic type, as no renal pelvis was identified, neither was a solid renal parenchymal seen.

Although the pathogenetic process leading to a multicystic kidney disease begins at the 8th week in utero, the mean age at the time of the antenatal diagnosis is about 28 weeks, with a range of 21 to 35 weeks [5].

In newborns, MCDK remains as one of the commonest causes of an abdominal mass and is also a common cause of a palpable abdominal mass in neonates (second only to hydronephrosis). Other differential diagnoses include ureteropelvic junction obstruction, renal dysplasia secondary to obstructive disorders, hypodysplasia (of a duplex kidney), multilocular cystic nephroma [6] and even infantile onset autosomal recessive polycystic kidney disease, depending on the variants of MCDK.

The three main characteristics of MCDK, namely the presence of multiple, non communicating cysts of varying sizes, the dysplas-

tic renal parenchymal and the absence of a normal pelvicalyceal system, may not always be present because there are three types or variants of MCDK (classic, hydronephrotic, and solid cystic dysplasia) [7].

The non demonstration of the other two characteristic features in our patients is due to the fact that they are most probably of the commonest classic variant, and also because of the non availability of radionuclide (DMSA renal scintigraphy and DTPA diuretic renal scan) as well as Magnetic resonance imaging at our centre. G.T. Rottenberg et al [8] did a retrospective study on sixty six children with a radiological diagnosis of multicystic kidney disease. The change in size which was demonstrated on sonograms was examined. Only fifty children had adequate follow-up over 32 months. It was concluded that multicystic kidney undergoes partial or complete involution over the first two years of life, because 40 out of the 55 kidneys showed reduction in size – these include 22 which were no longer detectable by ultrasound.

The less severely affected patients present in adulthood during the evaluation for abdominal pain, haematuria and hypertension. It rarely presents as an abdominal mass in this age group, but rather, with the incidental finding of one or more curvilinear calcifications in the renal area. Infection and pain are some of the other modes of presentation. This condition is more likely to be found on the left and is slightly more common in males. Our two patients presented with an abdominal mass, with hypertension and infection as complications in cases A and B respectively. There was no calcification.

Although MCDK is often unilateral since the bilateral condition is not compatible with extrauterine survival, the opposite kidney has an increased incidence of congenital anomalies like ureteropelvic junction obstruction or ureteral anomalies in as many as 30-41% of the patients [9].

No anomaly was seen in the contralateral kidney in A, while B had an extrarenal pelvis in the right kidney. Atiyeh B et al found the contralateral abnormalities to be commoner than the unilateral abnormalities and the most common contralateral genitourinary tract anomaly which was found in their study was vesicoureteric reflux, which was seen in 18% of the patients [10].

It is important to diagnose this to prevent acquired renal damage in the solitary functional unit. Reflux may occur in the ipsilateral ureter in a few cases. MCDK can be found in the upper or lower pole of a duplicated kidney, or on one side of a horse- shoe kidney.

Other associated findings in the contralateral kidney, apart from pelvic ureteric junction obstruction, are other obstructive uropathies like uretero vesical junction obstruction, ureteral ectopia, and ureterocoele. Ultrasonography is generally the first study which is performed, especially in neonates and infants. It is fast and accurate and does not require sedation, radiation or other interventions. It is useful for prenatal diagnosis and for post delivery monitoring.

Sonography should also be the first line of study in a symptomatic presentation, such as a palpable abdominal mass, abdominal pain, incontinence and recurrent urinary tract infections. It also provides clues to other urinary tract anomalies, as well as to intra-abdominal or retroperitoneal malignancies.

Classic MCDK appears as multiple, non communicating cysts of varying sizes, which completely replace the parenchymal, as observed by ultrasound. No renal pelvis or calyces are seen. The kidney is markedly enlarged at birth, but may progressively shrink to a small nubbin that commonly calcifies [11],[12].

In the hydronephrotic form, dilated renal pelvis and calyces are identifiable with multiple cysts of varying sizes, replacing most, but not all, of the renal parenchymal. Islands of heterogenous dysplas-

tic solid renal tissue are also seen [13].

Atypical forms of MCDK include a single or few large cysts replacing the kidney. In few cases, it is impossible to differentiate hydronephrosis from MCDK, although if renal pelvis cannot be identified, multicystic dysplasia is the likely diagnosis [14].

Hydronephrosis was the first radiological diagnosis in both patients because of their ages and the communicating cystic renal masses. In these difficult cases, radionuclide imaging may be helpful by showing some function by hydronephrotic kidneys on a DMSA (dimercaptosuccinic acid) scan, whereas renal concentration is seldom seen in multicystic kidney [11],[12],[13].

The radionuclide imaging facility is however not available at our centre and therefore it could not be utilized. Radionuclide imaging is superior to intravenous pyelography in children, in differentiating hydronephrotic kidney from MCDK (especially hydronephrotic form). Apart from DMSA; MAG-3 (technetium 99m mercaptoacetyl triglyceride) will demonstrate a lack of function (MCDK) and also provide information regarding the drainage in an obstructed hydronephrotic kidney.

However, a limitation of radionuclide imaging is the relatively poor renal function in the first month of life; the study is therefore usually postponed until 1 month of age, to avoid false- positive results.

Also, any lesion that impairs renal circulation, such as renal artery stenosis and renal vein thrombosis, will reveal the kidney as non-functioning, on a nuclear renogram.

Angiography will also reveal an absent or small renal artery in the multicystic dysplastic kidney, though it is rarely indicated.

Cystoscopy may reveal a hemitrigone and absent ureteral orifice on the affected side; however, when an orifice is present retrograde ureterography will often demonstrate ureteral atresia. The ureteral orifice was absent on the affected right side in these patients and retrograde catheterization was not possible.

Voiding cystourethrography is also recommended as a routine procedure in children with MCDK, due to a high frequency of lower urinary tract abnormalities. B Karmazyn et al [14], in a study on 59 children, found that 32% of them had one or more abnormalities of the lower urinary tract, which included vesicoureteric reflux, ectopic ureters, ureterocoele, hypospadias, opacification of a small utricle and ejaculatory duct reflux.

Intravenous urography (I.V.U.) may show two or more curvilinear calcifications in the renal area on a plain film. A soft tissue mass in the lumbar region, displacing the bowels, may also be seen. The contrast films may show a non excretory affected kidney. It may also demonstrate coexisting urinary tract anomalies like ectopic ureters, ureterocoele, etc.

Computerized Tomography scan and magnetic resonance imaging are not part of the routine algorithms in the diagnosis of MCDK. CT may however show calcification in the renal region; multicystic mass with little or no parenchyma and non excretion after intravenous contrast administration. Case A had CT, but the masses though cystic, were not calcified.

Magnetic Resonance Imaging (MRI) may show similar findings as those revealed by the computerized tomography scan and may also be able to show the little dysplastic parenchyma that may be missed by ultrasound and CT, because of its superior soft tissue resolution. It is also useful in the early detection of cancer, as the follow up of the patients is not surgically managed.

Voiding cystourethrography is indicated for the evaluation of vesicoureteric reflux, especially in children with a duplex collecting sys-

tem, while DMSA renal scintigraphy can evaluate renal functions in the normal kidney, both portions of a segmental MCDK and the compressed parenchyma (by cystic dysplasia) in classical MCDK [6]. The DTPA diuretic renal scan can demonstrate the drainage of the hydronephrotic variant [6].

The management of MCDK is a controversial topic that presents the physicians and the surgeons with a significant dilemma. Those advocating conservative management with a six monthly follow-up by sonograms based their reasoning on the fact that disappearance of MCDK is demonstrated clinically and on ultrasound in most patients by 5 years of age [15].

However, the resolution of the cysts on ultrasonography or the disappearance of the mass clearly does not equate with the resolution of the risk of hypertension, as significant stromal tissue may still be present [16].

The risk of hypertension alone is such that the conservative management of MCDK should entail lifelong follow-up with regular blood pressure assessment.

The other major complication of MCDK is malignancy. Malignancy includes Wilm's tumour, adenocarcinomas and embryonal tumours. These tumours develop in patients of various ages (Wilm's tumours in children and adenocarcinomas at ages of 15, 26 and 68 years), thus confirming the need for a lifelong follow up of conservatively managed patients. The development of hypertension and abdominal pain in case A; pyelonephritis with septicaemia in case B, as well as an unsure diagnosis and chances of malignancy in both the patients, necessitated the surgical management.

Most studies reported a low incidence of malignant transformation in MCDK; while this risk may seem to be small, there are considerable difficulties which are associated with its early detection. These include the significant regression in the size of the MCDKs, leading to the disappearance of the kidneys on ultrasound, thus preventing the early detection of the tumour growth in the stromal tissue and a high incidence of ureteral atresia which precludes early detection by either urine cytology or the development of macroscopic haematuria.

An early discharge from follow up is clearly not indicated, given the available information above. Also, there is no clear recommendation about how frequently the ultrasound should be performed, the huge financial costs and the demanding follow up of a seemingly asymptomatic child, as well as about the little or no perioperative complications of surgery (nephrectomy); these made surgical intervention the valid and cheaper option [17].

CONCLUSION

Two cases of multicystic dysplastic kidney, presenting as an abdominal mass in adults, had been discussed. The ultrasound features were also not characteristic. We also reviewed the relevant published articles. We observed that there was no consensus on

nephrectomy as the choice of treatment in a paediatric uncomplicated renal mass.

REFERENCES:

- [1] Griscorn NT, Vawter F.G, Fellers FX: Pelvi- infundibular atresia: The usual form of multicystic kidney; 44 unilateral and two bilateral cases. *Semin Roentgens* 1975;10:125.
- [2] Glassberg KI: The dilated ureter: Classification and approach. *Urology*. 1977; 9:1.
- [3] Woolf AS, Winyard PJD. Advances in the cell biology and genetics of human kidney malformations *J. Am. Soc. Nephrology*. 1998; 9: 1114-1125.
- [4] David S H, Carlton M B, Susan I et al: Management and etiology of unilateral multicystic dysplastic kidney: a review. *Paediatric nephrology*. (2009)24:233-241.
- [5] Avni E, Thova Y, Lalmard B, et al; Multicystic dysplastic kidney. Natural history from in utero diagnosis and post natal follow up. *J. Urol*. 1987; 138: 1420.
- [6] Chun chen Lin, Jeng-Dew Tsai, Jin-cheng Sheu et al. Segmental Multicystic dysplastic Kidney in children: Clinical presentation, Imaging finding, Management and outcome. *Journal of Paediatric Surgery*. Vol 45, Issue 9, S eptember 2010, Pg1856-1862.
- [7] Glassberg K.I., Stephens F.D., Lebowitz R.L., Renal dysgenesis and cystic disease of the kidney: a report of the committee on Terminology, Nomenclature and classification, section on Urology, American Academy of Paediatrics, *J. Urol* (1987), pp 1085-1092.
- [8] Rottenberg G.T., Gordon I and R De Bruyn. The natural history of the multicystic dysplastic kidney in children. *BJR*. 1997; Vol 70 Issue 832; 347 – 350.
- [9] Kliener B., Filly RA, Mack L et al Multicystic Dysplastic kidney; observations of contralateral disease in fetal population. *Radiology*. 1986 161: 27-29.
- [10] Atiyeh B, Husmann D, Baum M. Contralateral renal abnormalities in multicystic dysplastic kidney disease. *Pediatr*. 1992 Jul; 121(1):65-7.
- [11] Hayden CJ, Swischuk L. Renal cystic disease. *Semin ultrasound, CT MR*. 1991; 12: 361- 373.
- [12] Strife JL, Sonza AS, Kirks DR, et al, Multicystic dysplastic kidney in children: USS follow up. *Radiology*. 1993; 186: 705 – 788.
- [13] Fong EF, Rahman MR, Rose T, et al. Fetal renal cystic disease: sonographic-pathologic correlation. *AJR Am J Roentgenol*. 1986; 146:767.
- [14] Karmezyn B, Zerlin J.M. Lower urinary tract abnormality in children with multicystic dysplastic kidney. *Radiology*. 1997, Vol 203, 223-226.
- [15] Angelmeier KW, Kay R, Levin H. Hypertension as a complication of multicystic dysplastic kidney. *Urology*. 1992; 39: 55- 58.
- [16] Gough DCS, Postlethwaite RJ, Lewis M. A et al. Multicystic renal dysplasia diagnosed in the antenatal period – a note of caution. *Br. J. Urol*. 1995; 76: 244-248.
- [17] Webb N.J.A, Lewis M.A., Bruce J et al. unilateral multicystic dysplastic kidney: the case for nephrectomy. *Arch Dis Child*. 1997; 76: 31- 34.

AUTHORS:

- | | |
|--------------------------|---------------------------|
| 1. Dr. AREMU A ADEGOKE | 4. Dr. ASALEYE C M |
| 2. Dr. OSIATUMA VICTOR A | 5. Dr. FAMUREWA O C |
| 3. Dr. OLAJIDE ABIMBOLA | 6. Dr. ADETILOYE VICTOR A |

NAME OF DEPARTMENT(S) / INSTITUTION(S) TO WHICH THE WORK IS ATTRIBUTED:

Dept of Radiology, Ladoke Akintola University Of Technology Teaching Hospital, P.M.B.5000, Osogbo. Osun. State, Nigeria.
 Dept of Radiology, Obafemi Awolowo University Teaching Hospital, Ile-Ife. Osun. State, Nigeria.
 Dept of Surgery, Ladoke Akintola University Of Technology Teaching Hospital, P.M.B.5000, Osogbo. Osun State. Nigeria.

NAME, ADDRESS, TELEPHONE, E-MAIL ID OF THE CORRESPONDING AUTHOR:

Dr. Aremu, Ademola Adegoke, Radiology Dept, Ladoke Akintola University Of Technology, Teaching Hospital, P.M.B.5000, Osogbo. Osun State. Nigeria.
 E-MAIL: lamode70@yahoo.com, Phone: +234(0)8034061218

DECLARATION ON COMPETING INTERESTS: No competing Interests

Date of Submission: 11/11/2010
 Date of Acceptance: 10/12/2010
 Date of On Line First: 08/1/2011
 Date of Publication: 06/2/2011