

# Double Trouble in Systemic Sclerosis: Complete Heart Block and Systolic Dysfunction

AKSHYAYA PRADHAN<sup>1</sup>, SAMEER GANPAT VANKAR<sup>2</sup>, PRAVESH VISHWAKARMA<sup>3</sup>, RISHI SETHI<sup>4</sup>

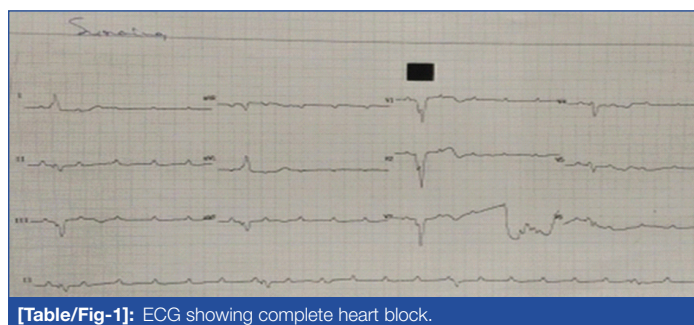
## ABSTRACT

A 26-year-old female, a known case of diffuse systemic sclerosis present with multiple episodes of syncope and progressive dyspnoea over six months. Her electrocardiogram revealed complete heart block and left ventricular systolic dysfunction with Ejection fraction of 42%. She underwent single chamber permanent pacemaker implantation and systolic dysfunction was managed medically. This case exemplifies a unique case of diffuse systemic sclerosis presenting with two rare primary cardiac manifestations namely complete heart block and systolic dysfunction, which occurred simultaneously.

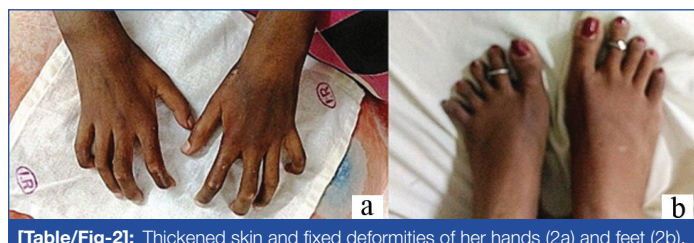**Keywords:** Pacemaker, Progressive dyspnoea, Syncope

## CASE REPORT

A 26-year-old lady, known case of Diffuse Systemic Sclerosis (DSS) diagnosed a year ago, presented with history of syncope and progressive dyspnoea. She had history of two episodes of syncope six months ago. Her Electrocardiogram (ECG) showed normal sinus rhythm and 24 hours holter study revealed occasional sinus pauses with maximum pause of 1.4 seconds. She was continuing her treatment with Methotrexate and oral corticosteroid and was kept on regular outdoor follow-up. However, her dyspnoea progressed from New York Heart Association (NYHA) class II to III over last six months. At the time of hospitalisation, she presented with multiple episodes of syncope and her ECG revealed complete heart block [Table/Fig-1]. At the time of admission, her pulse was 25/minute and blood pressure was 110/70 mm Hg. Auscultation of chest and cardiac system examination were within normal limits. She had thick skin and fixed deformities of her hand and foot [Table/Fig-2]. Her haemoglobin was 11.6 g% and serum creatinine 1.1 mg/dL. Her autoimmune test was positive for Antinuclear Antibody Titre (ANA) with 1:100 titre and homogenous pattern. She also had Scl-70 test results positive. Her double stranded deoxyribonucleic acid (dsDNA), U1 small nuclear ribonucleoprotein (U1-SNP) particle, and histone were negative.



[Table/Fig-1]: ECG showing complete heart block.



[Table/Fig-2]: Thickened skin and fixed deformities of her hands (2a) and feet (2b).

She was initially managed by temporary pacing followed by single chamber permanent pacemaker implantation. Her 2-D Echocardiography revealed global Left Ventricular (LV) dysfunction with LV Ejection Fraction (LVEF) of 42% [Video-1].

The patient was discharged uneventfully on 5 mg Ramipril, 20 mg Furosemide and 50 mg of Spiranolactone. She continued her immunomodulatory therapy for systemic sclerosis namely Methotrexate and oral corticosteroid. During her follow-up visit one and three months after discharge, patient did not have any syncope and was in NYHA II.

## DISCUSSION

This case emphasised on the rare primary cardiac manifestation of DSS namely progressive conduction abnormality from sinus pauses to development of Complete Heart Block (CHB) over six months and borderline systolic dysfunction. Arrhythmias and conduction abnormalities seen in patient with DSS can result from myocardial fibrosis and conduction system fibrosis [1]. Tachyarrhythmias usually result from myocardial fibrosis whereas bradyarrhythmias including CHB result from fibrosis of conducting system. Evaluation of cardiac involvement in DSS is important prognostically and ECG abnormalities in such patient have greatest impact in their survival. The most common abnormalities seen in the resting ECG in DSS patient was Left anterior fascicular block (16%) and first degree atrioventricular block in 8%. CHB was rare [2]. Conventional 2D ECHO in patient with DSS revealed diastolic dysfunction to be the most common feature with LV systolic dysfunction being rare. A large multicentre study reported prevalence of systolic dysfunction in 1.4% and 17.4% in diastolic dysfunction [3]. Myocardial involvement in DSS reveals microvascular alteration and collagen accumulation by activated fibroblast and altered complex immune system. These pathogenetic mechanisms result in "patchy mosaic" distribution of fibrosis which is pathognomonic of SSc.

Anuar M KT et al., reported two case reports of DDS presenting with CHB. First was 33-year-old female who was diagnosed of DSS for the last 18 years presenting with presyncope and gradual worsening exertional dyspnoea with cardiomegaly but without any signs of heart failure. She died without undergoing pacemaker. The second case which he mentioned was 56-year-old male, a diagnosed case of DSS presenting with presyncope with ECG presenting CHB without any evidence of cardiomegaly or heart failure. He underwent permanent epicardial pacing and

free of symptoms of presyncope [4]. Moysakakis I et al., also reported a case of 68-year-old female, a known case of DSS who had presented with presyncope with ECG suggestive of CHB with EF 50% and was asymptomatic after undergoing dual chamber permanent pacemaker implantation [5]. The present case exemplifies the unique twin but rare manifestations of DSS which is important to timely diagnose and manage.

## CONCLUSION

Complete heart block and left ventricular systolic dysfunction are rare primary cardiac manifestations seen in DSS patients. Progressive dyspnoea in DSS should be thoroughly investigated including the detailed cardiac evaluation for ruling out both systolic and diastolic dysfunction.

## REFERENCES

- [1] Ridolfi RL, Bulkeley BH, Hutchins GM. The cardiac conduction system in progressive systemic sclerosis. Clinical and pathologic features of 35 patients. *Am J Med.* 1976;61(3):361-66.
- [2] Follansbee WP, Curtiss EI, Rahko PS, Medsger TA, Lavine SJ, Owens GR, et al. The electrocardiogram in systemic sclerosis (scleroderma). Study of 102 consecutive cases with functional correlations and review of the literature. *Am J Med.* 1985;79(2):183-92.
- [3] De Groote P, Gressin V, Hachulla E, Carpentier P, Guillemin L, Kahan A, et al. Evaluation of cardiac abnormalities by Doppler echocardiography in a large nationwide multicentric cohort of patients with systemic sclerosis *Annals of the Rheumatic Diseases.* 2008;67:31-36.
- [4] M Anuar KT. Singham Systemic Scleroderma with Complete Heart Block *Med J Malaysia.* 1983;38(1):65-67.
- [5] Moysakakis I, Papadopoulos DP, Tzioufas AG, Votteas V. Complete heart block in a patient with systemic sclerosis *Clin Rheumatol* 2006;25(4): 551-52.

### PARTICULARS OF CONTRIBUTORS:

1. Assistant Professor, Department of Cardiology, King George's Medical University, Lucknow, Uttar Pradesh, India.
2. Senior Resident, Department of Cardiology, King George's Medical University, Lucknow, Uttar Pradesh, India.
3. Assistant Professor, Department of Cardiology, King George's Medical University, Lucknow, Uttar Pradesh, India.
4. Professor, Department of Cardiology, King George's Medical University, Lucknow, Uttar Pradesh, India.

### NAME, ADDRESS, E-MAIL ID OF THE CORRESPONDING AUTHOR:

Dr. Sameer Ganpat Vankar,  
Senior Resident, Department of Cardiology, King George's Medical University, Lucknow-226003, Uttar Pradesh, India.  
E-mail: samvan7@yahoo.co.in

Date of Submission: **Feb 23, 2018**

Date of Peer Review: **Apr 21, 2018**

Date of Acceptance: **May 22, 2018**

Date of Publishing: **Sep 01, 2018**

FINANCIAL OR OTHER COMPETING INTERESTS: None.