

# Anatomical study of Dorsalis pedis Artery and Its Clinical Correlations

VIJAYALAKSHMI S, GUNAPRIYA RAGHUNATH, VARSHA SHENOY

## ABSTRACT

To evaluate patients with arterial disease, palpation of peripheral arterial pulse is commonly used. In lower limb, palpation of dorsalis pedis artery is used to evaluate the arteriosclerotic diseases. Dorsalis pedis artery is the main source of blood supply to the foot. A knowledge about the origin, course and branching pattern of this artery is essential, as it forms the stem for one of the major myocutaneous flaps, used for ankle surgeries in plastic and reconstructive surgeries.

Fifty free lower limbs were dissected and the origin, course and branching pattern of dorsalis pedis artery were studied.

50 free lower limbs were collected from the anatomy dissection hall. The dorsalis pedis artery was dissected and its origin, course and branching pattern were studied.

In the present study dorsalis pedis artery was found to have a normal course and branching pattern in 56%, variation in origin

in 8%, variation in branching pattern in 16%, absence of the artery in 2% and duplication in 2% of the specimens studied.

As variation in dorsalis pedis artery is not uncommon, it is essential to have a sound knowledge about the artery. It is advisable to have preoperative angiography for any abnormality, to prevent risks during surgical intervention.

## KEY MESSAGE

The vascularity irrigation of the dorsum of the foot is mainly from the dorsalis pedis artery (DPA).

Palpation of foot pulses mainly DPA is used to evaluate patients with arterial diseases. This vessel provides the basis of the anatomical rationale for surgically raising a flap of skin over the dorsum of the foot, which can then be used to resurface other areas of the body.

**Key Words:** Dorsalis pedis artery, Peripheral arterial disease, Myocutaneous flap

## INTRODUCTION

With changing lifestyle, and increasing stress, mankind is more liable for diseases like diabetes and hypertension. Diabetic neuropathy leads to foot infections and ischemia, leading to the risk of major amputations. In the efforts of salvaging the ischemic limb DPA bypass acts as a major role. The dorsalis pedis artery (DPA) with its major branches is the preferentially used recipient vessel. The myocutaneous dorsalis pedis arterialised flap can be safely used as an island flap, to cover the ankle or heel and as a free flap for palm defects. Hence it was decided to study dorsalis pedis artery.

## MATERIALS AND METHODS

Fifty preserved lower extremities were used for the study. These lower limbs were dissected carefully to explore the dorsalis pedis artery, and its branches were traced and painted for clear view and photographed. In case of variations in the course and branching pattern of dorsalis pedis artery, further exploration was made. In cases of variant origin of the dorsalis pedis artery, the posterior compartment was explored and all the data were documented.

## RESULTS

The following observations were made after the dissection of the dorsalis pedis artery was carried out in all lower limbs.

The findings of this present study were grouped as follows:

1. Normal course of the dorsalis pedis artery.
2. Variant origin of the dorsalis pedis artery.
3. Variation in the course of the dorsalis pedis artery.
4. Variation in the branching pattern of the dorsalis pedis artery.
5. Absence of the arcuate artery.
6. Absence of dorsalis pedis artery.

### 1. Normal course of the dorsalis pedis artery

The chief artery of the dorsum of foot is the dorsalis pedis artery.

Most often, the anterior tibial artery continues as the dorsalis pedis artery. The anterior tibial artery enters the foot under the inferior extensor retinaculum and runs distally towards the inter-space between the first and second toes.

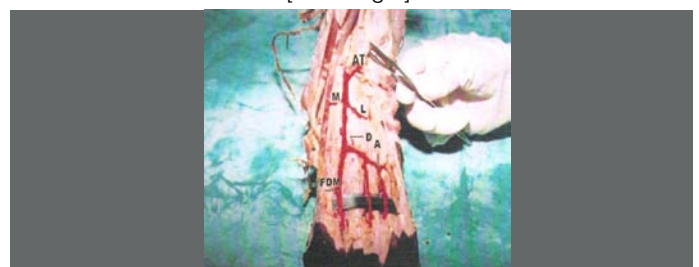The dorsalis pedis artery divides into two branches in the first dorsal intermetatarsal space. The large branch is the first dorsal metatarsal artery (deep plantar artery) that disappears between the two heads of the first dorsal interosseous muscle, into the sole of the foot.

A small-sized arcuate artery, runs transversely across the dorsum and provides most of the dorsal metatarsal arteries, usually two to four. The dorsal metatarsal arteries communicate with the plantar metatarsal arteries and end as tiny dorsal digital arteries.

**Branches from the dorsalis pedis artery are:**

1. Medial and lateral tarsal arteries.
2. Arcuate artery.
3. First dorsal metatarsal artery.

In the present study, out of 50 free lower limbs, 28 of them had normal course arising from anterior tibial artery and gave all the above said branches as in [Table/Fig 1].

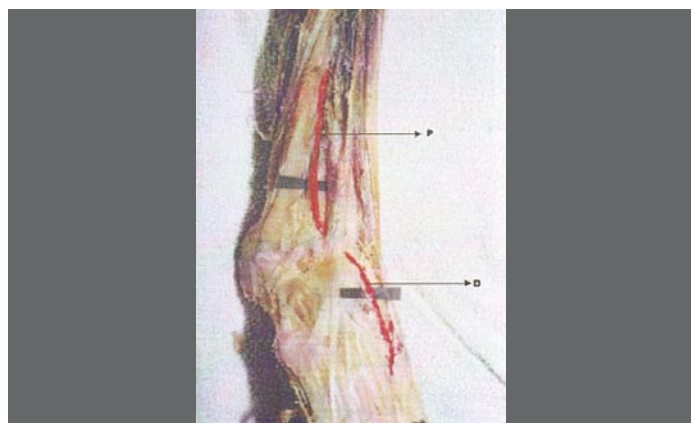


[Table/Fig 1]: Normal origin branching pattern of dorsalis pedis artery

AT- anterior tibial artery  
 M- medial tarsal artery  
 L- lateral tarsal artery  
 D- dorsalis pedis artery  
 A –arcuate artery  
 FDM – first dorsal metatarsal artery

**2. Variant origin of the dorsalis pedis artery**

The anterior tibial artery was hypoplastic and not reaching the ankle in four limbs. The peroneal artery gave rise to a perforating branch, which pierced the interosseous membrane and descended under cover of the extensor digitorum longus and peroneus tertius and anastomosed with the anterior malleolar branch of anterior tibial artery. Since anterior tibial artery was hypoplastic, the perforating branch of peroneal artery continued as the dorsalis pedis artery with normal course and branching pattern. [Table/Fig 2]

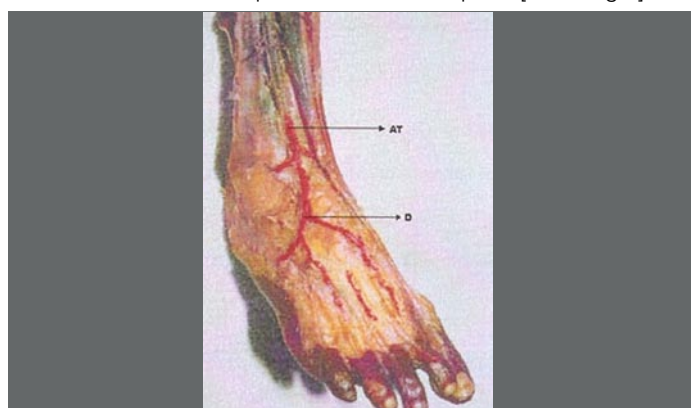


[Table/Fig 2]: Peroneal artery continuing as dorsalis pedis artery

P – Peroneal artery  
 D – dorsalis pedis artery

**3. Variation in the course of dorsalis pedis artery**

In 2 specimens, the dorsalis pedis artery had a lateral deviation away from the midline. In these cases, the dorsalis pedis artery deviated laterally in the proximal aspect and then returned to the first dorsal inter-metatarsal space in the distal aspect. [Table/Fig 3]



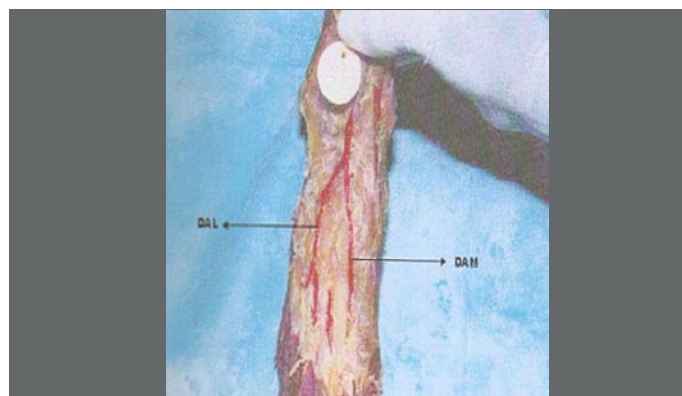
[Table/Fig 3]: Lateral deviation of the dorsalis pedis artery

AT – anterior tibial artery  
 D – dorsalis pedis artery

**4. Variation in the branching pattern of dorsalis pedis artery**

In eight specimens, the dorsalis pedis artery was found to have a short straight course and divided into medial and lateral branches. The medial branch continued as the first dorsal metatarsal artery and joined the plantar arch.

The lateral branch coursed obliquely towards the head of the other metatarsal bones and gave off the second, third and fourth metatarsal arteries which coursed in the inter-metatarsal spaces. These lateral and medial branches were named as dorsalis arteria medialis and dorsalis arteria lateralis. [Table/Fig 4]

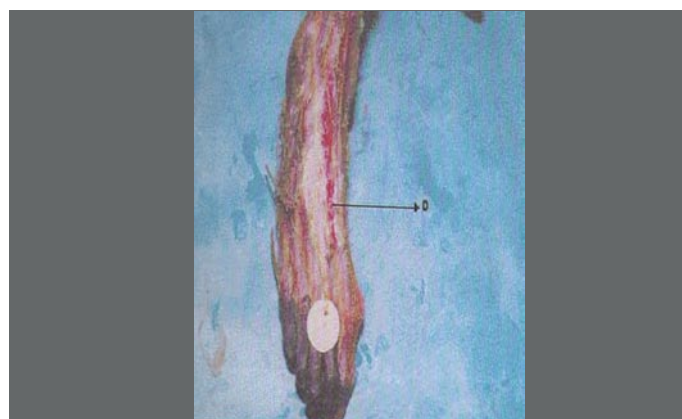


[Table/Fig 4]: Variation in branching pattern of dorsalis pedis artery

DAL – dorsalis arteria lateralis  
 DAM – dorsalis arteria medialis

**5. Absence of arcuate artery**

In three limbs, the arcuate artery failed to arise from the dorsalis pedis artery. [Table/Fig 5]

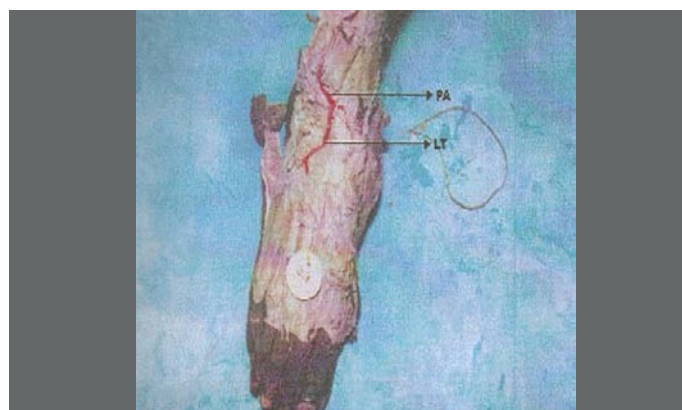


[Table/Fig 5]: Absence of arcuate artery

D- dorsalis pedis artery

**6. Absence of dorsalis pedis artery**

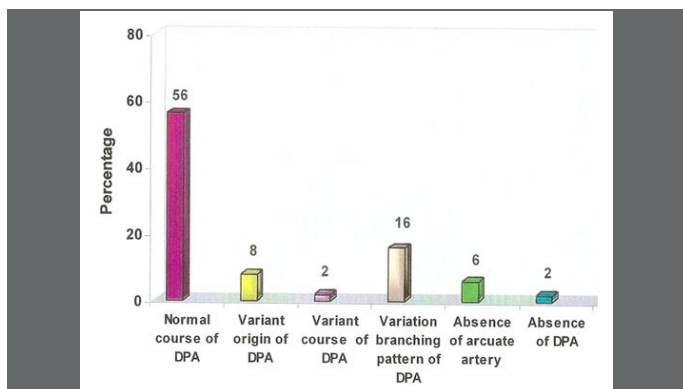
In one limb, the anterior tibial artery was hypoplastic, and the peroneal artery reached the anterior aspect of the ankle. It ended by giving a lateral tarsal branch which supplied the lateral tarsal bones. Further course of the artery was not traceable, so beyond the ankle there was absence of dorsalis pedis artery. The lateral plantar artery is larger and becomes the main source of blood supply to dorsum of foot in the absence of dorsalis pedis artery. [Table/Fig 6]



[Table/Fig 6]: Absence of dorsalis pedis artery

PA – peroneal artery  
 LT – lateral tarsal artery

The variations are summarised and are represented on bar diagram in [Table/Fig 7]



[Table/Fig 7]: Bar diagram showing the variations in dorsalis pedis artery

## DISCUSSION

Variations in the blood vessels and their anomalous course can be attributed to their development. Tiny blood vessels derived from the blood islands in the 3rd or 4th week of development, merge with each other and form a continuous network, from which buds grow out, canalise and form new vessels. New vessels of the neighbourhood areas form a closed network. Depending on the functional dominance, some vessels regress and others diverge in the mode of origin and course from the principal vessel. The dorsalis pedis artery is noted for its variations [1].

By dissecting out 100 limbs, it was noted that, only in one limb, the dorsalis pedis artery was replaced by a large perforating branch of the peroneal artery. The anterior tibial artery failed to reach the ankle and was hypoplastic. The posterior tibial artery was found to be traversing the interosseous membrane, 5 cm proximal to lateral malleolus and entered the extensor compartment [2], [3].

In the present study, it was found that the dorsalis pedis artery was a continuation of peroneal artery in 4 out of 50 limbs (8%) and the anterior tibial artery was hypoplastic, this variation was related to tobacco smokers [4].

After a study of 200 cases, normal distribution was found in 5.5% of cases. In about 3% of cases the artery arose from perforating branch of peroneal artery. In 12% of cases, it was reduced in size and almost absent. In 9% of cases, it deviated from its normal course, either laterally or medially. In 14% of cases the artery was either absent or too small to palpate [5].

In the present study, the artery had a normal course in 56% of the cases. In 8% of the limbs, the artery arose from the perforating branch of peroneal artery. In 2% of the limbs, it was absent. In 16% of the cases, the artery divided into medial and lateral branches. In 4% of limbs, it deviated laterally, suggesting the variations among dorsalis pedis artery is common.

Study of the course of dorsalis pedis artery in 67 specimens, revealed that the course of the artery was normal in 44 cases. In 15 cases, it divided into 2 terminal branches, Arteria dorsalis medialis and Arteria dorsalis lateralis, 2 cm to 3 cm distal to its origin. In 6 cases, the artery was tiny and the arterial supply of the dorsum of the foot was mainly provided by both lateral malleolar and fibular arteries. In the present study, similar variations in dorsalis pedis artery were noticed in 8 cases (16%) [6].

The arcuate artery was defined as that artery branching off from the dorsalis pedis artery at or below the level of tarsometatarsal joints, running laterally across the bases of metatarsals second to fourth and supplying the dorsal metatarsal arteries 2-4. The arcuate artery was present in only 16.7% of cases out 72 cadaveric feet [7].

The present study shows presence of arcuate artery in 76% of cases, suggesting that the arcuate artery is not the primary blood supply to the dorsal metatarsal arteries 2-4. The lateral tarsal artery

and branches from plantar arch supplied the metatarsal spaces 2-4, in the absence of arcuate artery.

Performance of a study on dorsalis pedis artery in 30 cadaveric limbs revealed that dorsalis pedis artery was absent in 6.7% of cases, the arcuate artery was absent in 33%. The dorsalis pedis artery was the continuation of peroneal artery in 6.7% of cases. The dorsalis pedis artery crossed under the extensor hallucis tendon at the ankle in 54%, above the ankle in 43% and below the ankle in 3%, suggesting the optimal site of dorsalis pedis artery anastomosis on the foot is the segment distal to the ankle [8].

In the present study, dorsalis pedis artery was absent in 2% and arcuate artery was absent in 6% of cases.

It was observed that dorsalis pedis pulse was absent in normal healthy young Chinese [9]. In 10 to 12% of people, the dorsalis pedis artery may be too small to palpate or may be away from the normal position or absent. Thus failure to detect a dorsalis pedis pulse, does not always indicate the presence of arteriosclerotic disease, but can be seen in normal persons also [10], [11].

Lateral deviation of dorsalis pedis artery and higher bifurcation of anterior tibial artery to form dorsalis pedis at the junction of upper 3/4th and lower 1/4th of leg were observed during routine dissection [12].

The same variations were also noticed in the present study in 2% of cases, suggesting that the dorsalis pedis pulse is not always felt lateral to the tendon of extensor hallucis longus, it can be deviated laterally without any vascular disease.

## SUMMARY AND CONCLUSION

In the present study, the following variations were noticed in the dorsalis pedis artery.

1. Normal course of dorsalis pedis artery in 56%
2. Variant origin of dorsalis pedis artery in 8%
3. Variation in the course of dorsalis pedis artery in 2%
4. Variation in branching pattern of dorsalis pedis artery in 16%
5. Absence of arcuate artery in 6%
6. Absence of dorsalis pedis artery in 2%

Palpation of the dorsalis pedis artery is essential, particularly in suspected cases of arterial disorders. The dorsalis pedis pulse can be usually felt on the dorsum of the foot, where the artery passes over the navicular and cuneiform bones. It may also be felt at the proximal end of first dorsal interosseous space. As observed above, the artery is subjected to variations, ranging from abnormal course, origin, distribution to complete absence. This must be kept in mind during physical examination in cases of thrombo-angitis obliterans, peripheral arterial diseases, thrombosis, acute embolism in which pulse distal to the occlusion site is lost.

Knowledge of this variation will be useful in deciding whether the absence of pulse in dorsalis pedis artery is due to thrombosis of the vessel or its abnormal course or absence. Aberration of the usual anatomic pattern of origin, branching and anastomosing pattern are thus of prime importance in surgical operative techniques. Prior confirmation by angiography for any abnormalities will avoid unnecessary surgical risks.

The artery serves as an important landmark on the dorsum of foot. The artery is recognized to play an important role in micro vascular surgery of the foot during replantations, reconstruction and repair due to its unique anatomical position and bountiful supply to the foot.

## REFERENCES:

- [1] Sadler T.W. In Langman's Medical Embryology, 5th edition, Willam and Wilkins:1985: 68- 9.

- [2] Mirwajahath Ali Dorsalis pedis artery- variation and clinical significance, Journal of Indian Medical Association; 1996;94:417-8.
- [3] Maral, Tuncel M. , CelikTas C. Anomalous Dorsalis pedis Artery. Surgical Radiology Anatomy 1994;6:319 -23.
- [4] Muir L, Labiotis N, Kuttu S, Kenerman L. Absence of dorsalis pedis pulse in the parents of children with club foot. Journal of Bone joint surgery 1995; 77: 114-6.
- [5] Huber JF. The arterial net work supplying the dorsum of foot. Anatomical Records 1941; 80: 373.
- [6] Bailleul JP, Olivez PR, Mestdagh H, Villette B . Desgraphical anatomy of the dorsalis pedis artery of the foot. Bull association of anatomy (Nancy)1984; 68: 15 – 25.
- [7] Dilandro AC, Lilja EC, Lepore FL. The prevalence of arcuate artery and a cadaveric study of 72 feet. Journal of American Pediatric Medical Association 2001;91(6):300-5
- [8] Yamada T, Glovicki P, Bower TC. Variations of the arterial anatomy of foot. American Journal of Surgery1993; 166 (2): 130 - 5.
- [9] Sun YQ, Zhu DL. Absent dorsalis pedis and posterior tibial pulsation in normal young Chinese. Chinese Medical Journal (England)1983; 96(9):643 - 6.
- [10] Keith L Moore. In clinically oriented anatomy, 3rd edition. Lippincott William and Wilkins;1992: 462 - 71.
- [11] Robert. B, Rutherford. In vascular surgery; 4thedition. W.B.Saunders company Tokyo;1992: 798 - 9.
- [12] Kesavi D, Keertisingh, Melani Rajendran S. Anamolous course of dorsalis pedis artery. Anatomical Adjuncts 2002; 3: 29 – 31.

**AUTHORS:**

1. Dr. VIJAYALAKSHMI S
2. Dr. GUNAPRIYA RAGHUNATH
3. Dr. VARSHA SHENOY

Acknowledgement: We are thankful to Dr. M Rajendran, Dr. Saraswathy Dr. HariPriya and Dr. Kesavi

**NAME OF DEPARTMENT(S) / INSTITUTION(S) TO WHICH THE WORK IS ATTRIBUTED:**

Dept of Anatomy, Saveetha Medical College

**NAME, ADDRESS, E-MAIL ID OF THE CORRESPONDING AUTHOR:**

Dr. Vijayalakshmi.S, Assistant Professor, Dept of Anatomy, Saveetha Medical College, Saveethanagar, Thandalam -602105, Kancheepuram –Tamilnadu-INDIA

E-mail: svlgp65@gmail.com, Phone: 9444183125

**DECLARATION ON COMPETING INTERESTS:** No competing Interests

Date of Submission: **Jan 18, 2011**  
Peer Review Completion: **Feb 07, 2011**  
Date of Acceptance: **Feb 12, 2011**  
Date of Publication: **Apr 11, 2011**