

Adenomatoid Odontogenic Tumour of the Maxilla and the Mandible: A report of 2 cases

A RAVI PRAKASH, P. SREENIVAS REDDY, V. SAIRAM

ABSTRACT

The purpose of this study was to report two cases of Adenomatoid Odontogenic Tumour (AOT) with a classical histological picture, one of which was located in the maxilla and the other in the mandible. Two female patients aged 17 and 22 years old presented with a painless swelling in the anterior maxilla and in the anterior mandible. The panoramic view showed circumscribed

radiolucent areas with fine calcifications in both the cases. The lesions were totally enucleated and the teeth 21 and 22 in the 1st case and 31 and 32 in the 2nd case were removed. The AOT frequently resembles other odontogenic lesions such as dentigerous cysts or ameloblastomas. Therefore, it should be distinguished from the more common lesions of odontogenic origin in routine dental examinations.

Key Words : Odontogenic, Tumour, Calcifications.

INTRODUCTION

Adenomatoid Odontogenic Tumour (AOT) is a relatively uncommon, benign and slow growing tumour which is often misdiagnosed as an odontogenic cyst[1,2]. AOT accounts for 3% of all the odontogenic tumours[3]. It is predominantly found in young and female patients, is located more often in the anterior maxilla in most of the cases and is associated with an unerupted permanent tooth, usually the lateral and canines in the 2nd decade[4].

It often causes the expansion of the surrounding bone and the displacement of the adjacent teeth[5]. However, the slow growing and painless nature of the lesion may cause the patients to tolerate the swelling for years until it produces an obvious deformity[6]. AOT was first described by Steensland in 1905[7]. However, a variety of terms have been used to describe this tumour, like adenoameloblastoma, ameloblastic adenomatoid tumour, adamantinoma, epithelioma adamantinum or teratomatous odontoma, which have been used before to define the lesion which is currently called as AOT[8,9].

In 1999, Philipsen and Riechart presented a review based on reports which were published until 1997, which showed some interesting aspects regarding the epidemiological figures of

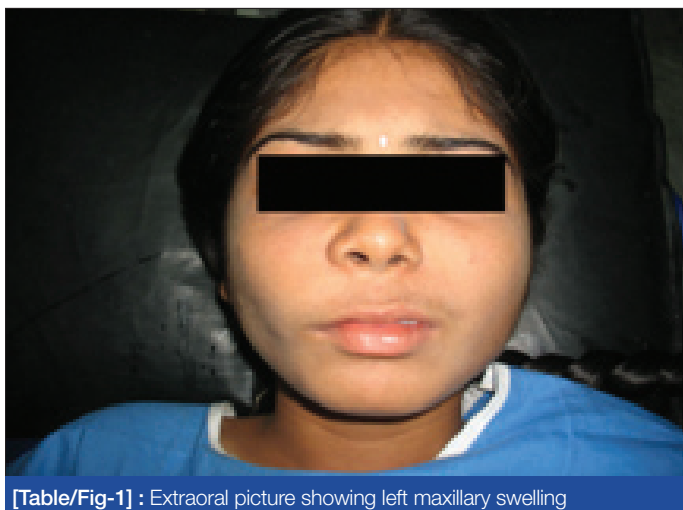this tumour. Since then, numerous case reports of AOT have been published. In this report, we present 2 cases of AOT, one occurring in the maxilla and one in the mandible, with similar classic histological features.

CASE REPORTS

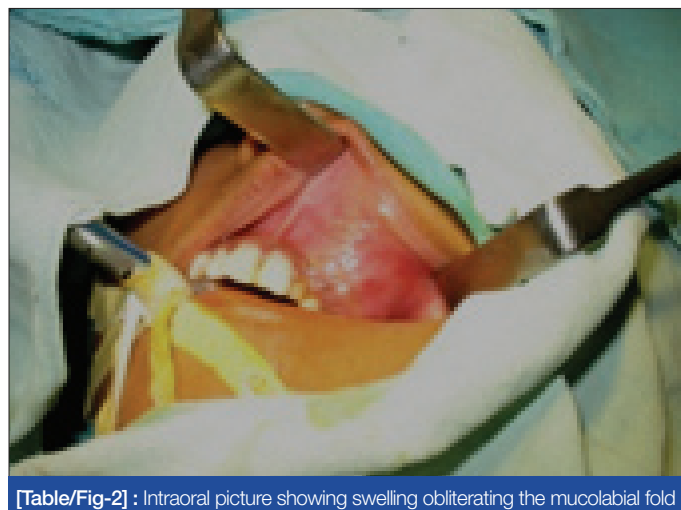Case 1:

A 17 year old girl presented a slow growing symptom free swelling in the anterior part of the maxilla of 3 months duration [Table/Fig-1]. The patient had no systemic diseases nor did she use any medication. There was no history of trauma, pain, discharge or any other symptoms which were related to the lesion. On clinical examination, the swelling was observed on the left side of the anterior maxilla.

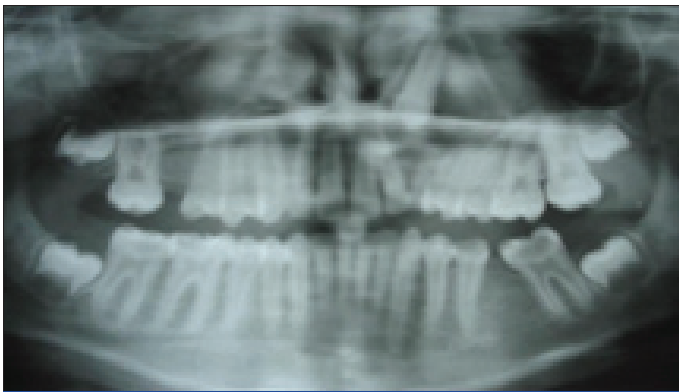
Intraorally, the patient presented with a swelling, with a mild labiolingual expansion in the maxillary alveolus in the 22 – 25 regions. The swelling had well defined margins with the normal overlying mucosa [Table/Fig-2]. The swelling was hard and non tender on palpation. The periapical and panoramic radiographs showed a unilocular radiolucency with fine calcifications, surrounding the crown of the impacted left canine, with diverging roots of 22 and 24 [Table/Fig-3]. Clinically, the case was diagnosed as AOT with impacted 23. The gross examination of the specimen



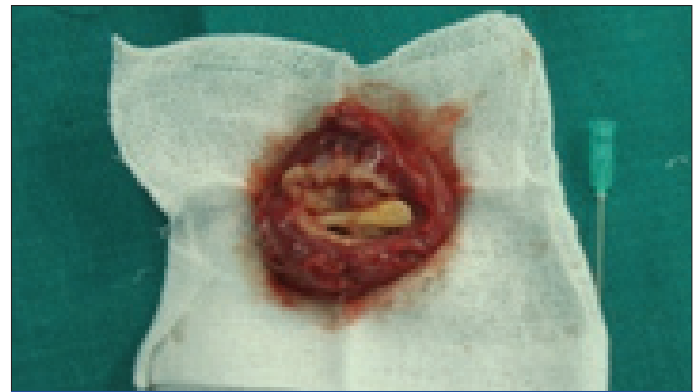[Table/Fig-1] : Extraoral picture showing left maxillary swelling



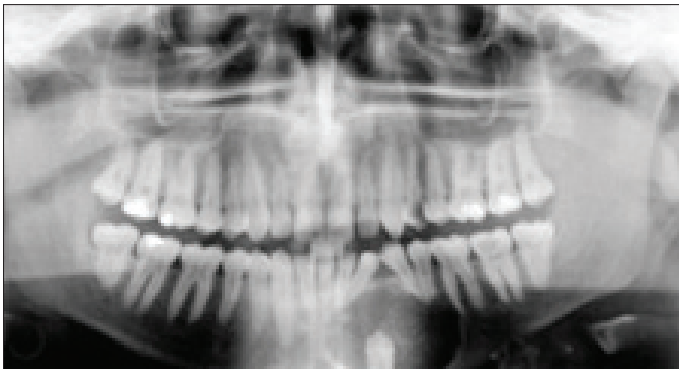
[Table/Fig-2] : Intraoral picture showing swelling obliterating the mucoabial fold



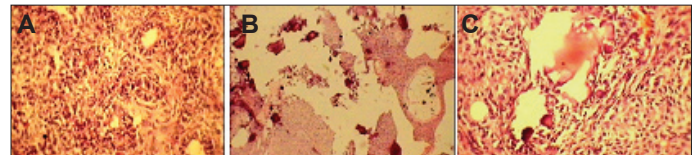
[Table/Fig-3] : Panoramic view with impacted 23



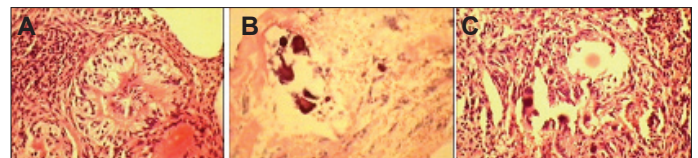
[Table/Fig-4] : The tumour was totally enucleated



[Table/Fig-5] : Panoramic view with impacted 33



[Table/Fig-6] : Photomicrograph of Case 1 showing classical AOT features. Tumour with Ductal pattern (A). Calcifications (B). Rosettes of cells (C).



[Table/Fig-7] : Photomicrograph of 2nd case with classical AOT features with ductal pattern like case 1 (A). Calcifications like case 1 (B). Rosettes of cells like case 1 (C).

showed a single pink – white soft tissue, measuring 2x2 cm, with an impacted canine within the lumen [Table/Fig-4].

Case 2:

A 22 year old female presented with a swelling that was painless, in the mental region of the mandible, of 4 months duration. The previous medical history was non contributory. The intra oral examination revealed a swelling which obliterated the labiobuccal fold in the 32- 35 region. The swelling was asymptomatic with hard consistency on palpation with the normal overlying mucosa. The panoramic radiograph showed a circumscribed radiolucent area with impacted 33. There was no root resorption, but the roots of 32 and 34 were divergent [Table/Fig-5]. The lesion was diagnosed as AOT depending on the clinical and radiographical examination. The lesion was totally enucleated.

Histologically, both the tumours showed exactly similar features with spindle shaped cells that formed sheets, strands and whorled masses of cells in a scanty fibrous stroma. The epithelial cells also showed rosette like structures with some showing central space, which was empty and few, with small amounts of eosinophilic material. Duct like structures were prominent in both the cases. Small foci of calcifications were also scattered throughout the tumour [Table/Fig-6 and 7].

DISCUSSION

The AOT is a rare odontogenic tumour which causes jaw swelling[10]. There is a slight female over male predilection which is almost 2:1[11] and it appears most often in the second decade of life. The sex and the ages of the patients that we have described in this case report were consistent with those found in literature. In our case, the lesions were typically asymptomatic, but they could cause the cortical expansion and the displacement of the adjacent teeth. The origin of the AOT is controversial, but

as it arises in the tooth bearing area, it is thought to arise from the odontogenic epithelium i.e. the cell rests of malessez[12].

The tumour has three clinicopathological variants, namely intraosseous follicular, intraosseous extra follicular, and peripheral. The follicular type is seen in 73% of all the AOT cases and is associated with an unerupted tooth as in our case, whereas the extra follicular type (24%) has no relationship with an impacted tooth, and the peripheral variant (3%) is attached to the gingival structures[13]. AOT is present more in the maxilla. In our study, one case showed the tumour in the anterior maxilla and in another one, it was located in the anterior region of the mandible.

Although larger lesions are reported in the literature, the tumours are usually in the dimensions of 1.5 – 3 cm. Radiographically, they appear unilocular and may contain fine calcifications and an impacted tooth with the displacement of the adjacent roots. This lesion should be differentiated from the calcifying odontogenic tumours or cysts, ameloblastomas, ameloblastic fibromas and ameloblastic fibro odontomas. The cases that we have described in our study, showed typically fine calcifications with impacted canines and the displacement of the adjacent roots, with no root resorption

The histological findings for AOT are remarkably similar in the literature. It presents as polygonal odontogenic cells with duct like structures and with a varying degree of inductive changes in the connective tissue. The tumour may be partly cystic and in some cases, the solid lesions may be present only as masses in the wall of a large cyst. The tumour may contain pools of amyloid like material and globular masses of calcified material. The symptoms which were presented in our cases were similar to the symptoms which were described in the literature.

The tumour is benign and well encapsulated. Therefore, conservative surgical enucleation produces excellent outcome without recurrence. Our patients have been under follow up for 6 months.

CONCLUSION

AOT occurring in the mandible is very rare. Only careful diagnosis and the adequate interpretation of the clinical and radiographical findings may be helpful in arriving at a correct diagnosis. The final diagnosis was made by the histological examination of the excised tissue specimen. The rarity of AOT may be associated with its slow growing pattern and asymptomatic behaviour.

REFERENCES

- [1] Philipsen HP, Reichart PA, Zhang KH, Nikai H, Yu QX. Adenomatoid odontogenic tumor: biologic profile based on 499 cases. *J Oral Pathol Med.* 1991;20:149–158.
- [2] Toida M, Hyodo I, Okuda T, Tatematsu N. Adenomatoid odontogenic tumor: report of two cases and survey of 126 cases in Japan. *J Oral Maxillofac Surg.* 1990;48:404–408.
- [3] White SC, Phaorah MJ. *Principles and Interpretation.* 5. St Louis; Mosby: 2004; pp. 431–433.
- [4] JGK Handschel et al. Adenomatoid odontogenic tumour of the mandible: review of the literature and report of a rare case. *Head & Face Medicine.* 2005;1:3;
- [5] Bravo M, White D, Miles L, Cotton R. Adenomatoid odontogenic tumor mimicking a dentigerous cyst. *Int J Pediatr Otorhinolaryngol.* 2005;69:1685–1688.
- [6] Olgac V, Koseoglu BG, Kasapoglu C. Adenomatoid odontogenic tumor: a report of an unusual maxillary lesion. *Quintessence Int.* 2003;34:686–688.
- [7] Steensland HS: Epithelioma adamantinum. *J Exper Med* 1905, 6:377-389.
- [8] Unal T, Cetingul E, Gunbay T: Peripheral adenomatoid odontogenic tumor: Birth of a term. *J Clin Pediatr Dent* 1995 , 19:139-142.
- [9] Dayi E, Gurbuz G, Bilge OM, Ciftcioglu MA. Adenomatoid odontogenic tumour (adenoameloblastoma). Case report and review of the literature. *Aust Dent J.* 1997;42:315–318.
- [10] Nigam S, Gupta SK, Chaturvedi KU. Adenomatoid odontogenic tumor - a rare cause of jaw swelling. *Braz Dent J.* 2005;16:251–253.
- [11] Ajagbe HA, Daramola JO, Junaid TA, Ajagbe AO. Adenomatoid odontogenic tumor in a black African population: report of thirteen cases. *J Oral Maxillofac Surg.* 1985;43:683–687.
- [12] Nergiz Yilmaz et al. Extrafollicular adenomatoid odontogenic tumour of the mandible: Report of a case. *Eur J Dent* 2009;3:71-74.
- [13] Philipsen HP, Srisuwan T, Reichart PA. Adenomatoid odontogenic tumor mimicking a periapical (radicular) cyst: a case report. *Oral Surg Oral Med Oral Pathol Oral Radiol Endod.* 2002;94:246–2489.

AUTHOR:

1. DR A RAVI PRAKASH
2. DR P. SREENIVAS REDDY
3. DR V. SAIRAM

NAME OF DEPARTMENT(S)/INSTITUTION(S) TO WHICH THE WORK IS ATTRIBUTED:

1. Department Of Oral Medicine & Radiology.
G.Pulla Reddy Dental College & Hospital, Kurnool- 518002

NAME, ADDRESS, TELEPHONE, E-MAIL ID OF THE CORRESPONDING AUTHOR:

Dr. A Ravi Prakash

Professor and Head

Department of Oral and maxillofacial pathology,
G Pulla Reddy Dental College and Hospital, Nandhyal Road,
Kurnool - 518002, Andhra Pradesh, India.

E-mail: drravi17@yahoo.com, 9448457595

DECLARATION ON COMPETING INTERESTS: No competing Interests.

Date of Submission: **Jan 12, 2011**

Date of Peer Review: **Feb 21, 2011**

Date of acceptance: **Feb 22, 2011**

Date of Publication: **Apr 11, 2011**