

Endometrial Ossification: An Unusual Cause of Infertility

MANISHA MAKKAR , PINKI PANDEY, CHINKI GUPTA, KALYANI KAPUR

ABSTRACT

Endometrial ossification, a rare but well recognized phenomenon in uterus, is the presence of bone in endometrium. It is an uncommon entity related to secondary infertility following an abortion. It is of paramount importance for the pathologists to recognize the non neoplastic nature of this condition

to avoid making erroneous diagnosis of malignant mixed mullerian tumor of the uterus. Removal of these bony bits leads to spontaneous conception. We are describing a case of endometrial ossification in a 28 years old female, presented with menorrhagia and secondary infertility.

Key Words: Endometrium, Osseous metaplasia, Infertility

INTRODUCTION

Endometrial osseous metaplasia, an uncommon entity which is related to secondary infertility following an abortion, is the presence of mature and immature bone in the endometrium. Less than 100 cases have been reported in the world literature, including nine from India [1],[2],[3].

It is important for the pathologists to recognize the non- neoplastic nature of this condition in order to avoid making a wrong diagnosis of malignant mixed mullerian tumour of the uterus. Most of patients conceive after the hysteroscopic evacuation of the bony spicules [4],[5].

We are reporting a case of endometrial ossification in a 28 year old female, who presented with menorrhagia and secondary infertility.

CASE SUMMARY

A 28 year old female patient presented to us with the complaints of menorrhagia and secondary infertility. Her past history revealed that she had one living child and two repeated abortions 6 years back, after which she had failed to conceive. Dilatation and curettage was done at 4 months of gestation during the last conception. The patient had no known history of systemic disease or haematological disorders and no such abnormality was detected after a detailed haematological work up. The patient had no signs or laboratory findings which suggested a calcium metabolism disorder. Her serum calcium and phosphorus levels were normal.

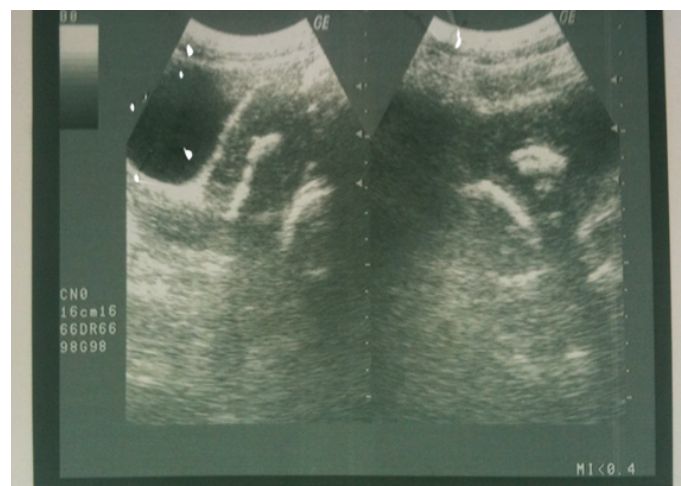
Further evaluation by ultrasonography revealed a densely echogenic band occupying most of the endometrial cavity [Table/Fig-1]. The patient underwent diagnostic hysteroscopy which revealed multiple firm to hard tissue pieces within the endometrial cavity, which were removed by using hysteroscopic forceps and these were submitted for histopathological study.

Grossly, the biopsy specimen included multiple, small, firm to hard tissue bits, along with scanty soft tissue pieces, together measuring 1×0.5×0.5 cms in dimension. The hard tissue bits were kept for decalcification. The hematoxylin and eosin stained paraffin sections were subjected for microscopic examination. The sections showed

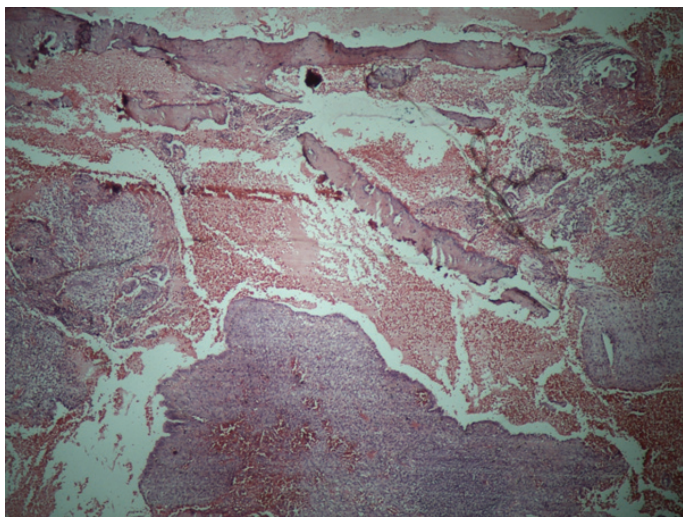
fragmented endometrial tissue which was predominantly composed of tubular glands with scanty stroma. The osteoid tissue which was mainly composed of the trabeculae of woven bone was present surrounding the endometrial tissue. The endometrial glands did not show any secretory activity. Further examination did not reveal any granuloma, inflammatory reaction, necrosis or the products of conception [Table/Fig-2] and [Table/Fig-3]. The histological diagnosis of osseous metaplasia of the endometrium was made.

DISCUSSION

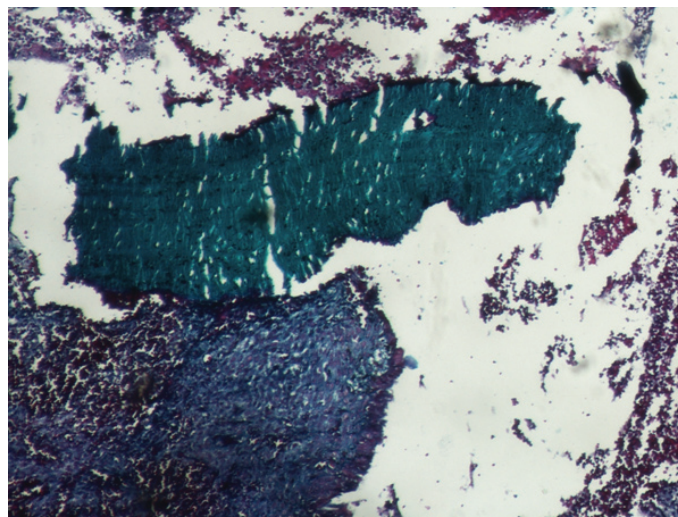
Ossification of the endometrium is a rare but well recognized phenomenon in the uterus, which is described by various other names such as ectopic intrauterine bone, heterotopic intrauterine bone and endometrial ossification. Other sites of ossification in the female genital tract are the vagina, the ovary and the cervix [1-7]. Endometrial ossification usually presents as dyspareunia, menstrual irregularities, pelvic pain, vaginal discharge and secondary infertility. Our patient also presented with secondary infertility and menorrhagia. Endometrial ossification has also been reported as a rare cause of primary infertility [2]. The cause of infertility due



[Table/Fig-1]: Ultra-sonography showing intracavitary calcification in the form of densely echogenic band



[Table/Fig-2]: Photomicrograph showing endometrial tissue with fragment of woven bone (H and E; x 40)



[Table/Fig-3]: Photomicrograph showing woven bone along with normal endometrial tissue (Masson Trichrome; x 40)

to endometrial ossification, is either increased prostaglandin production as proposed by Marcus et al [8], or its action as an intrauterine contraceptive device.

The aetiopathogenesis of endometrial ossification has been described by many theories; metabolic disorders such as hypercalcaemia, hypervitaminosis D or hyperphosphataemia and chronic endometrial inflammation such as endometritis or pyometra; persistent stimulation of the endometrium by oestrogen; osteogenesis in the surrounding endometrium which is promoted by retained foetal bones; the dystrophic calcification of retained and necrotic tissue. The most recent and accepted theory is the metaplasia of the endometrial stromal cells, usually fibroblasts, which change to osteoblasts and thus produce bone in the endometrium [1],[3],[8].

A previous history of abortion is present in most of the reported cases, with osseous changes in the endometrium. Usually the reproductive age group is involved, with a history of first trimester abortion. These patients resume the normal menstrual cycle in the post abortive period, as was seen in our case. The time interval between the antecedent abortion and the discovery of the endometrial ossification varies from 8 weeks to 14 years in the reproductive age group. In our case, the time interval was 6 years from the abortion, as compared to the history of 37 years from the abortion, which was described by Shimazu and Nakayama in a 62 years old woman [4],[9].

Intrauterine contraceptive device, malignant mixed müllerian tumour, endometrial tuberculosis and retained foetal tissue are the common differential diagnoses for the bone in the uterus, as was seen in our case. Before classifying the heterologous tissue as benign, the pathologist should exclude the possibility that the tissue in question is not a deceptively bland, appearing component of a malignant mixed müllerian tumour or an adenosarcoma. The removal of the heterotopic tissue is expected to restore the fertility, as our case demonstrated, with good endometrial response to the cyclical stimulation [10].

Physicians should also be aware of osseous metaplasia in the differential diagnosis of patients with uncertain history, who present with a sonographic image resembling an intrauterine contraceptive device [3], [4]. Endometrial tuberculosis should be ruled out, as it is a common cause of infertility in Indian females and can sometimes cause calcification and subsequent ossification in the endometrium. Retained foetal tissue is also an important differential

diagnosis for osseous metaplasia. The absence of surrounding tissue reaction and endochondral ossification may differentiate osseous metaplasia from the retained foetal tissue [4].

In the past, a series of dilatation and curettage was done to remove the bone from the endometrium, as a vigorous single curettage may lead to synechiae formation. However, recent studies recommend the complete removal of the bony spicules from the endometrial cavity hysteroscopically under ultrasonic guidance [11]. Oestrogens have a controversial role in this condition, as these can themselves cause endometrial ossification by promoting osteogenesis. As the endometrium has a high capacity for proliferation and as the endogenous hormone levels in a regularly menstruating woman are sufficient for its proliferation, this approach is unlikely to be practical [4],[5].

CONCLUSION

This case report highlights endometrial ossification as a very rare and peculiar cause of infertility. Fertility and spontaneous conception can be restored by the complete removal of the bony spicules from the endometrial cavity. Endometrial ossification is an important differential diagnosis of the malignant mixed müllerian tumour of the uterus. So, clinicians and pathologists should be aware of this entity in order to avoid an erroneous diagnosis.

REFERENCES

- [1] Bhatia NN, Hoshiko MG. Uterine osseous metaplasia. *Obstet Gynecol* 1982; 60:256-259.
- [2] Shroff CP, Kudterkar NG, Badhwar VR. Endometrial ossification-report of three cases with literature review. *Indian J Pathol Microbiol* 1985; 28:71-74.
- [3] Acharya U, Pinion SB, Parkin DE, Hamilton MP. Osseous metaplasia of the endometrium treated by hysteroscopic resection. *Br J Obstet Gynaecol* 1993; 100:391-392.
- [4] Bahneci M, Demirel LC. Osseous metaplasia of the endometrium: a rare cause of infertility and its hysteroscopic management. *Hum Reprod* 1996; 11:2537-2539.
- [5] Cayuela E, Perez-Medina T, Vilanova J, Alejo M, Capadas P. True osseous metaplasia of the endometrium: the bone is not from a fetus. *Fertil Steril* 2009; 91:1293-1294.
- [6] Bedaiwy MA, Goldberg JM, Biscotti CV. Recurrent osseous metaplasia of the cervix after loop electrosurgical excision. *Obstet Gynecol* 2001; 98:968-970.
- [7] Campo S, Campo V, Zannoni GF, Gambadauro P. Simultaneous ovarian and endometrial osseous metaplasia: a case report. *J Reprod Med* 2007; 52:241-242.
- [8] Marcus SF, Bhattacharya J, Williams G. Endometrial ossification a cause of secondary infertility. *Am J Obstet Gynaecol* 1994; 170:1381-1383.

- [9] Shimizu M, Nakayama M. Endometrial ossification in a postmenopausal woman. *J Clin Pathol* 1997; 50:171-172.
- [10] Sherman ME, Mazur MT, Kurman RJ. Benign diseases of endometrium. In: Kurman RJ ed. Blausteins Pathology of the Female Genital Tract 5th edition. New York: Springer; 2004: 421-466.
- [11] Umashankar T, Patted S, Handigund RS. Endometrial osseous metaplasia: clinicopathological study of a case and literature review. *J Hum Reprod Sci* 2010; 3:102-104

AUTHOR(S):

1. Dr. Manisha Makkar
2. Dr. Pinki Pandey
3. Dr. Chinki Gupta
4. Dr. Kalyani Kapur

NAME OF DEPARTMENT(S)/INSTITUTION(S) TO WHICH THE WORK IS ATTRIBUTED:

Department of Pathology, M.M institute of Medical Sciences and Research. Mullana-133207; Ambala, Haryana, India.

NAME, ADDRESS, TELEPHONE, E-MAIL ID OF THE CORRESPONDING AUTHOR:

Dr. Manisha Makkar
Sector 4, House no.231
Panchkula-134112, Haryana (India)
E-mail drmanishamakkar@yahoo.co.in
Mob. No. 09501588899

DECLARATION ON COMPETING INTERESTS:

No competing Interests.

Date of Submission: **25 Jan 2011**

Date of Peer Review: **12 Apr 2011**

Date of Acceptance: **18 Apr 2011**

Date of Publishing: **13 Jun 2011**