

Uterine Torsion Masquerading as Abruptio Placentae: Diagnosed on Laparotomy

NIRANJAN MAYADEO¹, ANUSHA DEVALLA²

ABSTRACT

Uterine torsion is a rare, life-threatening and unexpected obstetric emergency. It is almost always diagnosed at caesarean section. Its ill-defined clinical presentation may pose a diagnostic dilemma. Here the authors present a case of 32-year-old, Primigravida, 36 weeks pregnancy with acute abdomen and intrauterine foetal demise. Clinical features resembled Abruptio Placentae. The diagnosis of uterine torsion (180°) was established on laparotomy where the left ovarian ligament was seen on the right side anteriorly. A posterior hysterotomy was done to extract the baby which was followed by detorsion of the uterus. The postoperative period was uneventful.

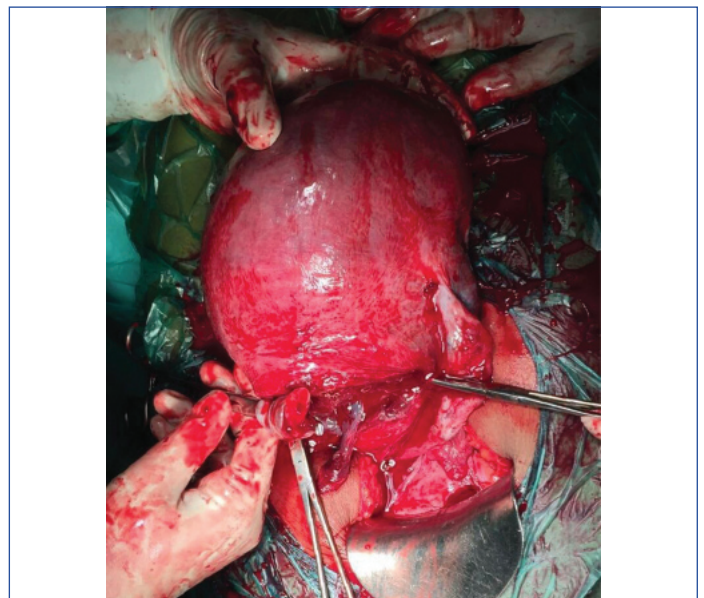
Keywords: Abdomen acute, Hysterotomy, Perinatal mortality, Pregnancy, Uterus

CASE REPORT

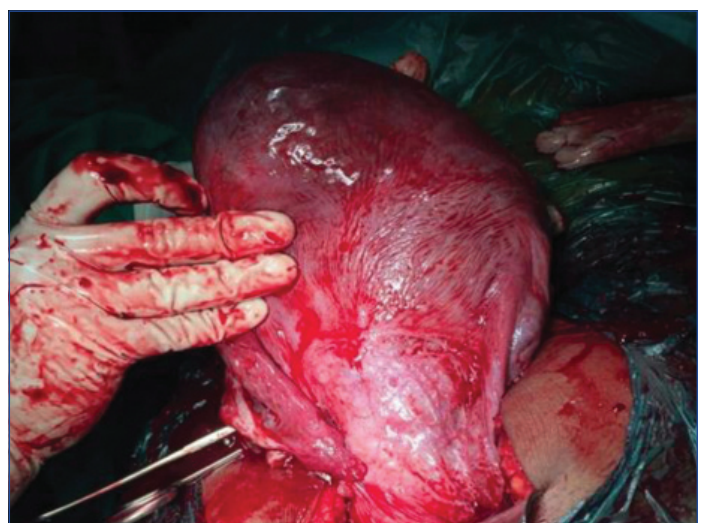
The patient was 32-year-old Primigravida with married life of five years and spontaneous conception with singleton pregnancy. She had infrequent antenatal visits at a nearby primary hospital; however, the course was uneventful. The patient denied any history of chronic medical or past surgical illness. Suddenly, at 36 weeks of gestation, the patient developed sweating, vomiting followed by acute abdominal pain not relieved with analgesics. She was not able to perceive foetal movements since the onset of pain. Within four hours of the onset of pain, she presented to our Emergency Room with pallor (1+), tachycardia (110/min) and normal blood pressure (100/70 mm Hg) with higher function well-preserved. Abdomen palpation indicated a tonically contracted uterus, foetal parts and presentation couldn't be identified, foetal heart sounds could not be appreciated. Local and Per Speculum examination revealed no fluid or blood loss. Per Vaginal examination revealed posteriorly placed, long, undilated and uneffaced cervix. Clinical impression of concealed Abruptio Placentae was made. Ultrasonography confirmed intrauterine foetal demise with no retroplacental clots.

Investigations including complete blood count and coagulation screen were within normal limits. Patient was induced with dinoprostone gel twice at an interval of six hours. The decision for delivery by emergency lower segment caesarean section was taken as there were no significant cervical changes. Patient was taken under spinal anaesthesia and abdomen opened by infraumbilical midline vertical incision. The utero-vesical fold couldn't be identified. Left-sided round ligament and ovarian ligament twisted around the uterus anteriorly and to the right (180°). A deliberate posterior transverse lower segment incision was given as a result of failure to perform detorsion [Table/Fig-1]. Liquor was found to be clear on amniotomy. A macerated male child of 1.8 kg was delivered. After baby delivery, uterus was exteriorized and findings of uterine torsion were confirmed. Uterus was seen rotated along the long axis nearly 180 degree clockwise and congestion in the fundal region secondary to torsion [Table/Fig-2]. Bilateral ovaries and fallopian tubes were found to be normal. Placenta delivered spontaneously and completely with no retroplacental clots. There was mild postpartum haemorrhage which got controlled with uterotonics. Haemostasis achieved and abdomen closed.

Vital parameters of the patient were stable postoperatively. She was given intravenous antibiotics and oral cabergoline (lactation



[Table/Fig-1]: Shows the deliberate posterior low transverse hysterotomy incision with both ovaries seen.



[Table/Fig-2]: Shows anterior surface of uterus with uterovesical fold after detorsion.

suppression) and had an uneventful postoperative recovery. She was discharged on 7th postoperative day after suture removal.

DISCUSSION

Uterine torsion is an unexpected obstetric emergency usually diagnosed at the time of caesarean section [1] and may jeopardise maternal and foetal outcomes. Mild dextrorotation (less than 45°) is a common physiological phenomenon. The rotation around the cervical canal (longitudinal) may be from 45° to 180°, although some cases up to 720° have been documented [2]. The vague symptoms and rarity of this condition raises concern for its management [3]. Obstruction of the uterine veins raises pressure

in the placental cotyledons leading to abruption and foetal distress. If left uncorrected, it may lead to uterine artery obstruction interrupting the placental perfusion causing intrauterine foetal demise [4].

Cases of uterine torsion have been reported sporadically in the literature, first in 1863, Virchow demonstrated in a human during postmortem examination. In 1876, Labbe described this abnormality for the first time in a living woman [3].

Only about 200 cases have been reported in the last 100 years.

Year	Author	Age of patient	Gravidity	Gestational age	Case details	Diagnostic modality	Intraoperative findings	Treatment	Outcome
2011	Deshpande G et al., [4]	25 years	G1	38 weeks	Abdominal pain and uterine tenderness with foetal bradycardia	Intraoperative	180° torsion	Detorsion of uterus with lower segment caesarean section, fundal fibroid 10×10 cm	Both mother and foetus doing good
2012	Rasquinha SD et al., [9]	31 years	G3P2	38 weeks	Asymptomatic	Intraoperative	Uterine torsion 180°	Posterior hysterotomy followed by baby delivery and uterine detorsion	Neonate and mother fine
2012	Gohil A and Patel M [10]	23 years	G1	28 weeks	Acute pain in abdomen and uneasiness	Intraoperative	180° laevorotation with profuse congestion	Obstetric hysterectomy with baby in-situ	IUD baby, mother well
2013	Qureshi S et al., [11]	25 years	G2P1	25 weeks	Pain in abdomen, bleeding per vaginum, decreased foetal movements	Intraoperative	180° uterine torsion with IUFD abruptio placentae	Deliberate posterior hysterotomy; Obstetric hysterectomy (all medical and conservative surgical failed)	Mother died of pulmonary embolism, IUD baby
2013	Bissa U and Shyam KR [3]	20 years	G1	28 weeks	Pain in abdomen, vomiting, reduced foetal movements. IUFD on UG and subacute intestinal obstruction	Intraoperative	720° uterine torsion	Detorsion of the unicornuate uterus followed by obstetric hysterectomy; no features of intestinal obstruction	Mother fine
2014	Sachan R et al., [12]	27 years	G2P1	20 weeks	Acute pain with shock	Intraoperative	360° axial torsion, massive abruption, large fundal leiomyoma	Detorsion followed by hysterotomy, uterine artery ligation to treat atonic PPH, Blood transfusions	Mother doing well, 16 weeks IUD baby
2015	Varsha S et al., [13]	26 years	G5P4L1D2A1	36 weeks	Shock and intrauterine foetal demise	Intraoperative	180° uterine torsion	Detorsion followed by hysterotomy by LSCS, dead foetus delivered; subtotal hysterectomy due to uterus atony	IUD baby, Mother doing well
2015	Singh P et al., [14]	28 years	G3P2	20 weeks	Pain in abdomen	MRI (preoperative)	Unruptured pregnancy in rudimentary horn with torsion of gravid horn	Resection of the rudimentary horn (left) with the necrosed left adnexa	IUD baby, Mother well
2016	Ulu I et al., [1]	37 years	G3P2	32 weeks	Severe abdominal pain and mild vaginal bleeding with foetal decelerations	Intraoperative	180° torsion, subchorionic hematoma, 5×4 cm fibroid	Detorsion failed; posterior hysterotomy	Baby admitted in NICU, discharged in two weeks; mother doing well
2016	Chundawat RS et al., [15]	22 years	G2P1	28 weeks	Primary abdominal pregnancy with dead foetus and gravid uterus	Intraoperative	Uterine torsion 180°	Detorsion unsuccessful followed by posterior hysterotomy, clots 400 mL	Mother fine, baby IUD
2017	Goswami B and Gautam H [16]	23 years	G1	31 weeks	Pain in abdomen with reduced foetal movements	Intraoperative	180° torsion of gravid right-sided horn of bicornuate uterus	Excision of that horn and delivery of foetus by posterior hysterotomy	Mother fine, baby IUD
2018	Kumar N et al., [17]	16 years	G1	17 weeks	No specific complaints	Intraoperative	Non-communicating rudimentary horn torsion 90° and rupture	Rudimentary horn resected with the tube	Mother fine, IUD baby
2018	Toshniwal R [18]	27 years	G4P1L1A2	20 weeks	Severe abdominal pain with shock	Intraoperative	Torsion of left horn of bicornuate uterus 90°	Posterior hysterotomy and detorsion	IUD baby, Mother well
2018	Thanappan A [19]	29 years	G4P1L1A2	25 weeks	Acute pain in abdomen with shock	Intraoperative	Uterine torsion 180°	Classical incision on posterior uterine surface, two litre blood clots drained, detorsion	IUD baby, mother fine
2020	Present study	32 years	G1	36 weeks	Sweating, vomiting, abdominal pain	Ultrasonography (preoperatively)	Uterine torsion 180°	Postero-transverse lower segment incision given. Delivery done.	Macerated baby, mother fine

[Table/Fig-3]: Reports of uterine torsion in pregnancy in the last decade (2011-2020) from India.

IUFD: Intrauterine foetal death; IUD: Intrauterine device; NICU: Neonatal intensive care unit; UG: Ultrasonography; PPH: Post-partum haemorrhage; LSCS: Lower segment caesarian section

Most of the cases in the literature associated with uterine torsion had singleton pregnancies; however, few have occurred in twin pregnancies as well. Uterine torsion in pregnancy can occur in any trimester, age and parity. The cases reported in the literature from India in the last decade (2011-2020) have been tabulated below [Table/Fig-3].

Kopko J et al., recently in 2019 described an incidental finding of uterine torsion of 100 degrees on laparotomy during 2nd trimester, done for appendectomy [5]. Only one maternal death has been observed in the last 50 years [6]. The chances of perinatal mortality secondary to foetal compromise may be as high as 12-18% [2]. Uterine leiomyomas were one of the major risk factor contributing to 31.8%, uterine anomalies were 19.9%, pelvic adhesions 8.4%, ovarian cyst 7%, malpresentations (particularly transverse lie) 4.3%, deformities 2.7% and unknown causes 25.5% [6]. Also uterine torsion with demonstrated foetal bradycardia associated with external cephalic version due to uterine torsion [6].

In this case, there was no apparent cause identified.

The clinical features may cause diagnostic dilemma due to absence of pathognomic symptoms. Common presentations being shock, intestinal obstruction, bleeding per vaginum, labour dystocia. Some may even remain asymptomatic [6]. Associated adnexal torsion requiring bilateral salpingo-oophorectomy has only been reported in 7% of cases [7]. A partial bladder torsion has been reported by Kilicci C associated with 720 degrees of uterine torsion [2]. In some cases, the diagnosis is only made after delivery of the foetus if the repair of posterior hysterotomy incision seems vascular. Radiological investigations may not be much yielding in such emergency situations. Common differential diagnoses includes ectopic pregnancy, placental abruption, intra-abdominal bleeding, torsion of a pelvic tumour, peritonitis, obstructed labour.

Wherever possible, an attempt to detort the uterus should be performed. It has been suggested, vertical hysterotomy/caesarean section should be advised in suspected cases to prevent the vascular or ureteral injury [1]. At term, uterus is derotated and lower segment caesarean section is done. Bilateral plication of utero-sacral ligaments as described by Ulu I et al., to prevent long-term recurrence of uterine torsion still lacks proper validation [1]. Such patients with incision on the posterior wall of the uterus preferably should have a repeat caesarean section in future pregnancy, since the risk of rupture is not known [8]. Hysterectomy should be considered only for greater degree and long-standing cases of torsion.

The correctable factors responsible for the uterine torsion should be dealt with during laparotomy. Difficulty in assessing the uterine scar integrity in the subsequent pregnancy owing to the posterior uterine incision and prior caesarean section being one of the risk factor for torsion, the patient must be advised for a suitable contraception and a close antenatal follow-up in the next pregnancy.

We have revisited various reports published by Indian authors in the

literature (last decade) of cases with uterine torsion in pregnancy [Table/Fig-3].

CONCLUSION(S)

Obstetricians should have this condition in mind while performing caesarean section on a patient with acute abdomen associated with foetal malpresentations, uterine tumours and structural uterine abnormalities. Anatomical landmarks (round ligament) should always be defined prior to uterine incision during a caesarean section, to prevent damage to uterine vessels and to check for any degree of torsion of the pregnant uterus.

Acknowledgement

The authors are thankful to the patient giving signed consent for this publication.

REFERENCES

- [1] Ulu I, Guneş MS, Kiran G, et al. A rare cause of placental abruption: Uterine torsion. *J Clin Diagn Res JCDR*. 2016; 10(1):QD06-07.
- [2] Kilicci C, Sanverdi I, Bostanci E, Abide CY, Eser SK. Uterine torsion of 720 degrees in the third trimester of pregnancy and accompanying bladder torsion: A case report. *Pan Afr Med J*. 2018;29:175.
- [3] Bissa U, Shyam KR. Complete Axial Torsion of Gravid Uterus By 720. *IOSR Journal of Dental and Medical Sciences*. 2013;7(4):12-15.
- [4] G. Deshpande, R. Kaul, and P. Manjuladevi. A case of torsion of gravid uterus caused by leiomyoma. *Case Reports in Obstetrics and Gynecology*. 2011;2011(10):206418.
- [5] Kopko J, Stariczak R, Warzecha D, Wielgos M. Uterine torsion in the second trimester of pregnancy. *Neuro Endocrinol Lett*. 2019;39(6):423-26.
- [6] Zullino S, Faiola S, Paganelli AM, Ferrazzi E. A Case of Abruption Placentae due to the Torsion of Gravid Uterus. *Case Rep Obstet Gynecol*. 2014;2014:801616.
- [7] Cook KE, Jenkins SM. Pathologic uterine torsion associated with placental abruption, maternal shock, and intrauterine fetal demise. *Am J Obstet Gynecol*. 2005;192(6):2082-83.
- [8] A Dua, K Fishwick, B Deverashetty. Uterine Torsion in Pregnancy: A Review. *The Internet Journal of Gynecology and Obstetrics*. 2005;6(1):01-03.
- [9] Rasquinha SD, Rao SB, Rasquinha, VC, Aithal V. A twist in the tale- Rare case of uterine torsion. *International Journal of Biomedical Research*. 2013;3(11):435-36.
- [10] Gohil A, Patel M. Torsion of gravid uterus managed by obstetric hysterectomy with the fetus in situ. *J Obstet Gynecol India*. 2013;63(4):279-81.
- [11] Qureshi S, Singh U, Bansal B, Singh N. Torsion of preterm gravid uterus: A case report. *International Journal of Case Reports and Images*. 2013;4(7):392-95.
- [12] Sachan R, Patel ML, Sachan P, Arora A. Complete axial torsion of pregnant uterus with leiomyoma. *BMJ Case Rep*. 2014; 2014. doi: 10.1136/bcr-2014-205558.
- [13] Varsha S, Devi GP, Bharathi T, Priya VP, Rao SS, Israel YN. A twist in the diagnosis ... and the uterus! A case report of third trimester uterine torsion. *Journal of Clinical and Scientific Research*. 2015; 4(3):240-43.
- [14] Singh P, Gupta R, Das B, Bajaj SK, Misra R. Midtrimester spontaneous torsion of unruptured gravid rudimentary horn: Presurgical diagnosis on magnetic resonance imaging. *J Obstet Gynaecol Res*. 2015;41:1478-82.
- [15] Chundawat RS, Rastogi R, Tak A. Torsion of gravid horn of bicornuate uterus: A rare case report. *Int J Reprod Contracept Obstet Gynecol*. 2016;5(7):2428-30.
- [16] Bivarani Goswami, Himleena Gautam. Torsion of Gravid Horn of Bicornuate Uterus in 3rd Trimester- A Case Report. *IOSR Journal of Dental and Medical Sciences*. 2017;16(9):01-04.
- [17] Kumar N, Das V, Pandey A, Agarwal S. Torsion and rupture of a non-communicating rudimentary horn in a 17-week gestation in a 16-year-old girl: Lessons learnt. *BMJ Case Reports*. 2018;2018:bcr-2017-222073.
- [18] Toshniwal R. Uterine Torsion in 20 Weeks of Pregnancy: A Rare Case Report. *J Obstet Gynaecol India*. 2019;69(1):28-30.
- [19] A Thanappan. Uterine torsion in pregnancy- A rare case report. *University Journal of Medicine and Medical Specialities*. 2018, Vol. 4(3).

PARTICULARS OF CONTRIBUTORS:

1. Professor, Department of Obstetrics and Gynaecology, Seth GS Medical College, KEM Hospital, Mumbai, Maharashtra, India.
2. Junior Resident, Department of Obstetrics and Gynaecology, Seth GS Medical College, KEM Hospital, Mumbai, Maharashtra, India.

NAME, ADDRESS, E-MAIL ID OF THE CORRESPONDING AUTHOR:

Anusha Devalla,
House No. 15, Sector 9A, Saket Nagar, Bhopal-462024, Madhya Pradesh, India.
E-mail: anushadevalla2@gmail.com

AUTHOR DECLARATION:

- Financial or Other Competing Interests: None
- Was informed consent obtained from the subjects involved in the study? Yes
- For any images presented appropriate consent has been obtained from the subjects. Yes

PLAGIARISM CHECKING METHODS: [Jan H et al.]

- Plagiarism X-checker: May 23, 2020
- Manual Googling: Jul 24, 2020
- iThenticate Software: Sep 29, 2020 (13%)

ETYMOLOGY: Author Origin

Date of Submission: **May 22, 2020**
Date of Peer Review: **Jul 08, 2020**
Date of Acceptance: **Jul 24, 2020**
Date of Publishing: **Oct 01, 2020**