

Clinical Characteristics of Pigment Dispersion Syndrome and Pigmentary Glaucoma Patients: A Cross-sectional Study

VIJAY PRATAP SINGH TOMAR¹, SANDEEP SHARMA², RAHUL BHARDWAJ³, SINDHUJA SINGH⁴,
VIRENDRA KUMAR PAL⁵, NIKITA JAISWAL⁶, PRAKHAR CHAUDHARY⁷, SAURABH SUMANGLAM⁸



ABSTRACT

Introduction: Pigmentary Glaucoma (PG) and Pigment Dispersion Syndrome (PDS) are two different spectrums of a single disease. Since the disease is seen in younger population and is rapidly progressive blinding disease, therefore early diagnosis and treatment will reduce the burden of the disease and improve the quality of life.

Aim: To evaluate clinical characteristics of PDS and PG patients in eastern part of Uttar Pradesh.

Materials and Methods: This was a two years (1st January 2018 to 31st December 2019) hospital-based retrospective cross-sectional study of patients who attended the glaucoma clinic. Diagnosis of PDS was made when they had normal optic disc, normal visual field {with or without increased Intra Ocular Pressure (IOP)} and at least two of the following three signs were found clinically: Krukenberg spindle, homogenous moderate-to-heavy (\geq Spaeth 2+) Trabecular Meshwork (TM) pigmentation, and any degree of zonular and/or lenticular pigment granule dusting. Patients with PDS were diagnosed with PG, if they had two or more of the following findings: initial IOP >21 mmHg, glaucomatous optic nerve damage or glaucomatous visual field loss. Various parameters such as

influence of demographics, IOP, Best-Corrected Visual Acuity (BCVA), Central Corneal Thickness (CCT), Mean Deviation (MD), Visual Field Index (VFI %), spherical equivalent and clinical finding of anterior segment of study patients were analysed. Mean, standard deviation and percentage were calculated using GraphPad InStat version 3.0.

Results: Among 40 patients, nine eyes of the six patients had myopia of $-0.5D$ or greater, with mean refractive error of -3.55 ± 4.72 spherical equivalent. The average baseline IOP in study patients (PDS+PG), was 30.21 ± 11.42 mmHg. Twenty four (60%) patients, either in one or both eyes had glaucoma, secondary to PDS at the initial diagnosis. Thirty three (82.5%) patients had Krukenberg spindles. Homogeneous TM pigmentation was seen in all patients. Typical spoke-like radial Iris Transillumination Defects (ITDs) were not observed in any of the patients except in one patient, who had isolated short slit-like trans-illumination defects in iris crypts.

Conclusion: PDS patients with normal optic disc and visual field and raised IOP, should be started prophylactic treatment and needs to be monitored more closely. Thus, the finding of PDS in Indians should alert the ophthalmologist to look for glaucoma during the initial examination.

Keywords: Clinical characteristic, Iris transillumination defects, Trabecular meshwork

INTRODUCTION

In 1949, Sugar HS and Barbour FA [1], described a novel clinical form of glaucoma with marked dispersion of pigment onto several structures in the anterior and posterior chamber. They named this entity as PG. It has a diagnostic triad which consists of: 1) slit like mid-peripheral Iris Trans-Illumination Defects (ITD); 2) diffuse and dense brownish pigmentation of the anterior chamber angle; and 3) pigment granules on the corneal endothelium (the 'Krukenberg spindle'). The diagnosis of PDS was made when these findings were not associated with glaucoma.

It has been documented that there is a release of melanin pigment from Iris Pigment Epithelium (IPE) in PDS patients' eyes, which is deposited on Trabecular Meshwork (TM), lens zonules, lens surface, iris surface and corneal endothelium by aqueous convection currents. Accumulation of pigments in TM is responsible for increased aqueous outflow resistance, which may lead to PG [2,3].

Studies done earlier showed the varied clinical features and prevalence of PDS, in different racial group. Among adult whites, the prevalence of PDS was 2.45% [1,4-7]. In a study [9] among black population (>7 years of age), the prevalence of PDS was found to be $0.167\% \pm 0.013$. The black and white PDS patients have different spectrum of clinical signs like ITDs and anterior iris stromal pigment dusting were not found common in black patients as in whites [8-13].

The Caucasians of age between 20 to 45 years are more commonly affected by PDS. It is relatively less common in Asians and Africans. PDS patients with sustained IOPs >21 mmHg and no optic nerve changes or visual field loss should probably be treated with IOP-lowering therapy [14]. The aim of this study was to evaluate clinical characteristics of PDS and PG patients in eastern part of Uttar Pradesh.

MATERIALS AND METHODS

This was a hospital based retrospective cross-sectional study done at a tertiary eye care center of Regional Institute of Ophthalmology, Sitapur, Eastern Uttar Pradesh region. The study was approved by the Institutional Review Board of the parent institution and adhered to the tenets of the Declaration of Helsinki, (IEC No- SHE/2019.20/640). Informed consent was obtained from all patients before undertaking treatment options.

The records of all patients who were diagnosed, either as PDS or PG, from 1st January 2018 to 31st December 2019 (2 years), were analysed and included in this study.

Inclusion and Exclusion criteria: Patients who underwent a complete ophthalmic examination, with complete records and clinical finding consistent with either PDS or PG or both, were included in this study. Patients with any previous ocular surgery, laser treatment, uveitis, any ocular trauma, exfoliative material and pseudo exfoliation were excluded from the study.

The patients were divided into PDS and PG group. Diagnosis of PDS was made when at least two of the following three signs were found clinically: Krukenberg spindle, homogenous moderate-to-heavy (\geq Spaeth 2+) TM pigmentation, and any degree of zonular, and/or lenticular pigment granule dusting, with normal Optic Nerve Head (ONH) and normal visual field and with or without increased IOP. PDS may or may not be associated with increased IOP [15]. Patients with PDS were diagnosed with PG, if they had two or more of the following findings: initial IOP >21 mmHg, glaucomatous optic nerve damage or glaucomatous visual field loss.

Comprehensive ophthalmic examinations included visual acuity measurement by Snellen's chart and converted to corresponding log Minimum Angle of Resolution (MAR) values, refraction, IOP measurement by Goldmann applanation tonometer, slit-lamp biomicroscopy pre- and postmydriasis, gonioscopy, fundus examination, peripheral retinal examination and automated Humphrey Swedish Interactive Threshold Algorithm (SITA) standard 24-2 visual field test, or by Humphrey automated 10-2 SITA standard perimetry if their glaucomatous damage was very severe. Systemic and ocular medical history of each subject was also recorded.

All the patient were evaluated for the corneal endothelial pigmentation, anterior iris stromal pigment dusting, ITDs, posterior iris bowing (concave iris configuration), increased TM pigmentation, pigment granule dusting on lens zonules or peripheral posterior surface of lens, peripheral retinal degeneration and pigmentation and optic disc examination. Pigmentation of TM was leveled as 0 no pigment, 1+ minimal, 2+ mild, 3+ moderate and 4+ intense, by Spaeth grading system [16]. Pigment deposition on corneal endothelium was depicted as Krukenberg spindle, diffuse pigmentation or no pigmentation. Each patient's Central Corneal Thickness (CCT) was measured using an ultrasonic pachymeter. The average of five CCT values was taken.

Sample Size

Sample size was calculated by using formula, given below:

$$n = z^2 \times p \times (1-p) / e^2$$

Where, $z=1.96$ for a confidence level (α) of 95%, p =proportion, e =margin of error, n =sample size;

$$z=1.96, p=0.02 (2\%), e=0.05 (5\%)$$

$$n = 1.96^2 \times 0.02 \times (1-0.02) / 0.05^2$$

$$n = 0.0753 / 0.0025 = 30.118$$

$$n = 0.0753 / 0.0025 = 30.118, n \approx 31$$

The sample size came out to be approximately 31.

STATISTICAL ANALYSIS

All statistical analyses were done at 5% significance using Graph Pad InStat version 3.0 and Microsoft Excel 2019. Descriptive analysis such as mean, standard deviation and percentage were used to exhibit the clinical parameters. A p -value less than 0.05 considered statistically significant.

RESULTS

Out of 1202 patients, examined in glaucoma specialty clinic during the 2-years period of time, a total of 40 patients were diagnosed as having either PDS or PG. Out of total 40 patients, 16 patients were diagnosed as PDS and 24 as PG. Out of total 80 eyes, 39 eyes had PDS and 41 eyes had PG. Thirty one (77.5%) were male and nine (22.5%) patients were female. Mean age of study patients was 36.52 ± 8.91 years (range, 16-57) with male to female ratio 3.4:1. The average age of PDS and PG patients were 36.5 ± 11.76 and 36.5 ± 6.34 years, respectively. There was no statistically

significant difference between age of PDS and PG patients ($p=1.0$). Demographic characteristics are summarised in [Table/Fig-1].

Variable	All study patients	PDS	PG	p-value (PDS vs PG)
Total No. of patients	40	16	24	-
Total No. of eyes	80	39	41	-
Male/Female	31/9	11/5	20/4	0.44*
Male:Female ratio	3.4:1	2.2:1	5:1	-
Age (years)	36.52 ± 8.91	36.5 ± 11.76	36.5 ± 6.34	1.0 [§]
Male	36.1 ± 8.7	34.9 ± 12.1	36.8 ± 5.63	0.5534 [§]
Female	37.9 ± 10.5	40 ± 10.13	35.25 ± 8.98	0.4853 [§]

[Table/Fig-1]: General characteristics of study patients.

PDS: Pigment dispersion syndrome; PG: Pigmentary glaucoma; *Chi-square test
[§]unpaired t test, statistical significance level ≤ 0.05

Average Best Corrected Visual Acuity (BCVA) (log MAR) of all the patients was 0.36 ± 0.75 while among PDS and PG patients, it was 0.038 ± 0.15 and 0.58 ± 0.89 , respectively ($p=0.0001$). The mean CCT (μ m) of all the study patients was 538.6 ± 27.82 while for PDS and PG patients, it was 550.18 ± 23.10 and 530.87 ± 28.03 , respectively ($p=0.0280$) [Table/Fig-2]. All patients except nine eyes of the six patients had myopia of $-0.5D$ or greater, with mean refractive error of -3.55 ± 4.72 spherical equivalent (range, -24.75 to 0.5). The mean refractive error of PDS patients was -1.22 ± 1.49 (range, -4.5 to $+0.5D$) and in PG eyes was -5.10 ± 5.44 spherical equivalent (range, -24.75 to $-0.25D$), ($p=0.0085$), [Table/Fig-2]. The average baseline IOP in all study patients was 30.21 ± 11.42 mmHg (range 12-56). The average IOPs in PDS and PG patients were 21.75 ± 8.27 mmHg and 35.85 ± 9.61 mmHg, respectively ($p=0.001$) [Table/Fig-2]. Thirty six out of forty patients had increased initial IOP of >21 mmHg in at least one eye at the time of diagnosis and 62 eyes out of 80 eyes had initial IOP of >21 mmHg. The average baseline MD and average VFI (%) of all study patients, on Humphrey visual field analysis were -7.71 ± 8.29 and 83.58 ± 22.24 , respectively. In PDS and PG group average baseline MD were -0.423 ± 1.18 and -12.9 ± 7.21 , respectively ($p=0.0001$). The VFI (%) were 98.03 ± 1.62 and 73.95 ± 24.31 in PDS and PG groups, respectively ($p=0.0003$) [Table/Fig-2].

Variables (Mean \pm SD)	All study patients (n=40)	PDS (n=16)	PG (n=24)	p-value (PDS vs PG)
BCVA (log MAR)	0.36 ± 0.75	0.038 ± 0.15	0.58 ± 0.89	0.0001 [§]
CCT (μ m)	538.6 ± 27.82	550.18 ± 23.10	530.87 ± 28.03	0.0280 [§]
Baseline IOP (mmHg)	30.21 ± 11.42	21.75 ± 8.27	35.85 ± 9.61	0.0001 [§]
C:D ratio	0.667 ± 0.235	0.478 ± 0.134	0.793 ± 0.202	<0.001 [§]
Baseline MD	-7.71 ± 8.29	-0.423 ± 1.18	-12.9 ± 7.21	0.0001 [§]
VFI (%)	83.58 ± 22.24	98.03 ± 1.62	73.95 ± 24.31	0.0003 [§]
Spherical equivalent	-3.55 ± 4.72	-1.22 ± 1.49	-5.10 ± 5.44	0.0085 [§]

[Table/Fig-2]: Baseline Investigation findings in study patients.

BCVA: Best corrected visual acuity; CCT: Central corneal thickness; MD: Mean deviation; VFI: Visual field index; [§]unpaired t test, statistical significance level ≤ 0.05

Five patients had family history of glaucoma and four had family history of PDS. Ten patients had been diagnosed with 'primary open angle glaucoma' before referral to the hospital. All of them were taking anti-glaucoma medications at the time of evaluation for PDS. Only nine of the PDS patients had symptoms, which were mostly occasional blurred vision accompanied with heaviness of the affected eye and headache.

Out of 40 patients, thirty three patients (82.5%) had Krukenberg spindles in at least one of the eye, which were bilateral in 28 patients and unilateral in five patients. Six (one PDS and five PG) patients had traces of diffuse corneal endothelial pigmentation. One patient of PDS did not have any corneal endothelial pigmentation in both eyes [Table/Fig-3].

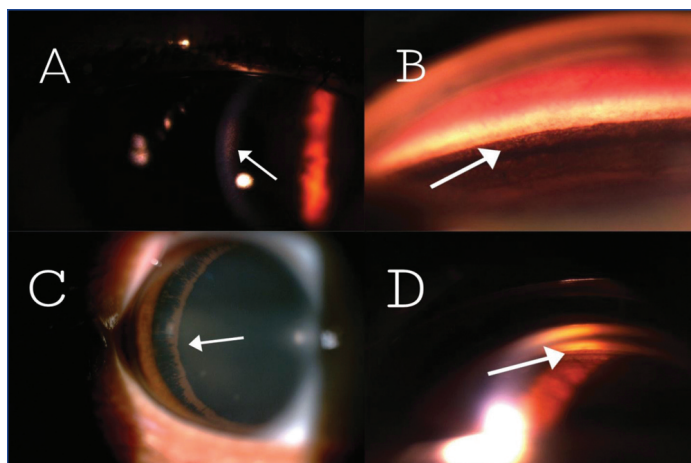
Variables	PDS	PG
Corneal endothelial pigmentation		
KS	14 (35%)	19 (47.5%)
DP	1 (2.5%)	5 (12.5%)
None	1 (2.5%)	-
TM pigmentation		
0 no pigment	-	-
1+ minimal	-	-
2+ mild	1 (2.5%)	-
3+moderate	9 (22.5%)	10(25%)
4+ intense	6 (15%)	14 (35%)
ITDs		
Traces	-	1 (2.5%)
Lenticular/zonular pig		
Traces	5 (12.5%)	2 (5%)
Grd 1	9 (22.5%)	5 (12.5%)
Grd 2	1 (2.5%)	6 (15%)
Grd 3	1 (2.5%)	10 (25%)
Grd 4	-	1 (2.5%)
Anterior Iris stromal pigment dusting		
Traces	-	2 (5%)
Mid-peripheral iris configuration		
Concave	2 (5%)	10(25%)
Flat	14 (35%)	14 (35%)

[Table/Fig-3]: Clinical findings of anterior segment in study patients.

KS: Krukenberg spindle; DP: Diffuse pigmentation; TM: Trabecular meshwork; ITD: Iris trans-illumination defect; Grd: Grade

Twelve (2 PDS and 10 PG) patients had concave mid-peripheral iris configuration and 28 (14 PDS and 14 PG) patients had flat mid-peripheral iris configuration. Only two patients (PG patients) had a trace cluster of pigment granules on inferior iris surface and no patient exhibited an obvious diffuse anterior iris stromal pigment granule dusting. Typical spoke-like radial ITDs were not observed in any of the patients [Table/Fig-3]. In one patient, the most myopic of the group with -24.75D spherical equivalent had, isolated short slit-like trans-illumination defects in iris crypts.

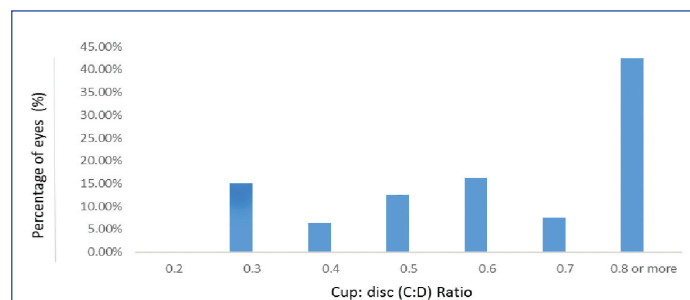
Homogeneous TM pigmentation was seen in all patients and Sampolesi's line was visualised at almost 360 degrees in all cases on gonioscopy [Table/Fig-4]. All study patients showed Zentmayer line (also known as Scheie's line). Zentmayer line represents pigment granule deposition on lens zonules or on posterior peripheral surface, which may be of different extent [Table/Fig-4].



A. Krukenberg spindle, B. TM Hyperpigmentation, C. Zentmayer's line, D. Sampaolesi line

[Table/Fig-4]: Clinical pictures of anterior segment findings.

On fundus examination 34 (42.5%) eyes had C:D ratio of 0.8 or more, 6 (7.5%) had C:D ratio of 0.7 and 40 (50%) eyes were having C:D ratio of 0.6 or less, as shown in [Table/Fig-5]. The average C:D ratio in all study patients was 0.667 ± 0.235 . The C:D ratio of PDS and PG patients, were 0.478 ± 0.134 and 0.793 ± 0.202 , respectively, ($p < 0.001$) [Table/Fig-2].



[Table/Fig-5]: Cup:disc (C:D) ratio distribution among eighty eyes of the study population.

Notably, 60% (24/40) patients, either in one or both eyes had glaucoma manifestations of secondary to PDS at the initial diagnosis. Seventeen of them were diagnosed as having PG in both eyes and seven patients were diagnosed with PG, unilaterally. Three patients had BCVA of Light Perception (LP) in one eye and two patients had no LP in one eye. Both eyes of one patient were having < 20 degrees of visual field on Humphrey perimetry, at initial examination.

DISCUSSION

The objective of the present study was to evaluate clinical characteristics of PDS and PG patients at a tertiary eye care center in Eastern Uttar Pradesh and it was found that, 82.5% of the study patients had Krukenberg spindles. In black patients, this percentage was 57.1% [8]. In our study, TM pigmentation was homogeneous and pigment granule deposition on posterior surface of lens and zonules were most common findings and these similar findings were also common among black population [8], while Spoke-like mid-peripheral ITDs were rarely found in the present study and Mid-peripheral iris concave configuration was common among 30% of the study patients. In a study done by Roberts DK et al., the black patients did not show obvious concave iris configuration rather showed flat peripheral iris configuration and deep anterior chamber depth. Trace cluster of pigment granules on inferior iris surface were identified in two of the forty (5%) study patients, but was not reported in black patients [8]. The white patients also have concave iris configuration, pigment deposition on zonules and/or on posterior lens surface [4,6,7,17]. The black patients are different from white patients in not having mid-peripheral radial ITDs [8-13].

Typical spoke-like radial ITDs were not detected in any of the study patient. Whilst the most myopic of the group with -24.75 D spherical equivalent, isolated short slit-like trans-illumination defects in iris crypts was observed in one (2.5%) patient.

The anterior iris stromal pigment granule dusting is not as common in black patients as compared to white patients. Trace cluster of pigment granules on inferior iris surface were identified in two out of the forty (5%) study patients, but was not reported in black patients.

The mean age of the study population was found to be 36.52 ± 8.91 years with 3.4:1 male to female ratio. No statistically significant difference in age ($p=1.0$) between PDS and PG patients was found. In both the groups, males were affected more than females. Qing G et al., reported that, mean age of the PDS patients was 35.5 ± 7.0 years (range, 22-49), with a 2:1 male-to-female ratio [18].

Age was significantly ($p < 0.0001$) lower and there were significantly ($p < 0.001$) more men than women in the group with PG compared with the group with primary open angle glaucoma [19].

The lack of ITDs in black PDS patients may be due to their dark irides [8,11,13]. The iris color of Indians is usually brown or dark brown, which results from heavy pigmentation in iris melanocytes and iris stroma by virtue of which they can block an IPE trans-illumination defect. The heavily pigmented irides in PDS/PG patients may also account for the lack of ITDs in PDS.

In the best of the author's knowledge, there has been no separate study conducted regarding clinical features of PDS/PG in patients of eastern Uttar Pradesh. In this study, it was found that study patients comprised of 1.98% (40 of 2012) of all outpatients in glaucoma specialty clinic of the hospital. Similar results were reported by Qing G et al., where PDS patients comprised 1.1% (18 of 1632) of all outpatients in glaucoma specialty clinic of Beijing [18]. This turned out to be much more common than we had imagined. The lack of typical ITDs in Indian PDS/PG patients may distract the attention of clinicians from suspecting PDS.

Ten study patients were diagnosed with primary open angle glaucoma before referral to the glaucoma clinic. Although, 82.5% (33 out of 40) were detected having Krukenberg spindle. It is subtle and hard to notice in some patients even under slit-lamp bio-microscopy because of the dark background of the highly pigmented iris, especially when the pigmentation remains minimal. The anterior iris stromal pigment granule dusting was absent in the majority of the study patients.

In the study, 60% (24/40) patients, had glaucoma manifestations of secondary to PDS at the initial diagnosis and 90% patients had raised initial IOP. Seventeen patients of them were diagnosed as having PG in both eyes and seven were diagnosed with PG unilaterally. Many PDS patients are not detected until they develop PG or visual symptoms due to incomplete and subtle spectrum of clinical signs in them. These percentages are much higher than white PDS patients [4,6,7,17,20].

In the present study, the mean refractive error of PDS and PG patients was -1.22 ± 1.49 and -5.10 ± 5.44 spherical equivalent, which was significantly more myopic in PG patients, ($p < 0.0085$). Gramer E et al., reported that greater the myopia, the earlier the onset of glaucoma [21]. Another study by Jonas JB et al., showed that refractive error was significantly more myopic ($p < 0.0001$) in the group with PG compared with the group with primary open angle glaucoma [19]. Moderate myopia (-3 to -4 D), is the most common refractive error in patients of PDS and PG [22].

The CCT of PG patients was significantly thinner than PDS patients. The baseline IOP in PDS and PG patients was 21.75 ± 8.27 mmHg and 35.85 ± 9.61 mmHg, respectively. There was a statistically significant high baseline IOP in PG patients than in PDS patients, at presentation, ($p = 0.0001$). Even patients with PDS and normal IOP, have been noted to have a tendency toward large spontaneous fluctuations in their IOP [23]. This diurnal IOP variability is postulated to be linked to circadian increases in aqueous outflow obstruction because of sudden pigmentary accumulations [24]. The C:D ratio of PG patients was significantly higher than PDS patients. This is because of more neuro-retinal rim thinning in PG patients. The C:D ratio changes more gradually in large discs [25].

Among both the group, PG group patients had significantly lower MD ($p = 0.0001$) and VFI ($p = 0.0003$). These patients can experience rapid deterioration of their visual function and often a more complicated course requiring additional surgeries [3].

Limitation(s)

The limitations of the present study were its retrospective nature, small sample size and for detection of ITDs, a standard slit-lamp examination in dark room was performed. Whereas use of an infrared imaging technique, which has demonstrated to be helpful in detecting ITDs in black patients [12,14], would have been more helpful to pick up iris defects in the Indian patients also.

CONCLUSION(S)

The clinical features of PDS in Indians are almost similar to that of blacks. At the time of initial diagnosis of PDS, 82.5% of the patients had Krukenberg spindle and 60% of patients (24 of 40) had PG. All forty patients had involvement of both eyes either as PDS or PG. PDS patients with normal optic disc and visual field and raised IOP, should be started prophylactic treatment. Patients with PDS and PG need to be monitored more closely. Thus, the finding of PDS in Indians should alert the ophthalmologist to look for glaucoma at the initial examination.

REFERENCES

- [1] Sugar HS, Barbour FA. Pigmentary glaucoma: A rare clinical entity. *Am J Ophthalmol.* 1949;32:90-92.
- [2] Campbell DG. Pigmentary dispersion and glaucoma: A new theory. *Arch Ophthalmol.* 1979;97:1667-72.
- [3] Yang JW, Sakiyalak D, Krupin T. Pigmentary glaucoma. *J Glaucoma.* 2001;10:S30-32.
- [4] Ritch R, Steinberger D, Liebmann JM. Prevalence of pigment dispersion syndrome in a population undergoing glaucoma screening. *Am J Ophthalmol.* 1993;115:707-10.
- [5] Scheie HG, Fleischhauer HW. Idiopathic atrophy of the epithelial layers of the iris and ciliary body. *Arch Ophthalmol.* 1958;59:216-88.
- [6] Scheie HG, Cameron JD. Pigment dispersion syndrome: A clinical study. *Br J Ophthalmol.* 1981;65:264-69.
- [7] Gillies WE, Brooks AM. Clinical features at presentation of anterior segment pigment dispersion syndrome. *Clin Experiment Ophthalmol.* 2001;29:125-27.
- [8] Roberts DK, Chaglasian MA, Meetz RE. Clinical signs of the pigment dispersion syndrome in blacks. *Optom Vis Sci.* 1997;74:993-1006.
- [9] Semple HC, Ball SF. Pigmentary glaucoma in the black population. *Am J Ophthalmol.* 1990;109:518-22.
- [10] Roberts DK, Flynn M, Gable EM. Anterior chamber angle anomalies associated with signs of pigment dispersion in a group of black probands and their first-degree relatives. *Optom Vis Sci.* 2001;78:133-41.
- [11] Roberts DK, Wernick MN. Infrared imaging technique may help demonstrate iris transillumination defects in blacks who show other pigment dispersion syndrome clinical signs. *J Glaucoma.* 2007;16(5):440-47.
- [12] Roberts DK, Winters JE, Castells DD, Teitelbaum BA, Alexander CC. A cross-sectional study of Krukenberg spindles and pigmented lens striae in a predominantly black population. *J Glaucoma.* 2005;14:57-63.
- [13] Roberts DK, Chaglasian MA, Meetz RE. Iris transillumination defects in the pigment dispersion syndrome as detected with infrared videography: A comparison between a group of blacks and a group of nonblacks. *Optom Vis Sci.* 1999;7:545-49.
- [14] Patrianakos TD, Pasquale LR. Pigment dispersion syndrome and pigmentary glaucoma. In: Daniel M. Albert, editor. *Principles and Practice of Ophthalmology*, 3rd ed. Philadelphia: Saunders Elsevier; 2008. Pp. 2601.
- [15] Tandon A, Zhang Z, Fingert JH, Kwon YH, Wang K, Alward WLM. The heritability of pigment dispersion syndrome and pigmentary glaucoma. *Am J Ophthalmol.* 2019;202:55-61.
- [16] Gazzard G, Rajan A, Foster P, Barton K. Gonioscopy. In: R Ramakrishnan, editor. *Diagnosis and Management of Glaucoma*, 1st ed. New Delhi: Jaypee Brothers Medical Publishers; 2013. Pp. 135.
- [17] Siddiqui Y, Ten Hulzen RD, Cameron JD, Hodge DO, Johnson DH. What is the risk of developing pigmentary glaucoma from pigment dispersion syndrome. *Am J Ophthalmol.* 2003;135:794-99.
- [18] Qing G, Wang N, Tang X, Zhang S, Chen H. Clinical characteristics of pigment dispersion syndrome in Chinese patients. *Eye.* 2009;23:1641-46.
- [19] Jonas JB, Dichtl A, Budde WM, Lang P. Optic disc morphology in pigmentary glaucoma. *Br J Ophthalmol.* 1998;82:875-79.
- [20] Lichter PR, Shaffer RN. Diagnostic and prognostic signs in pigmentary glaucoma. *Trans Am Acad Ophthalmol Otolaryngol.* 1970;74:984-98.
- [21] Gramer E, Thiele H, Ritch R. Risk Factors in Pigmentary Glaucoma. In: *Glaucoma Update VI*. Springer, Berlin, Heidelberg. 2000.
- [22] Lord FD, Pathanapitoon K, Mikelberg FS. Keratometry and axial length in pigment dispersion syndrome: A descriptive case-control study. *J Glaucoma.* 2001;10(5):383-85.
- [23] Linner E. The association of ocular hypertension with the exfoliation syndrome, the pigmentary dispersion syndrome and myopia. *Surv Ophthalmol.* 1980;25:145-47.

[24] Mastropasqua L, Carpineto P, Ciancaglini M, Gallenga PE. A 12-month, randomized, doublemasked study comparing latanoprost with timolol in pigmentary glaucoma. *Ophthalmology* 1999;106:550-55.

[25] Garway-Heath DF, Ruben ST, Viswanathan A, Hitchings RA. Vertical cup/disc ratio in relation to optic disc size: its value in the assessment of the glaucoma suspect. *Br J Ophthalmol.* 1998;82(10):1118-24.

PARTICULARS OF CONTRIBUTORS:

1. Associate Professor, Department of Ophthalmology, Regional Institute of Ophthalmology, Sitapur, Uttar Pradesh, India.
2. Associate Professor, Department of Ophthalmology, Regional Institute of Ophthalmology, Sitapur, Uttar Pradesh, India.
3. Assistant Professor, Department of Ophthalmology, Regional Institute of Ophthalmology, Sitapur, Uttar Pradesh, India.
4. Consultant, Department of Ophthalmology, Regional Institute of Ophthalmology, Sitapur, Uttar Pradesh, India.
5. Professor, Department of Ophthalmology, Regional Institute of Ophthalmology, Sitapur, Uttar Pradesh, India.
6. Consultant, Department of Ophthalmology, Regional Institute of Ophthalmology, Sitapur, Uttar Pradesh, India.
7. Consultant, Department of Ophthalmology, Regional Institute of Ophthalmology, Sitapur, Uttar Pradesh, India.
8. Optometrist, Department of Ophthalmology, Regional Institute of Ophthalmology, Sitapur, Uttar Pradesh, India.

NAME, ADDRESS, E-MAIL ID OF THE CORRESPONDING AUTHOR:

Rahul Bhardwaj,
Sitapur Eye Hospital Campus, Civil Lines, Sitapur, Uttar Pradesh, India.
E-mail: rahulbhardwaj227@gmail.com

PLAGIARISM CHECKING METHODS: [\[Jan H et al.\]](#)

- Plagiarism X-checker: Sep 29, 2020
- Manual Googling: Nov 09, 2020
- iThenticate Software: Dec 12, 2020 (22%)

ETYMOLOGY: Author Origin

AUTHOR DECLARATION:

- Financial or Other Competing Interests: None
- Was Ethics Committee Approval obtained for this study? Yes
- Was informed consent obtained from the subjects involved in the study? Yes
- For any images presented appropriate consent has been obtained from the subjects. Yes

Date of Submission: **Sep 26, 2020**

Date of Peer Review: **Oct 19, 2020**

Date of Acceptance: **Nov 10, 2020**

Date of Publishing: **Dec 15, 2020**