

# Hereditary Bisalbuminemia in Sjögren's Syndrome and Rheumatoid Arthritis

SERDAL UGURLU<sup>1</sup>, BUGRA HAN EGELI<sup>2</sup>, IBRAHIM MURAT BOLAYIRLI<sup>3</sup>

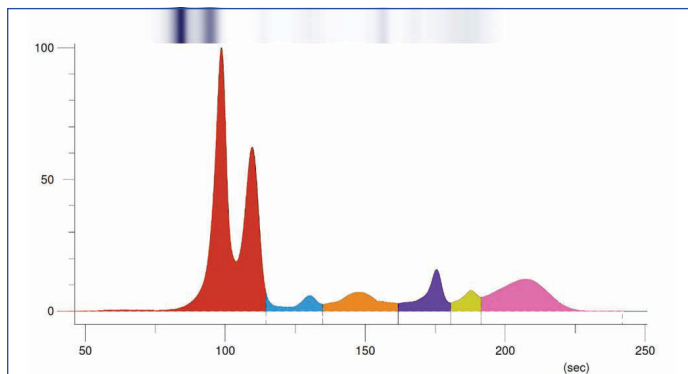
## ABSTRACT

Bisalbuminemia is rare finding of bifid albumin bands in serum electrophoresis. The protein abnormality can be sporadic and inherited. So far, this albumin variant was not found to cause or coexist with a specific pathology. This is a case of bisalbuminemia in 43-year-old female patient with a past medical history of Rheumatoid Arthritis (RA) and Sjogren's Syndrome (SS). Similar electrophoresis findings were seen in two siblings of the patient. Rheumatology focused work-up of the family was negative. We could not find an association between this blood protein variant and the patient's rheumatologic condition. Bisalbuminemia should not be a concern to the rheumatologist as it does not hint towards pathology.

## CASE REPORT

A 43-year-old female patient presented with the chief complaint of dry eyes and dry mouth. She has a five-year-long past medical history of RA treated with oral hydroxychloroquine.

Following her rheumatologic clinical work-up, she was diagnosed with SS. Anti-Sjögren's-syndrome-related antigen A autoantibodies (Anti-SSA) was positive. Anti-Sjögren's-syndrome-related antigen B autoantibodies (Anti-SSB) was negative. Serum Antinuclear Antibody (ANA) level was positive. The serum electrophoresis showed bicuspid pattern in the albumin fraction [Table/Fig-1].



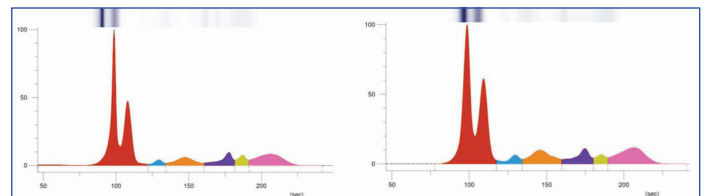
**[Table/Fig-1]:** The serum electrophoresis of the patient; \*Fractions in their order and color; Red: Albumin, Blue: Alpha 1, Orange: Alpha 2, Purple: Beta 1, Yellow: Beta 2, Pink: Gamma.

Her family history was non-contributory in terms of any rheumatologic disorders, blood pathologies or malignancies. Similar electrophoresis results were seen in the two sisters of the patient [Table/Fig-2]. In addition to focused history and physical exam, the rheumatologic work-up of the sisters has not shown the presence of any positive findings including Rheumatoid Factor (RF), ANA, Anti-SSA, Anti-SSB, and acute phase response. The patient was counselled and managed conservatively for good oral hygiene and use of artificial tears. She was guided for proper exercise and rest to maintain body flexibility. As the syndrome can only be controlled, she was followed-up for the same.

## DISCUSSION

Bisalbuminemia is an albumin abnormality characterised by the duplication of the albumin in the serum electrophoresis. Besides albumin, other serum protein fractions alpha-1, alpha-2, beta, and gamma are not altered in their particular order. Whether acquired or

**Keywords:** Albumin variant, Autoimmunity, Protein electrophoresis



**[Table/Fig-2]:** The serum electrophoresis of the two sisters; \*Fractions in their order and colour; Red: Albumin, Blue: Alpha 1, Orange: Alpha 2, Purple: Beta 1, Yellow: Beta 2, Pink: Gamma.

inherited, has an estimated frequency of 1:10000 to 1:1000 [1,2]. The finding has been reported in various case reports in conditions of Diabetes Mellitus, Hypothyroidism, Alzheimer's disease, multiple myeloma, nephrotic syndrome, digestive adenocarcinoma [1,3-6]. A co-existence of hereditary bisalbuminemia and Sjogren-Larsson syndrome was reported in three siblings [7].

Serum electrophoresis is frequently ordered in autoimmune conditions to eliminate any pathologies associated with an abnormal gamma fraction such as polyclonal or monoclonal gammopathies. In the present case, we came across the abnormal albumin fraction in this screening process. As the brief literature review showed the present cases of an inherited nature, the family work-up was warranted.

To best of our knowledge, bisalbuminemia in rheumatologic conditions has not been reported to date. As none of the two sisters of the patient have any rheumatologic complaints or diagnoses, it is challenging to find an association of this albumin variant and autoimmune conditions.

## CONCLUSION(S)

Further electrophoresis findings might be intriguing to search for more, in terms of a scientific explanation, the present case, after complete investigations and work-up, seems nothing more than a protein variant. Despite published a few times in the medical literature, a solid association that pinpoints towards clinical significance is absent. Even though, further analysis on the antigenicity of these two albumin variants can be scientifically legitimised, this finding should not be a concern to the clinician as it does not hint towards a pathology.

## REFERENCES

- [1] Shetty JK, Prakash M, Gopalakrishna K. Bisalbuminemia in an adult male with Alzheimer's disease. *Indian J Med Sci.* 2007;61(6):356-57.
- [2] Kim YH, Lee YW, Jeon BR, Lee YK, Shin HB, Kang DH, et al. Clinical characteristics and ALB gene mutation analysis of Korean patients with bisalbuminemia. *Korean J Lab Med.* 2010;30(3):307-11.

- [3] Shetty JK, Maradi R, Prabhu K, Bhat G. Bisalbuminemia in a hypothyroid patient with diabetes: A case report. *J Clin Diagn Res.* 2015;9(9):BD01-BD2.
- [4] Hajoui FZ, Biaz A, Zouiten L, Mechtani S, Dami A, Bouhsain S, et al. A case of bisalbuminemia in a patient with digestive adenocarcinoma. *Ann Biol Clin (Paris).* 2015;73(2):190-94.
- [5] Hoang MP, Baskin LB, Wians FH Jr. Bisalbuminuria in an adult with bisalbuminemia and nephrotic syndrome. *Clin Chim Acta.* 1999;284(1):101-07.
- [6] Pola V, Tichý M. Bisalbuminemia. Critical review and report of a case of an acquired form in a myeloma patient. *Folia Haematol Int Mag Klin Morphol Blutforsch.* 1985;112(1):208-18.
- [7] Maia M. Sjögren-Larsson syndrome in two sibs with peripheral nerve involvement and bisalbuminaemia. *J Neurol Neurosurg Psychiatry.* 1974;37(12):1306-15.

**PARTICULARS OF CONTRIBUTORS:**

1. Professor, Department of Internal Medicine, Cerrahpasa, Faculty of Medicine, Istanbul, Turkey.
2. Department of Internal Medicine, Cerrahpasa, Faculty of Medicine, Istanbul, Turkey.
3. Professor, Department of Biochemistry, Cerrahpasa Faculty of Medicine, Istanbul, Turkey.

**NAME, ADDRESS, E-MAIL ID OF THE CORRESPONDING AUTHOR:**

Dr. Serdal Ugurlu,  
Cerrahpasa, Faculty of Medicine, Istanbul, Turkey.  
E-mail: serdalugurlu@gmail.com

**PLAGIARISM CHECKING METHODS:** [\[Jan H et al.\]](#)

- Plagiarism X-checker: Sep 10, 2020
- Manual Googling: Jan 13, 2021
- iThenticate Software: Jan 14, 2021 (2%)

**ETYMOLOGY:** Author Origin**AUTHOR DECLARATION:**

- Financial or Other Competing Interests: None
- Was informed consent obtained from the subjects involved in the study? Yes
- For any images presented appropriate consent has been obtained from the subjects. NA

Date of Submission: **Sep 06, 2020**Date of Peer Review: **Nov 26, 2020**Date of Acceptance: **Jan 14, 2021**Date of Publishing: **May 01, 2021**