

COVID-19 And Malaria Co-infection Management in Post Liver Transplant- A Case Report

SANIYA WASIM SHAIKH¹, SAMPATHKUMAR MAHADEVAPPA MAHENDRAKAR²,
SULAIMAN SADRUDDIN LADHANI³, AZIZULLAH HAFIZULLAH KHAN⁴



ABSTRACT

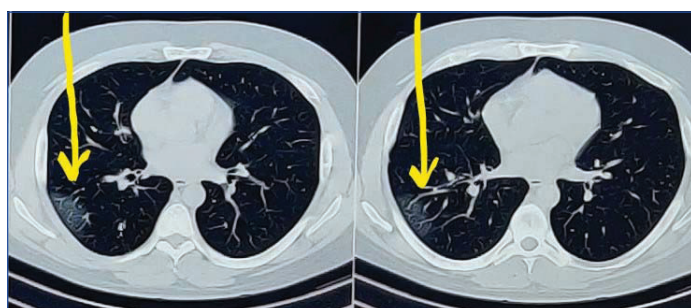The current pandemic of Coronavirus Disease 2019 (COVID-19) has posted unprecedented challenges to the community of clinicians in various aspects, ranging from prompt and early diagnosis to preventing complications. What makes the challenge even tougher is to be able to distinguish between diseases presenting with similar complaints, especially in tropical regions, and yet be able to treat judiciously and give a targeted treatment. The level of difficulty escalates when a patient with Solid-Organ Transplant (SOT) on immunosuppressive therapy presents to the clinician as suspected COVID-19 along with a co-infection. Incidences like these carry an increased burden of higher morbidity and mortality, with or without immunosuppression, if not timely diagnosed and judiciously treated, thus heralding the need to be vigilant in the current pandemic. Thus, to the best of our knowledge, this was the first documented and successfully treated case of a patient with past history of Liver Transplant (LT) with Severe Acute Respiratory Syndrome Coronavirus-2 (SARS-CoV-2) pneumonia with co-existing *Plasmodium vivax* (*P.vivax*) malaria.

Keywords: Coronavirus disease 2019, Immunosuppressive therapy, *Plasmodium vivax*, *Plasmodium vivax* malaria, Working challenges

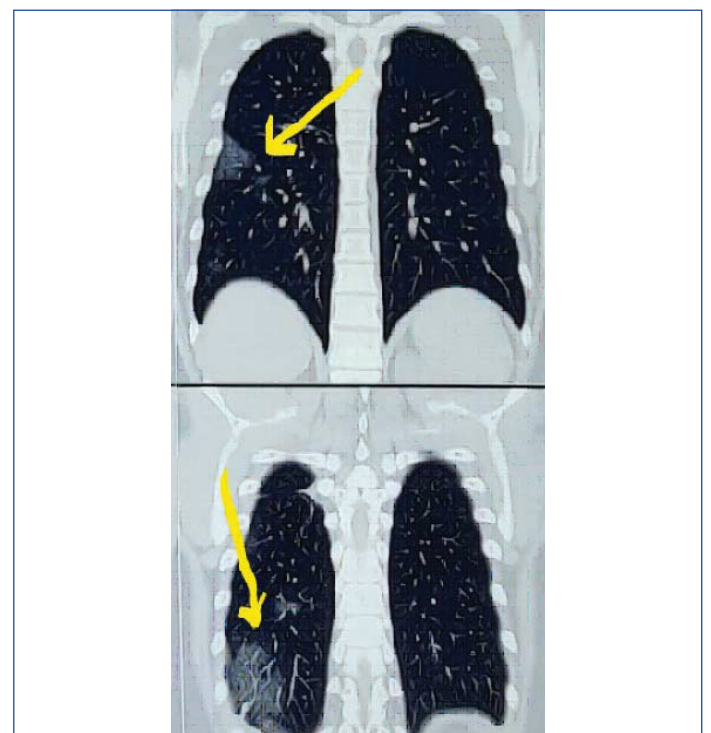
CASE REPORT

A 38-year-old male with a body mass index of 29.4 kg/m², a case of hypertension, remote smoker and a history of orthotopic LT for cryptogenic liver disease seven years ago, on regular oral medications with amlodipine, aspirin, tacrolimus, prednisolone and mycophenolate mofetil and past history of pulmonary tuberculosis two years back having completed anti tubercular therapy, presented to emergency medical services with acute onset febrile illness, throat irritation, loss of sense of smell, lethargy since five days. On admission, patient had a heart rate of 110 per minute, temperature 102°F, he was in mild respiratory distress, non-invasive blood pressure of 130/90 mmHg, respiratory rate of 22 breaths per minute and oxygen saturation of 93% on room air. Bilateral lung auscultation revealed normal breath sounds with unremarkable cardiovascular and other systems. With the current pandemic situation, high clinical suspicion of COVID-19 was made. Nasopharyngeal swab for SARS CoV-2 was tested. RT-PCR for SARS CoV-2 was positive. Chest roentgenogram revealed no significant abnormalities. Computed Tomography (CT) of the chest revealed patchy areas of ground glass opacities noted in right lower lobe and left upper lobe, CT severity score 3/25 [Table/Fig-1,2]. His blood investigations revealed haemogram within normal limits, elevated serum bilirubin 2.3 mg/dL, while other liver enzymes and coagulation profile were in the normal range. High levels of D-dimer 5000 mg/dL, C-reactive protein 166 mg/L, ferritin levels 1721 ng/mL, serum lactate dehydrogenase 658 U/L and serum

creatinine 1.86 mg/dL [Table/Fig-3]. Electrocardiogram showed sinus tachycardia, arterial blood gas analysis on room air revealed mild hypoxemia. Patient was treated with supplemental oxygen via nasal prongs at four liters per minute, intravenous (IV) ceftriaxone, dexamethasone, remdesivir, subcutaneous low molecular weight heparin, while his immunosuppressive medication tacrolimus was continued and mycophenolate mofetil was kept on hold. Bed-side ultrasonography of abdomen revealed no abnormalities. However, the patient continued to have high grade fever with chills and rigors with increasing oxygen requirement. Serial haemogram revealed



[Table/Fig-1]: Computed tomography axial view of chest.



[Table/Fig-2]: Coronal view: Computed Tomography (CT) scan of chest, arrow shows few patchy areas of ground glass opacities with interlobular septal thickening scattered in right lower lobe and left upper lobe.

Investigations	(Reference-units)	Days of hospital stay				
		Day 1	Day 2	Day 3	Day 4	Day 5
Haemoglobin (gm/dL)	13-17	15.2	15	14	13.5	14.5
Total leucocyte counts (per cumm)	4000-10000	6000	6030	14160	8530	8000
Platelets counts (per cumm)	150000-400000	159000	75000	52000	98000	118000
Aspartate aminotransferase (U/L)	0-37	48.8	59.5	75	40.1	32
Alanine aminotransferase (U/L)	0-40	50	53	55	45.8	38
Total bilirubin (mg/dL)	0-1	2.3	1.3	1	0.80	
Direct bilirubin (mg/dL)	0.1-0.3	1	0.5	0.5		
D-dimer (mg/dL)	0-400	5000		1030		756
C-reactive protein (mg/L)	<5	166		184.48		54
Serum lactate dehydrogenase (U/L)	230-460	658		620		500
Ferritin (ng/ mL)	30-400		1721			800
Serum creatinine (mg/dL)	0.6-1.2	1.86		1.33		0.9

[Table/Fig-3]: Serial blood investigations and trends; peripheral smear for malarial parasites (thick and thin smear) showed ring and schizont forms of *P.vivax*

falling trend in platelets counts and elevated inflammatory markers. Subsequently, on haemogram and peripheral smear examination (thick and thin smear) showed ring and schizont forms of *P.vivax* which was confirmed by rapid malarial antigen test which was positive for *P.vivax*. Serum tacrolimus levels were within normal limits. Glucose-6-Phosphate Dehydrogenase activity (G6PD) was normal and his glycaemic control was adequate. The patient was then initiated on IV artesunate 2.4 mg/kg at 0, 12, 24 and 48 hours. He gradually improved and became symptomatically better. Subsequent serial blood investigations showed normalising platelet counts, inflammatory markers, renal and liver function tests. The patient was eventually discharged on primaquine, along with his other regular medications. He was advised home quarantine for one week and rehabilitation. On follow up after four weeks he was clinically stable and symptom free.

DISCUSSION

The COVID-19 has posed extraordinarily unparalleled challenges to health care workers. Towards the end of 2019, Wuhan-China, reported multiple cases of lower respiratory tract infection with clinical features similar to viral pneumonia, the cause of which was later identified as 2019 novel coronavirus (2019 nCoV) [1]. Globally, until mid February 2021, there have been 108,579,352 confirmed cases of COVID-19, including 2,396,308 deaths reported by World Health Organisation (WHO) with India having 10,916,589 confirmed cases and 155,732 deaths [2]. The clinical features of COVID-19 includes fever with or without chills and rigors, associated with cough predominantly dry, pleuritic chest pain, constitutional symptoms of bodyache, generalised fatigue and respiratory distress in severe cases while some patients may present with multisystem manifestations [1,3]. In recent times, studies have been done which bring our attention to the possibility of co infections in COVID-19 with a variety of pathogens [3,4]. The risk of contracting COVID-19 in post SOT patients is variable with pre-existing co morbidities and immunosuppressed status [5]. The world wide estimated data provided by WHO is 229 million cases of malaria in 2019 with an estimated death of 4,09,000 attributed to malaria [6]. Despite adoption of national programmes for prevention and control of malaria, it continues to put a burden on the socioeconomic and healthcare system [3,7]. This makes it essential to rule out the

common endemic diseases, if the patient presents with symptoms overlapping in various diseases in order to prevent misdiagnosis or under-diagnosis.

Liver enzyme derangements have been very often noticed in patients of COVID-19, but the degree of derangement depends upon the severity of the disease [8]. LT patients on immune suppression therapy are at a greater risk of contracting COVID-19 but the incidence of mortality has not been widely recorded and there is very little data regarding management of LT patients with COVID-19 [8]. As reported in a study done by Fix OK et al., in post LT patient with deranged liver biochemistry, depending upon the severity of the disease it is required to continue with immunosuppressive medications in modified dosages, while off-label therapies should be continued for COVID-19 but simultaneously monitoring liver biochemistry [9]. It has been postulated in a case series report done by Patrono D et al., that increased Immunosuppression has a high tendency to delay viral clearance, thus further necessitating the need for modifying Immunosuppression therapy [10]. In a report by Bhoori S et al., 3 of 111 patients of LT with BMI >28, receiving antihypertensive drugs, with dyslipidemia and diabetes mellitus, died within a few weeks of developing SARS-CoV-2 pneumonia [11] while Colmenero J et al., reported 18% mortality in LT patients with SARS-CoV-2 pneumonia requiring ICU [12]. The preponderance of mortality substantially depends upon the pre-existing co-morbidities, as reported by Bhoori S et al., and Lee BT et al., [11,13].

It was observed that the patient presented with a classical presentation of COVID-19 with evidence of pulmonary involvement on CT along with blood investigations of elevated inflammatory markers, thus supporting the provisional diagnosis of SARS-CoV-2 pneumonia, the treatment for which was initiated promptly, albeit, the treatment regimen for the same is undefined and continues to be in trial. He was treated with RNA polymerase inhibitor-remdesivir since it has shown to cause inhibition of SARS-CoV-2 in human bronchial epithelial cell and because of its property of minimal interaction with tacrolimus, making it preferable over lopinavir/ritonavir [14,15]. However, regardless of appropriate treatment, he was persistently symptomatic with rapidly increasing inflammatory markers, derangements in haemogram and liver function tests, which instituted the suspicion of co infections prompting the use of combination therapy. Even though there is limited data on use of remdesivir and artesunate combination in post LT COVID-19 patients with malaria, the tolerated both under cautious monitoring.

CONCLUSION(S)

With the above case report it is suggested that when a patient presents with a clinical picture which is similar in a large spectrum of diseases, clinicians should not limit their investigations and approach to the extent of current pandemic only, taking into consideration the possibilities of other tropical diseases. Also, in a patient of SOT, on immunosuppressive drugs, the need to modify immunosuppressive medicines depends upon the clinical profile of the patient. Conclusively, a holistic approach in clinical assessment, timely diagnosis along with targeted treatment, if provided to the patient can help prevent morbidity and mortality.

REFERENCES

- [1] Huang C, Wang Y, Li X, Ren L, Zhao J, Hu Y, et al. Clinical features of patients infected with 2019 novel coronavirus in Wuhan. China. 2020;395(10223):497-506.
- [2] World Health Organisation. COVID 19 live updates. <https://covid19.who.int/>
- [3] Sardar S, Sharma R, Alyamani TY, Aboukamar M. COVID-19 and Plasmodium vivax malaria co-infection. IDCases. 2020;21:e00879.
- [4] Lai CC, Wang CY, Hsueh PR. Co-infections among patients with COVID-19: The need for combination therapy with non-anti-SARS-CoV-2 agents? Journal of Microbiology, Immunology and Infection. 2020 May 23.
- [5] Fishman JA, Roberts MB, Zhang EW, Kumar D, Hirsch HH, Maggiore U. Case 29-2020: A 66-year-old man with fever and shortness of breath after liver transplantation. New England Journal of Medicine. 2020;383(12):1168-80.

- [6] WHO. Malaria. World Health Organisation Fact Sheet. Updated 30 November 2020. Available: <http://www.who.int/news-room/factsheets/detail/malaria/>
- [7] Kumar A, Valecha N, Jain T, Dash AP. Burden of malaria in India: Retrospective and prospective view. *The American Journal of Tropical Medicine and Hygiene*. 2007;77(6_Suppl):69-78.
- [8] Niknam R, Malek-Hosseini SA, Hashemieh SS, Dehghani M. COVID-19 in liver transplant patients: Report of 2 cases and review of the literature. *International Medical Case Reports Journal*. 2020;13:317.
- [9] Fix OK, Hameed B, Fontana RJ, Kwok RM, McGuire BM, Mulligan DC, et al. Clinical best practice advice for hepatology and liver transplant providers during the COVID-19 pandemic: AASLD expert panel consensus statement. *Hepatology*. 2020;72(1):287-304.
- [10] Patrono D, Lupo F, Canta F, Mazza E, Mirabella S, Corcione S, et al. Outcome of COVID-19 in liver transplant recipients: A preliminary report from Northwestern Italy. *Transplant Infectious Disease*. 2020;22(5):e13353.
- [11] Bhoori S, Rossi RE, Citterio D, Mazzaferro V. COVID-19 in long-term liver transplant patients: Preliminary experience from an Italian transplant centre in Lombardy. *The Lancet Gastroenterology & Hepatology*. 2020;5(6):532-33.
- [12] Colmenero J, Rodríguez-Perálvarez M, Salcedo M, Arias-Milla A, Muñoz-Serrano A, Graus J, et al. Epidemiological pattern, incidence, and outcomes of COVID-19 in liver transplant patients. *Journal of Hepatology*. 2020;74(1):148-55.
- [13] Lee BT, Perumalswami PV, Im GY, Florman S, Schiano TD, Da BL, et al. COVID-19 in liver transplant recipients: An initial experience from the US epicenter. *Gastroenterology*. 2020;159(3):1176-78.
- [14] Jamir I, Lohia P, Pande RK, Setia R, Singhal AK, Chaudhary A. Convalescent plasma therapy and remdesivir duo successfully salvaged an early liver transplant recipient with severe COVID-19 pneumonia. *Annals of Hepato-biliary-pancreatic Surgery*. 2020;24(4):526.
- [15] Laracy JC, Verna EC, Pereira MR. Antivirals for COVID-19 in solid organ transplant recipients. *Current Transplantation Reports*. 2020:1-1.

PARTICULARS OF CONTRIBUTORS:

1. Postgraduate Trainee in Tropical Medicine and Health, Department of Internal Medicine, Prince Aly Khan Hospital, Mumbai, Maharashtra, India.
2. Consultant Intensivist and Emergency Head, Department of Internal Medicine, Prince Aly Khan Hospital, Mumbai, Maharashtra, India.
3. Head of Department, Department of Chest Medicine, Prince Aly Khan Hospital, Mumbai, Maharashtra, India.
4. Consultant Physician and Intensivist, Department of Internal Medicine, Prince Aly Khan Hospital, Mumbai, Maharashtra, India.

NAME, ADDRESS, E-MAIL ID OF THE CORRESPONDING AUTHOR:

Dr. Sulaiman Sadruddin Ladhani,
Head of Department, Department of Chest Medicine, Prince Aly Khan Hospital,
Aga Hall, Nesbit Road, Mazgaon, Mumbai-400010, Maharashtra, India.
E-mail: drsladhani@gmail.com

PLAGIARISM CHECKING METHODS: [\(Jan H et al.\)](#)

- Plagiarism X-checker: Feb 20, 2021
- Manual Googling: Mar 18, 2021
- iThenticate Software: Mar 22, 2021 (7%)

ETYMOLOGY: Author Origin**AUTHOR DECLARATION:**

- Financial or Other Competing Interests: None
- Was informed consent obtained from the subjects involved in the study? Yes
- For any images presented appropriate consent has been obtained from the subjects. Yes

Date of Submission: **Feb 19, 2021**
Date of Peer Review: **Mar 01, 2021**
Date of Acceptance: **Mar 19, 2021**
Date of Publishing: **May 01, 2021**