

# Tetrasomy 8 in Haematological Malignancies-A Case Series

NEERAJA KOPPAKA<sup>1</sup>, SAYLI KALE<sup>2</sup>, DEEPAK CHAVAN<sup>3</sup>, SANDHYA KANDOOR<sup>4</sup>, USHANG KATE<sup>5</sup>, ANURITA PAIS<sup>6</sup>

## ABSTRACT

Tetrasomy 8, a rare genetic abnormality in haematological disorders is associated with Acute Myeloid Leukaemia (AML), Myelodysplastic Syndrome, Myeloproliferative Neoplasms and Acute Non Lymphocytic Leukaemia. It may be found as a sole chromosomal abnormality or co-exist with Trisomy 8. Tetrasomy 8 has shown to have proliferative advantage and aggressive clinical course with lower survival rates. Four cases of Tetrasomy 8 were reported in present series, of which one case showed Tetrasomy 8 as a sole chromosomal abnormality, two cases with its co-existence with Trisomy 8 and one case with complex rearrangement of chromosome 8. Trisomy 8 as a sole abnormality is associated with intermediate prognosis; hence the aggressive behaviour of the disease with Tetrasomy 8 can be attributed to increase in gene dosage of extra chromosome 8. The fourth case of AML with monocytic differentiation showed complex karyotype with presence of two isochromosomes 8, resulting in five copies for long arm of chromosome 8. This demonstrates presence of crucial genes for leukemogenesis in 8q region. From various studies, it is evident that the role of Tetrasomy 8 in poor prognosis and role of associated genes in leukemogenesis needs further investigation on molecular deregulation mechanisms with biologic and clinical consequences. Building up on rare abnormalities by this study would help in a better understanding of the disease with appropriate classification and ultimately can lead to an effective clinical management.

**Keywords:** Acute leukaemia, Chromosomes, Fluorescence in-situ hybridisation myelodysplastic syndrome, Survival

## INTRODUCTION

Tetrasomy 8 is a rare cytogenetic abnormality in Haematological disorders associated with all subtypes of AML predominantly the monocytic lineage, Myelodysplastic Syndrome (MDS) and Myeloproliferative Neoplasms (MPN). Usually, complex multiple chromosomal abnormalities are associated with poor prognosis, however mere presence of sole numerical abnormality of Tetrasomy 8 can also lead to poor prognosis. The overall median survival of patients with Tetrasomy 8 in Haematological malignancies has been estimated at 6-7 months [1]. Among the numerical abnormalities, Tetrasomy 8 is one of the most common rare genetic abnormalities with only 33 cases documented till date [2].

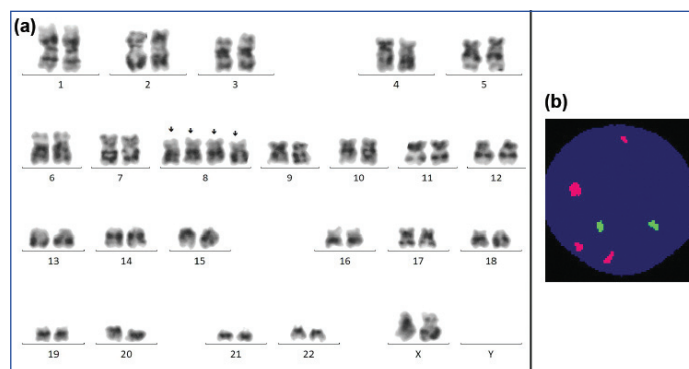
Karyotyping and fluorescence in-situ hybridization (FISH) evaluation of four cases with Tetrasomy 8 are reported in this study. Tetrasomy 8 clone is observed mostly with presence of Trisomy 8 as detected by either conventional cytogenetics and/or FISH technique. Tetrasomy 8 as a sole numerical abnormality was observed in Case 1 with MDS, while Case 2 and 3 revealed Tetrasomy 8 as a subclonal evolution from a pre-existing clone of Trisomy 8. In Case 3, Trisomy 8 was detected only after application of FISH technique using locus specific probe for Runt related Transcription factor 1 (RUNX1T1) as it was a small clone. In Case 4, partial pentasomy for the long arm of chromosome 8 was observed as a result of isochromosome formation.

## CASE SERIES

### Case 1

A 65-year-old female patient with clinical suspicion of MDS, with an intermittent high grade fever, weakness, weight loss, absence of lymphadenopathy, absence of blasts, presence of dysplasia and bone pains with sternal tenderness was referred for karyotyping and FISH. Her haemoglobin was low (8.2 mg/dL), leukopenia (2250/mm<sup>3</sup>), 5% neutrophils, 92% lymphocytes,

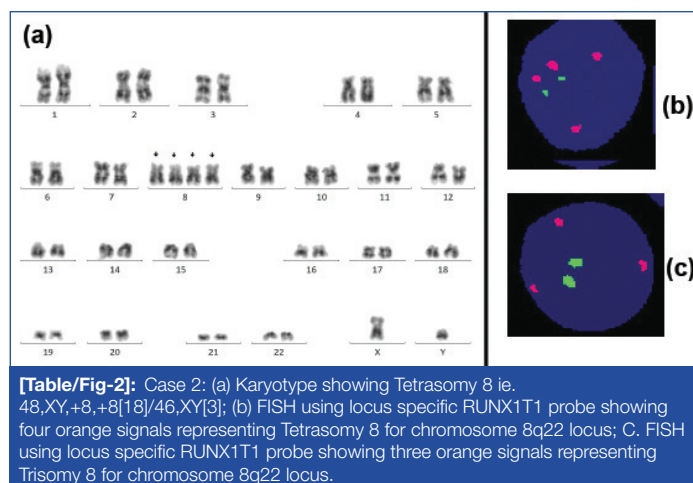
high absolute neutrophil count 20%, high platelet count 58000/mcL of blood, normal mean corpuscular volume 97.3 fl, mean corpuscular haemoglobin 31.8 picograms/cell and mean corpuscular haemoglobin concentration (32.7 g/dL). Karyotyping revealed Tetrasomy 8 in 30% of the cells, which is represented as 48,XX, +8, +8 (6)/46, XX(14) according to International System for Human Cytogenomic Nomenclature (ISCN) [3]. FISH analysis using probes for MDS associated recurrent genetic markers showed negative status for deletions of 5q33-34,7q31 and 20q12. Fifteen percent of cells showed Tetrasomy 8 represented by four orange signals for 8q22 locus and absence of trisomy 8 was observed [Table/Fig-1].



**[Table/Fig-1]:** Case 1: (a) Karyotype showing Tetrasomy 8 i.e. 48, XX, +8, +8 [6]/46, XX [14]; (b) FISH using locus specific RUNX1T1 probe showing four orange signals representing Tetrasomy 8 for chromosome 8q22 locus.

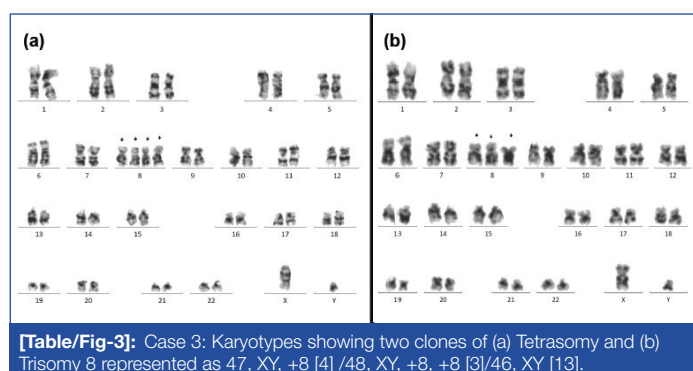
### Case 2

Chromosomal analysis of a 60-year-old male patient came with complaints of with fever, was found to have atypical cells with blasts and pancytopenia revealed four copies of chromosome 8 in 86% cells represented as 48,XY,+8,+8 [18]/46, XY [3] according to ISCN [3]. FISH analysis showed Tetrasomy 8 in 90% cells. However, a small clone of 6% with Trisomy 8 was identified indicating clonal evolution of Trisomy 8 to Tetrasomy 8 [Table/Fig-2].



### Case 3

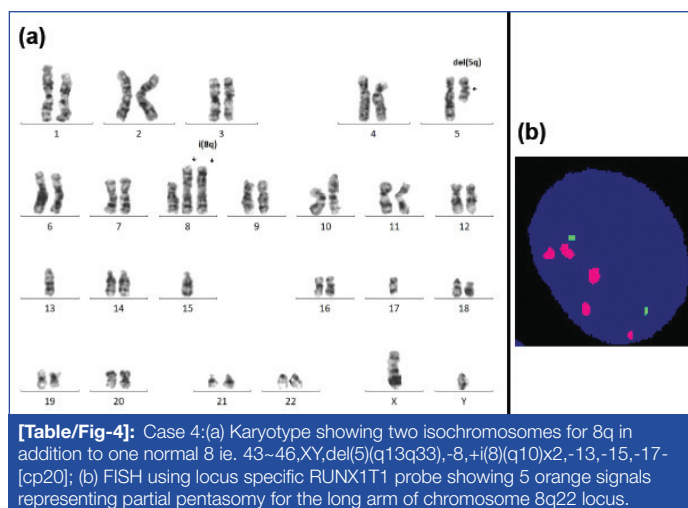
A 51-year-old male patient with Chronic Myeloid Leukaemia- chronic phase (CML-CP) on imatinib treatment since one year, was referred for cytogenetic studies. Karyotyping did not reveal presence of Philadelphia chromosome (Ph), but Trisomy 8 and Tetrasomy 8 were detected. This was also clonal evolution represented as 47, XY, +8 (4)/48, XY, +8,+8(3)/46, XY(13) according to ISCN [Table/Fig-3] [3]. As this was a case of CML-CP referred after one-year of imatinib treatment, the karyotype findings represent disappearance of Philadelphia.



Positive clone if initially existed and appearance of a new clone of Tetrasomy 8 which possibly represents clonal evolution to an aggressive disease status as a result of presence of Tetrasomy 8. Since, the patient succumbed to illness and as the karyotype was not available at diagnosis, hence the confirmation of Ph negative clonal evolution could not be ascertained.

### Case 4

Bone marrow sample of an 85-year-old male patient was referred for flow cytometry and chromosomal analysis. Flow cytometry analysis diagnosed the case as AML with monocytic differentiation with 20% Myeloperoxidase (MPO) positive blasts and 20% monocytoid cells. Karyotyping revealed a complex monosomal karyotype with hypodiploidy of 43-45 chromosomes, deletion on the long arm of chromosome 5, two additional copies of isochromosomes for the long arm of chromosome 8 and loss of chromosomes 13,15 and 17 represented by 43~46,XY,del(5)(q13q33),-8,+i(8)(q10)x2,-13,-15,-17 (cp20). Two copies of isochromosomes for 8q and one normal 8 resulted in five copies for 8q, representing polysomy 8q. FISH using locus specific probe for RUNX1T1 (AML1) revealed five orange signals for 8q22 in 64% cells confirming presence of Polysomy 8q and absence of Trisomy and Tetrasomy 8 clones [Table/Fig-4].



## DISCUSSION

Trisomy 8 is one of the most frequent numerical chromosomal abnormality associated with myeloid malignancies and myelodysplastic syndrome, while tetrasomy 8 is a rare numerical chromosomal aberration, most commonly linked to AML with monocytic differentiation, mostly with French-American- British M0-M2 [4]. Tetrasomy 8 has shown association with younger age group [2,4-6]. In contrast, present case study showed higher age group ranging from 51 to 85 years.

Studies documented the association of high leukocyte and blast count in cases with Trisomy 8 and Tetrasomy 8 [2,4]. This could not be ascertained in the patients included in this study as they were referred from remote centers and limited source of clinical and laboratory information was available except for case 1.

Probable mechanism for formation of Tetrasomy 8 seems to be a step wise evolution from disomy to Tetrasomy by way of two consecutive mitotic non disjunctions as observed in two of the present cases [3]. However, there have been different mechanisms reported with simultaneous non disjunction of both homologues during single cell division. Presence of Trisomy 8 as a sub-clone would be a result of loss of one of the duplicated chromosome 8 [4].

To rule out co-existence of Trisomy 8 with Tetrasomy 8 for case 1, FISH test was performed using RUNX1T1 probe, which showed four RUNX1T1 signals indicating Tetrasomy 8 as a single primary clone as a rare occurrence [Table/Fig-1]. However, in Case 2 and 3, it seems to be an evolutionary mechanism from Trisomy 8 to Tetrasomy 8 [Table/Fig-2,3] as reported by El Wardany TA et al., [4].

In case 4, multiple copies of long arm of chromosome 8 could be due to duplication during isochromosome formation rather than Trisomy and Tetrasomy mechanism. In the present series, the mechanisms for leukemogenesis could be either due to loss of heterozygosity of the short arm of chromosome 8 or due to proto-oncogene activation by multiple copies of 8q long arm as reported by Ferro MT et al., and this suggests genomic instability due to multiple additional chromosomal abnormalities [7]. Aktas D et al., have showed Tetrasomy 8 to have a proliferative and aggressive clinical course with lower survival and higher relapse rates after remission probably caused by the multiple copies of the genes located on the long arm of chromosome 8 [5].

The exact role of genes on chromosome 8 in leukemogenesis is not clearly understood, with some reports mentioning the potential malignant transformation due to the over expression of c- myc gene on 8q24, cmos on 8q22 and RUNX1T1 gene on 8q21.3 [1]. Farag F et al., have reported an additional molecular event of a hotspot missense mutation in DNMT3A in a patient with Tetrasomy 8. Additionally,

altered expression levels of genes responsible for apoptotic regulation could also have direct implications on survival [2].

From various studies, it is evident that the reason for poor prognosis in Tetrasomy 8 needs further investigation on more number of cases based on molecular pathway deregulation mechanisms along with their clinical, biological information and clinical consequences [1,2,4].

## CONCLUSION(S)

Documentation of rare tetrasomy 8 cases will lead to building up on their clinical information, disease outcome and understanding the mechanism of leukemogenesis. This will further define them as separate disease entity for personalised targeted therapy initiation.

Reporting rare Tetrasomy 8 findings would help to gather more detailed clinical and laboratory information and lead to better understanding of the pathogenetic mechanisms and disease outcome. This will further define them as separate disease entity for personalised targeted therapy initiation.

## REFERENCES

- [1] Kim J, Park TS, Song J, Lee KA, Lee SG, Cheong JW, et al. Tetrasomy 8 in a patient with acute monoblastic Leukaemia. *Korean J Lab Med.* 2008;8(4):262-66.
- [2] Farag F, Morcus R, Ramachandran P, Josan K, Wang JC. Tetrasomy 8 associated with a poor prognosis in acute monoblastic Leukaemia: A case report. *Cureus.* 2019;11(2):e4068.
- [3] McGowan-Jordan J, Simons A, Schmid M Jean. *An International System for Human Cytogenomic Nomenclature.* Karger. 2016.
- [4] El Wardany TA, Keyed HF, Saad AA, El-Dine El-Jaffery SS, Moustafa NN. Polysomy 8 in Egyptian patients with de-novo acute myeloid Leukaemia. *Egypt J Haematol.* 2012;37:213-20.
- [5] Aktas D, Tuncbilek E, Cetin M, Hicsonmez G. Tetrasomy 8 as a primary chromosomal abnormality in a child with acute megakaryoblastic Leukaemia: A case report and review of the literature. *Cancer Genet Cytogenet.* 2001;126(2):166-68.
- [6] Tsigotis P, Papageorgiou S, Abatzis D. Acute myelogenous Leukaemia with tetrasomy 8 is a disease with a poor prognosis. *Cancer Genet Cytogenet.* 2005;161(1):78-81.
- [7] Ferro MT, Vázquez-Mazariego Y, Ramiro S, Santiago MF, García-Sagredo JM, Nuñez R, et al. Trisomy/ tetrasomy of chromosome 8 and +i(8q) as the sole chromosome abnormality in three adult patients with myelomonocytic Leukaemia. *Cancer Genet Cytogenet.* 2000;120(2):163-65.

### PARTICULARS OF CONTRIBUTORS:

1. Cytogeneticist, Department of Cytogenetics, SRL Ltd, Mumbai, Maharashtra, India.
2. Scientific Officer, Department of Cytogenetics, SRL Ltd, Mumbai, Maharashtra, India.
3. Section Technical Supervisor, Department of Cytogenetics, SRL Ltd, Mumbai, Maharashtra, India.
4. Scientific Officer, Department of Cytogenetics, SRL Ltd, Mumbai, Maharashtra, India.
5. Senior Cytogeneticist, Department of Cytogenetics, SRL Ltd, Mumbai, Maharashtra, India.
6. Head-Cytogenetics, Department of Cytogenetics, SRL Ltd, Mumbai, Maharashtra, India.

### NAME, ADDRESS, E-MAIL ID OF THE CORRESPONDING AUTHOR:

Dr Anurita Pais,  
Plot 1 Prime Square Bldng Gaiwadi Ind Estate sv Road Goregoan West,  
Mumbai, Maharashtra, India.  
E-mail: anurita.pais@srl.in

### PLAGIARISM CHECKING METHODS: [Jain H et al.]

- Plagiarism X-checker: Apr 03, 2021
- Manual Googling: Jun 26, 2021
- iThenticate Software: Aug 18, 2021 (3%)

### ETYMOLOGY: Author Origin

### AUTHOR DECLARATION:

- Financial or Other Competing Interests: None
- Was informed consent obtained from the subjects involved in the study? Yes
- For any images presented appropriate consent has been obtained from the subjects. Yes

Date of Submission: **Apr 02, 2021**

Date of Peer Review: **Jun 07, 2021**

Date of Acceptance: **Jul 10, 2021**

Date of Publishing: **Sep 01, 2021**