

# Acropigmentation of Dohi- A Rare Presentation

SAMIKSHA DEEPAK CHAVHAN<sup>1</sup>, SUGAT JAWADE<sup>2</sup>, BHUSHAN MADKE<sup>3</sup>, ADARSHLATA SINGH<sup>4</sup>

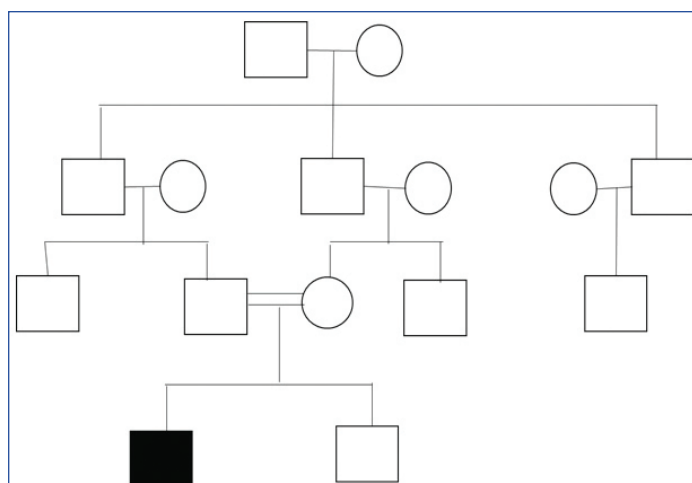
## ABSTRACT

Reticulate Acropigmentation of Dohi or Dyschromatosis symmetrica hereditaria, is an autosomal dominant genodermatosis, with very few reported autosomal recessive traits mostly seen in the Japanese population. A 27-year-old Indian male presented with light and dark coloured lesions involving bilateral arms and forearms, chest, back, and bilateral lower limbs with sparing of face, palms, and soles from 20 years. There were multiple hyperpigmented and hypopigmented macules which on detailed cutaneous examination and biopsy was diagnosed as reticulate acropigmentation of Dohi. As no definitive and effective treatment is available in this condition, the patient was treated conservatively with sun protection and sunscreen to decrease the contrast between hyperpigmented and hypopigmented lesions however the patient could not be followed-up further. Acropigmentation of Dohi being a rare entity diagnosing and differentiating it from other disorders is important.

**Keywords:** Autosomal dominant, Autosomal recessive, Dyschromatosis symmetrica hereditaria, Dyschromatosis symmetrica universalis, Genodermatosis

## CASE REPORT

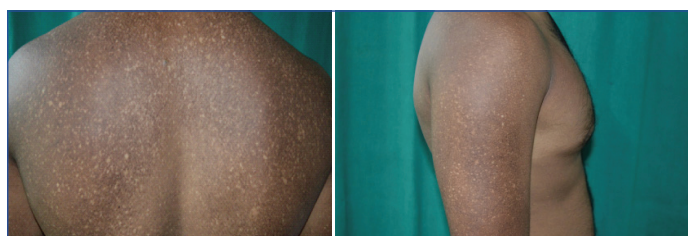A 27-year-old Indian male presented with light and dark coloured lesions involving bilateral arms and forearms, chest, back, and bilateral lower limbs with sparing of face, palms, and soles from 20 years. The lesions gave variegated mottled appearance. The lesions initially involved only arms and back and were noticed first at the age of 7 years. The lesions gradually increased to involve the whole of the body in the period of the last 10 years, after that there have been no further increase in areas of involvement. There was a history of parental consanguinity and no family member was affected with similar skin lesions in the past generations, as shown in the 4-generation pedigree chart [Table/Fig-1]. There was also no history of any pigmentary disorder in the family, hence supporting the autosomal recessive inheritance pattern.



[Table/Fig-1]: Signifies the 4-generation pedigree chart.

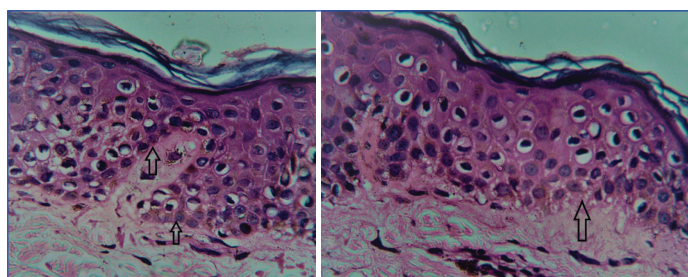
○: Female; □: Male; ■: Affected Male; —: Consanguineous marriage

On cutaneous examination, multiple hypopigmented and hyperpigmented macules of size ranging from 0.5 - 1 cm involving back [Table/Fig-2], chest, bilateral arms and forearms [Table/Fig-3], and lower limb with sparing of palms, soles and face were seen. On further examination, the patient did not show the presence of palmar pits and breaks in dermatoglyphics. There was no mucosal involvement and the systemic examination of the patient was normal with no associated co-morbidities.



[Table/Fig-2]: Multiple hyperpigmented and hypopigmented macules all over the back; [Table/Fig-3]: Multiple hyperpigmented and hypopigmented macules over arm. (Images from left to right)

Two biopsies were taken, one from a hypopigmented macule and another from a hyperpigmented macule from the back, both the pieces measured about less than 0.5 cm in size. Histopathological report on Haematoxylin and Eosin (H&E) stain of hyperpigmented macule showed an increased number of melanocytes in the basal layer of the epidermis [Table/Fig-4] whereas biopsy from hypopigmented macule comparatively showed the lesser number of melanocytes in the basal layer [Table/Fig-5]. Based on the biopsy report diagnosis was made as Acropigmentation of Dohi. Reticulate Acropigmentation of Kitamura, Xeroderma pigmentosa, and Dowling-Degos disease were ruled out based on the clinical examination and biopsy report.



[Table/Fig-4]: On histopathological examination with H & E stain, hyper-pigmented macule showing an increased number of melanocytes in the basal cell layer of the epidermis in 40X microscopic view; [Table/Fig-5]: On histopathological examination with H & E stain, hypopigmented macule showing lesser number of melanocytes in the basal layer of the epidermis in 40X microscopic view. (Images from left to right)

Being a genetic disorder, without any symptoms and systemic involvement, no definitive management was done. The patient was counselled about the disease condition and strict sun protection was advised to reduce the contrast between hyper and hypo pigmented macules.

## DISCUSSION

Reticulate Acropigmentation of Dohi was first described by Toyoma I in 1929 [1] which is commonly seen in the Japanese population and rare in other parts of the world [2-4]. There has been a study by the Japanese dermatologist where almost 185 cases of Acropigmentation of Dohi were reviewed [5]. However, it is uncommon in Indian population and very few cases have been reported till now. It is a rare autosomal dominant, genodermatosis which starts presenting in infancy or early childhood [2-4], and some cases with autosomal recessive inheritance have been reported [2,6]. However, there is paucity of data on the incidence of both the patterns of inheritance. The disease condition is characterised by hyper and hypopigmented macules giving variegated mottled appearance [3] which usually starts at the age of 6 years [7] and becomes stable by the time patient reaches the age of adolescence [7]. This pigmentation lasts lifelong. But, in present case patient did showed an increase in the number of lesions even after adolescence. The disease presentation was due to a mutation in Ribonucleic Acid (RNA) editing enzyme called RNA-specific adenosine deaminase (ADAR1) having gene locus on chromosome 6q24.2-q25.22 [2,8].

History, cutaneous examination, and histopathological findings of index patient were in support of the diagnosis of Acropigmentation of Dohi. Alfadley A et al., reported a case of autosomal recessive trait of reticulate acropigmentation of Dohi in three black siblings with absence of similar pigmentary involvement in family members which supported the pattern of inheritance [6]. Acropigmentation of Dohi in rare cases is associated with other defects. Zhou Q et al., have reported Congenital Heart Disease (CHD) and haemangioma with Dyschromatosis symmetrica hereditaria [9]. There is also a reported case of a 10-year-old Indian girl of Dyschromatosis symmetrica hereditaria who presented with dystonia since infancy and was due to bilateral striatal necrosis of brain [10]. In one of the cases reported from Japan seven-year-old girl presented with chilblains showed ADAR1 gene mutation [11] however, in this case there were no associated co-morbidity and no systemic derangement since birth.

Other pigmentary disorders like Reticulate Acropigmentation of Kitamura, Dyschromatosis hereditaria universalis, Xeroderma pigmentosa, and Dowling-Degos disease needs to be differentiated [2]. Reticulate Acropigmentation of Kitamura shows atrophic macules, palmar pits and there are no hypopigmented macules seen [2,7]. Dowling-Degos disease, which is also an autosomal dominant disease shows flexural involvement with comedo like lesions and pitted scars [2,7]. Xeroderma pigmentosa which is due to abnormal Deoxyribonucleic Acid (DNA) repair shows the involvement of photo exposed areas with erythema, diffuse freckling and telangiectasia [2,7]. Dyschromatosis hereditaria universalis which is also an autosomal disorder also shows the appearance of hyper and hypopigmented

macules, sparing of palms and soles. It is commonly associated with short stature, deafness, grand mal epilepsy and solar elastosis [2,7]. Acropigmentation of Dohi presents with only skin manifestations without any symptoms and systemic involvement. Also, there is no effective treatment available, and differentiating it from other pigmentary disorders to make an appropriate diagnosis and avoid misleading treatment is important [7,12].

## CONCLUSION(S)

Present patient had a typical presentation of reticulate Acropigmentation of Dohi with late onset and without any significant family history, hence could be an autosomal recessive trait of the disease which is a rare occurrence. Most of the cases stay unreported due to only skin manifestation, hence diagnosing and differentiating it from other skin conditions is important. Even with the late clinical onset, genodermatosis is a possibility and hence, it is suggested that complete assessment of the patient presenting with pigmentary disorder should be done.

## REFERENCES

- Toyama I. Dyschromatosis symmetrica hereditaria. Jpn J Dermatol. 1929;27:95-96 (in Japanese).
- Mohana D, Verma U, Amar AJ, Choudhary R. Reticulate acropigmentation of dohi: A case report with insight into genodermatoses with mottled pigmentation. Indian J Dermatol. 2012;57:42-44.
- Rao KS, Shetty JN. Acropigmentation of dohi. Indian J Dermatol Venereol Leprol. 1998;64:128-29.
- Barzegari M, Kiavash K. Dyschromatosis symmetrica hereditaria (reticulate acropigmentation of dohi): First report from Iran. Indian J Dermatol. 2009;54:11-13.
- Oyama M, Shimizu H, Ohata Y, Tajima S, Nishikawa T. Dyschromatosis symmetrica hereditaria (reticulate acropigmentation of Dohi): Report of a Japanese family with the condition and a literature review of 185 cases. Br J Dermatol. 1999;140(3):491-96.
- Alfadley A, Al Ajjan A, Hainau B, Pedersen KT, Al Hoqail I. Reticulate acropigmentation of Dohi: A case report of autosomal recessive inheritance. J Am Acad Dermatol. 2000;43(1 Pt 1):113-17.
- Gaiowski CB, Zuneda Serafini S, Werner B, Deonizio JM. Dyschromatosis symmetrica hereditaria of late onset? Case Rep Dermatol Med. 2014;2014:639537. doi:10.1155/2014/639537
- Kono M, Akiyama M. Dyschromatosis symmetrica hereditaria and reticulate acropigmentation of Kitamura: An update. J Dermatol Sci. 2019;93(2):75-81.
- Zhou Q, Zhang L, Zhang Y, Luo H, Zhu L, Wang P, et al. Two novel ADAR1 gene mutations in two patients with dyschromatosis symmetrica hereditaria from birth. Mol Med Rep. 2017;15(6):3715-18.
- Kono M, Suganuma M, Dutta A, Ghosh SK, Takeichi T, Muro Y, et al. Bilateral striatal necrosis and dyschromatosis symmetrica hereditaria: A-I editing efficiency of ADAR1 mutants and phenotype expression. Br J Dermatol. 2018;179(2):509-11. doi: 10.1111/bjd.16610. Epub 2018 May 29. PMID: 29603717.
- Kono M, Suganuma M, Shimada T, Ishikura Y, Watanabe S, Takeichi T, et al. Dyschromatosis symmetrica hereditaria with chilblains due to a novel two-aminoadic deletion in the double-stranded RNA-binding domain of ADAR1. J Eur Acad Dermatol Venereol. 2018;32(10):e394-96. doi: 10.1111/jdv.15076. Epub 2018 Jun 11. PMID: 29775506.
- Chao SC, Huang CY, Yang MH. A novel nonsense mutation of the DSRAD gene in a Taiwanese family with dyschromatosis symmetrica hereditaria. Eur J Dermatol. 2006;16(4):449-50.

### PARTICULARS OF CONTRIBUTORS:

- Resident Doctor, Department of Dermatology, Jawaharlal Nehru Medical College, Wardha, Maharashtra, India.
- Professor, Department of Dermatology, Jawaharlal Nehru Medical College, Wardha, Maharashtra, India.
- Professor and Head, Department of Dermatology, Jawaharlal Nehru Medical College, Wardha, Maharashtra, India.
- Professor, Department of Dermatology, Jawaharlal Nehru Medical College, Wardha, Maharashtra, India.

### NAME, ADDRESS, E-MAIL ID OF THE CORRESPONDING AUTHOR:

Dr. Samiksha Deepak Chavhan,  
Jawaharlal Nehru Medical College, Sawangi, Wardha-442005, Maharashtra, India.  
E-mail: samiksha.chavhan4@gmail.com

### AUTHOR DECLARATION:

- Financial or Other Competing Interests: None
- Was informed consent obtained from the subjects involved in the study? Yes
- For any images presented appropriate consent has been obtained from the subjects. Yes

### PLAGIARISM CHECKING METHODS: [Jain H et al.]

- Plagiarism X-checker: May 08, 2021
- Manual Googling: Sep 29, 2021
- iThenticate Software: Oct 25, 2021 (3%)

### ETYMOLOGY: Author Origin

Date of Submission: **May 07, 2021**  
Date of Peer Review: **Jun 26, 2021**  
Date of Acceptance: **Oct 05, 2021**  
Date of Publishing: **Nov 01, 2021**