

Thyroglossal Duct Cyst with Multiple Tracts- A Case Report

S PRABAKARAN¹, T SWETHA², RB NAMASIVAYA NAVIN³, S RAJASEKARAN⁴, K PRIYA⁵

ABSTRACT

A thyroglossal duct cyst is an embryological remnant which persists due to failure in the closure of thyroglossal duct. Worldwide the prevalence of thyroglossal cysts is about 7%. There is no sexual predominance seen. Normally at about 10th week of gestation the thyroglossal duct involutes, if there is any persistent duct remnant then this can lead to thyroglossal duct cyst formation. There is 1% chance of malignant transformation (papillary carcinoma). A 21-year-old female presented to the Ear, Nose and Throat Department with the complaint of swelling in front of the neck for the past one month. A 2 x 1.5 cm² swelling was observed in the anterior aspect of neck-infrahyoid region extending till thyroid notch. The swelling moved upwards with protrusion of the tongue and deglutition. Ultrasound neck revealed a complex cystic lesion in midline of neck of size 2 x 1 x 2.2 cm³ suggestive of thyroglossal cyst. Fine Needle Aspiration Cytology (FNAC) showed features suggestive of thyroglossal duct cyst. Patient was prepared for Sistrunk procedure. Intraoperatively multiple tracts of thyroglossal duct cyst were seen and the same were removed in toto. Patient was on regular follow-up postoperatively for a period of one year and no evidence of any recurrence was seen.

Keywords: Congenital cervical anomaly, Infrahyoid cyst, Sistrunk procedure, Thyroglossal duct remnant

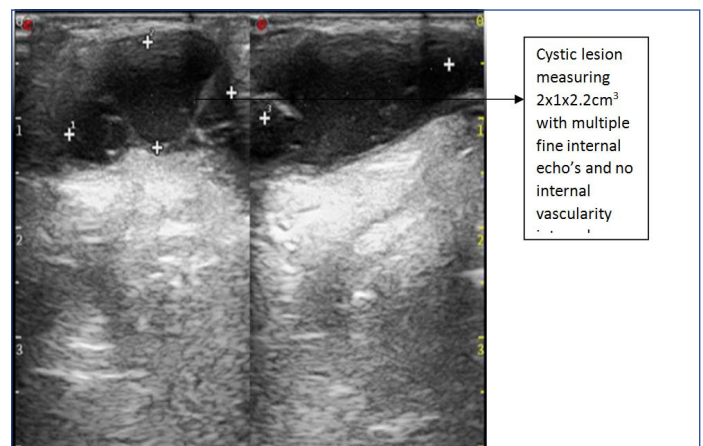
CASE REPORT

A 21-year-old female presented to the Ear, Nose and Throat Department with the complaint of swelling in front of the neck for the past one month. Detailed history was collected from the patient after obtaining informed written consent. Patient gave history of swelling over the midline of the neck which was moving upward with protrusion of tongue and deglutition. No history of any other specific ear, nose and throat complaints was present. No history of known co-morbidities. No relevant personal and family history.

General physical examination was normal. Patient was found to be haemodynamically stable. Local examination of ear, nose and throat was found to be normal. On examination, a swelling of 2 x 1.5 cm² was observed in the anterior aspect of neck-infrahyoid region extending till thyroid notch which moved upwards with protrusion of the tongue and deglutition and no evidence of visible sinuses/ scars/pulsations was observed over the swelling on inspection. On palpation swelling was firm in consistency, surface over the swelling was smooth with a well-defined border, no fixity (mobile in both horizontal and vertical planes). No warmth/tenderness was present, able to get below the swelling. Fluctuation test and transillumination test was positive.

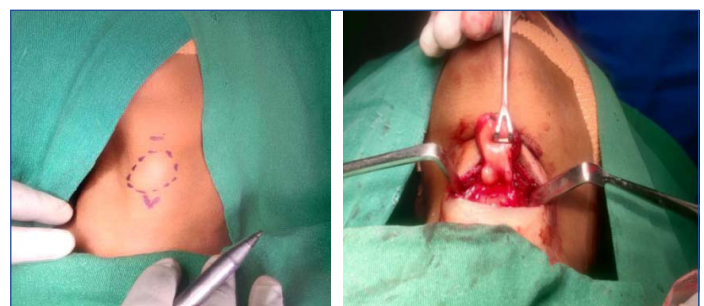
Ultrasonography (USG) neck revealed a complex cystic lesion in midline of neck 2 x 1 x 2.2 cm³ was suggestive of thyroglossal cyst [Table/Fig-1]. Differential diagnosis was dermoid cyst, branchial cleft cyst, ectopic thyroid anomalies with odontogenic origin, lipomas, metastatic lymph nodes. Fine Needle Aspiration Cytology (FNAC) smear showed neutrophils and follicular cells with intranuclear grooves and intranuclear cytoplasmic inclusion bodies was suggestive of thyroglossal duct cyst. The other differential diagnosis was ruled out as Ultrasound and FNAC were suggestive of thyroglossal duct cyst.

With the clinical history, clinical examination and investigation, a diagnosis of thyroglossal cyst was made. All routine blood investigations were done and found to be normal. Patient was planned for Sistrunk operation after thorough preanaesthetic work up. Complete airway evaluation was done. Mallampatti Grade was 2. X-Ray neck anteroposterior /lateral was done and found to be normal. Indirect laryngoscopic examination was normal. Fitness was obtained for surgery and the procedure was executed.



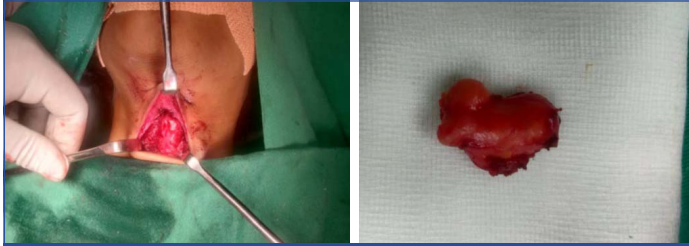
[Table/Fig-1]: Ultrasound image showing complex cystic lesion in midline of neck- suggestive of thyroglossal cyst.

Under general anaesthesia with orotracheal intubation, patient was laid down in supine position with neck extended, parts painted and draped [Table/Fig-2]. Local infiltration was given with 1% lignocaine with 1:1,00,000 epinephrine to obtain a clear bloodless field. Horizontal skin crease incision was made over the swelling. Incision deepened, subplatysmal flap was elevated. Strap muscles were divided in midline and retracted laterally. Swelling was separated from the adjacent structures [Table/Fig-3]. Multiple tracts of thyroglossal duct were seen and traced. Hyoid bone was identified and delineated by releasing the suprahyoid and infrahyoid muscles in the central part. High



[Table/Fig-2]: Preoperative image of swelling in midline anterior aspect of neck with markings. **[Table/Fig-3]:** Intraoperative image of thyroglossal cyst. (Images from left to right)

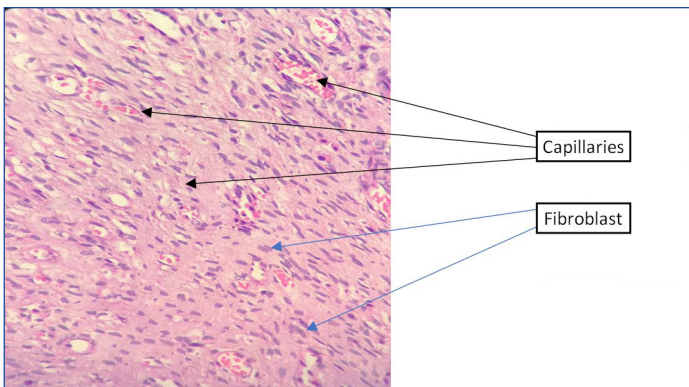
ligation was done and the specimen was removed [Table/Fig-4]. After complete haemostasis suction drain of size 22 was fixed. Strap muscles were approximated in midline. Operation site was closed in layers. Patient withstood the procedure and specimen was sent for histopathological examination [Table/Fig-5]. Patient was treated postoperatively with intravenous antibiotics (injection taxin 1 gm twice a day for two days followed by a course of oral antibiotics (tablet cepodem 200 mg twice a day for five days), analgesics (tablet zerodol -p twice a day) for five days, antacids (tablet pan D before breakfast once a day for five days) and intravenous (i.v.) steroids (injection decadron 8 mg i.v. twice a day for two days) followed by tablet ivepred 8 mg twice a day for five days.



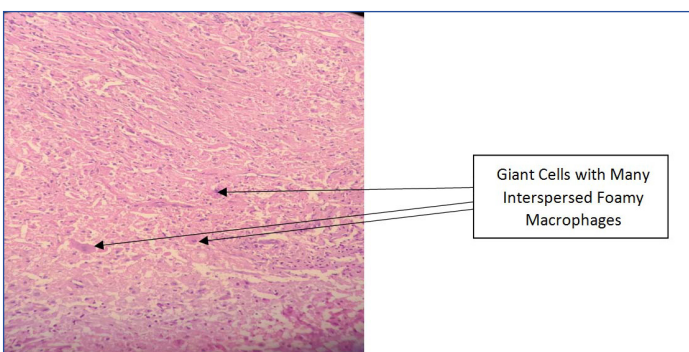
[Table/Fig-4]: Surgical field after removal of specimen.

[Table/Fig-5]: Removed specimen. (Images from left to right)

Postoperative histopathology specimen revealed features conclusive of cyst lined by squamous epithelium with florid xanthogranulomatous reaction. It reveals proliferation of capillaries and fibroblasts [Table/Fig-6], giant cell reaction [Table/Fig-7] and squamous epithelium and lumen with proteinaceous material [Table/Fig-8]. Patient was on routine postoperative follow-up for a period of one year and no evidence of any recurrence was noted.



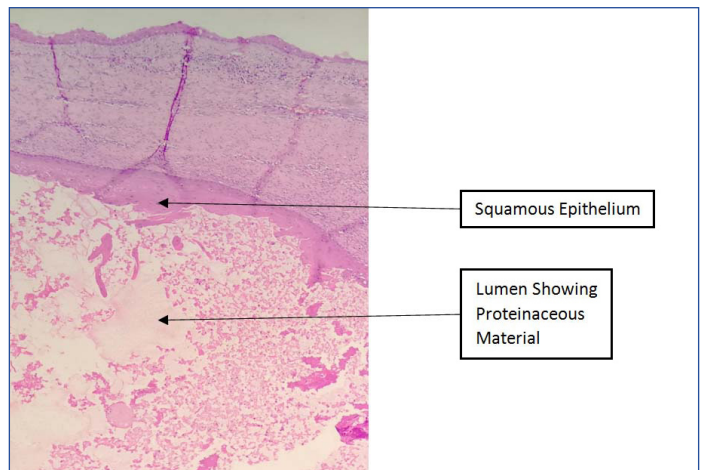
[Table/Fig-6]: Histopathology image showing proliferation of capillaries and fibroblasts. (40X, Stain- H&E)



[Table/Fig-7]: Histopathology image showing giant cell reaction. (10X, Stain- H&E)

DISCUSSION

A thyroglossal duct cyst is an embryological remnant which persists due to failure in the closure of thyroglossal duct [1]. They are the most common midline neck masses more common in paediatric age group compared to adults. Worldwide the prevalence of thyroglossal cysts is about 7% [2]. The common congenital



[Table/Fig-8]: Histopathology image showing lumen with proteinaceous material (4X, Stain- H&E).

anomaly of the cervical region is thyroglossal duct cyst [2]. There is no sexual predominance seen. Normally at about 10th week of gestation the thyroglossal duct involutes, if there is any persistent duct remnant then this can lead to thyroglossal duct cyst formation. There is one percent chance of malignant transformation (papillary carcinoma). The thyroglossal duct can persist and exist as a tract, duct or as a cyst anywhere between the foramen caecum to the thyroid gland [1,2].

In a meta-analysis of 381 cases of thyroglossal duct cysts by Allard RH, the following locations were reported: 2.1% lingual, 24.1% suprahyoid, 60.9% thyrohyoid and 12.9% suprasternal [3]. Suprahyoid thyroglossal duct cysts usually occur in midline while infrahyoid thyroglossal duct cysts are para-midline. In a case series of 685 cases, the size of the cysts were ranging from 0.2 cm to 8.5 cm with a mean of 2.6 cm similar to our study were the size of the cyst was 2x1.5 cm² [4]. The thyroglossal duct cyst usually occurs in children below five years of age than patients aged above 20 years, but about one-third of cases can also be seen after second decade of life similar to the present case report [3,4].

A case of giant thyroglossal duct cyst which was measuring 9.2x7.6 cm² was described by El-Ayman YA et al., in an 85-year-old male which was slowly progressive from his 20 years of age indicating that these cysts can present initially as early as second decade of life similar to our case study [5]. As it is related to both hyoid bone and foramen coecum, thyroglossal duct cysts move upwards with swallowing and protrusion of tongue [5,6]. There is a 1% incidence of carcinoma, classically papillary thyroid cancer within thyroglossal duct cysts [6-8].

Definitive management of thyroglossal duct cyst is sistrunk operation [9,10]. Marshall SF and Becker WF in their study had a recurrence of 1.3% in their series of 310 cases proving that recurrence of cyst after surgery is an uncommon event provided the tract is excised fully [11]. It is ideal to excise thyroglossal duct cyst in patients with or without mass effect or cosmetic reason or recurrent infection [12]. One more important factor to be considered is that diagnosis of thyroglossal duct cyst should never be omitted in elderly patients and extreme size of the swelling [13,14]. It is difficult to diagnose a thyroglossal duct cyst when it appears in the sublingual area or floor of oral cavity as it is not easy to differentiate it from other cysts in that region [15]. Differential diagnosis of thyroglossal duct cysts include branchial cleft cyst, dermoid cysts, cystic hygroma, epidermoid cysts, thymic cyst, bronchogenic cyst, midline cervical cleft and midline anterior neck inclusion cyst [15].

CONCLUSION(S)

Standard treatment for thyroglossal cyst is sistrunk operation with good outcome and low recurrence rate. Recurrence rate

of thyroglossal duct cyst is 10%. The factors that contribute to recurrence include intraoperative rupture, incomplete excision, insufficient surgical experience and presence of infection. It is important to keep in mind that multiple tracts may be present rarely in thyroglossal duct cysts which should be removed in-toto along with a central part of the hyoid bone to prevent the recurrence.

REFERENCES

- [1] Hussain A, Sajjad H. Anatomy, Head and Neck, Thyroid Thyroglossal Duct. [Updated 2021 Aug 11]. In: StatPearls [Internet]. Treasure Island (FL): StatPearls Publishing; 2021 Jan-. Available from: <https://www.ncbi.nlm.nih.gov/books/NBK54494/>
- [2] Shakrawal N, Varshney B, Verma AK, Khara S, Goyal A, Patro SK. Thyroglossal duct cyst papillary carcinoma: A treatment puzzle yet to be solved! Annals of Indian Academy of Otorhinolaryngology Head and Neck Surgery. 2019;3(2):85-88.
- [3] Allard RH. The thyroglossal cyst. Head Neck Surg. 1982;5(2):134-46. doi: 10.1002/hed.2890050209. PMID: 7169333.
- [4] Thompson LD, Herrera HB, Lau SK. A clinicopathologic series of 685 thyroglossal duct remnant cysts. Head and neck pathology. 2016;10(4):465-74.
- [5] El-Ayman YA, Naguib SM, Abdalla WM. Huge thyroglossal duct cyst in elderly patient: Case report. Int J Surg Case Rep. 2018;51:415-18.
- [6] Rathod JK, Rathod SJ, Kadam V. Papillary carcinoma of thyroid in a thyroglossal cyst. J Oral Maxillofac Pathol. 2018;22(Suppl 1):S98-S101.
- [7] Patigaroo SA, Dar NH, Jallu AS, Ahmad R. Thyroglossal duct cysts: A clinicosurgical experience. Indian J Otolaryngol Head Neck Surg. 2017;69(1):102-07.
- [8] Marianowski R, Amer JA, Morisseau-Durand MP, Manach Y, Rassi S. Risk factors for thyroglossal duct remnants after Sistrunk procedure in a pediatric population. Int J Pediatr Otorhinolaryngol. 2003;67(1):19-23.
- [9] Forest VI, Murali R, Clark JR. Thyroglossal duct cyst carcinoma: case series. J Otolaryngol Head Neck Surg. 2011;40(2):151-56.
- [10] Deditis RA, Guimaraes AV. Papillary thyroid carcinoma in thyroglossal duct cyst. International surgery. 2000;85(3):198-201.
- [11] Marshall SF, Becker WF. Thyroglossal cysts and sinuses. Annals of Surgery. 1949;129(5):642.
- [12] Ibrahim FF, Alnoury MK, Varma N, Daniel SJ. Surgical management outcomes of recurrent thyroglossal duct cyst in children-A systematic review. Int J Pediatr Otorhinolaryngol. 2015;79(6):863-67.
- [13] Ghaneim A, Atkins P. The management of thyroglossal duct cysts. Int J Clin Pract. 1997;51(8):512-13.
- [14] Arora V, Kathuria B, Yadav SP, Hernot S. Thyroglossal duct cyst and Sistrunk: a case series. Journal of Case Reports. 2015;5(2):322-26.
- [15] Park MJ, Shin HS, Choi DS, Choi HY, Choi HC, Lee SM, et al. A rare case of thyroglossal duct cyst extending to the sublingual space: A case report. Medicine. 2020;99(17).

PARTICULARS OF CONTRIBUTORS:

1. Assistant Professor, Department of Otorhinolaryngology, Chettinad Hospital and Research Institute, Chennai, Tamil Nadu, India.
2. Junior Resident, Department of Otorhinolaryngology, Chettinad Hospital and Research Institute, Chennai, Tamil Nadu, India.
3. Assistant Professor, Department of Otorhinolaryngology, Chettinad Hospital and Research Institute, Chennai, Tamil Nadu, India.
4. Professor and Head, Department of Otorhinolaryngology, Chettinad Hospital and Research Institute, Chennai, Tamil Nadu, India.
5. Professor, Department of Otorhinolaryngology, Chettinad Hospital and Research Institute, Chennai, Tamil Nadu, India.

NAME, ADDRESS, E-MAIL ID OF THE CORRESPONDING AUTHOR:

Dr. S Prabakaran,
3/286, Pachaiyappar Street, Periyarsalai, Palavakkam,
Chennai-600041, Tamil Nadu, India.
E-mail: somu.prabakaran@gmail.com

PLAGIARISM CHECKING METHODS: [Jain H et al.]

- Plagiarism X-checker: May 12, 2021
- Manual Googling: Sep 01, 2021
- iThenticate Software: Sep 27, 2021 (8%)

ETYMOLOGY: Author Origin

AUTHOR DECLARATION:

- Financial or Other Competing Interests: None
- Was informed consent obtained from the subjects involved in the study? Yes
- For any images presented appropriate consent has been obtained from the subjects. Yes

Date of Submission: **May 11, 2021**
Date of Peer Review: **Jul 29, 2021**
Date of Acceptance: **Sep 09, 2021**
Date of Publishing: **Nov 01, 2021**