

Rapidly Growing *Mycobacterium* in Postsurgical Wounds: A Systematic Review and Meta-analysis

ASHOK MHASKE¹, SHUBHANGI MHASKE², SANJAY HARKE³, ARTI JAIN⁴, JASWANT PATEL⁵

ABSTRACT

Introduction: Rapidly Growing Mycobacteria (RGM) are extensively found in nature and is isolated as an environmental saprophyte from water sources and soil. The incidence of these opportunistic pathogens has increased in the recent years as nosocomial outbreaks, with an exaggerated outcome of morbidity and resistant antibiotic intervention.

Aim: To assess the occurrence of rapidly growing mycobacteria in postsurgical wounds.

Materials and Methods: Literature search in PubMed, Google Scholar and Scopus of published articles in English language from March 2010 to December 2020 were analysed for the predetermined outcomes. Keywords used for the literature search were “atypical mycobacteria”; “non tuberculous mycobacteria”; “rapidly progressing mycobacteria”; “RGM”; “postsurgical wounds”;

“surgical site infection”; “wound site”; “port hole infections”. A total of 10 studies adhering to Preferred Reporting Items for Systematic Reviews and Meta-Analyses (PRISMA) guidelines were included for statistical analysis. OpenMeta-Analyst software was used.

Results: A prevalence of 56.4% (95% CI: 33.0; 79.8) was noted in 592 patients evaluated postsurgically. The articles included were of fair quality when assessed on Ottawa scale. *M.Chelonae*, *M.Abscessus*, *M.fortuitum* and *M.massiliense* were the most commonly isolated organisms. Clarithromycin, Amikacin, Ciprofloxacin, Imepenem and Linezolid were administered as antibiotic intervention.

Conclusion: Considering the higher prevalence of RGM infection (56.40%), every surgeon must consider the possibility of this opportunistic infection. It is vital to address this issue to eliminate the risk of severe outcome.

Keywords: Antibiotics, Non tuberculous mycobacteria, Occurrence, Surgical infection

INTRODUCTION

Mycobacterium species belong to the family of Mycobacteriaceae and genus *Actinobacteria*. They are classified into three major types namely, *M.tuberculosis* complex, *M.leprae* and Non Tuberculous *Mycobacterium* (NTM). Synonymously referred to as atypical mycobacteria and currently termed as Rapidly Growing Mycobacteria (RGM), are omnipresent and has a global prevalence. They are even referred by other terms such as *Mycobacterium* other than tubercle bacilli (MOTT), anonymous (or) unclassified mycobacteria, tuberculoid or paratubercle bacilli. Their habitat is water or soil, while opportunistically infecting human beings [1].

Atypical *mycobacterium* is gaining clinical importance in the recent years with enhanced frequencies of outbreaks and pseudo-outbreaks, and incidence of cases in healthcare set up. Majority of the times, infections resulting from this group of organism are a resultant of non adherence to sterilisation procedure of medical equipment or surgical devices [2].

The RGM infection presents similar to tuberculosis with reduced morbidity. A definitive diagnosis is made on the basis of culture and Deoxyribonucleic Acid (DNA) sequencing as they do not totally respond to standard Admission, Transfer and Discharge (ATD) [3]. An increase in NTM infection reporting is due to improved histopathological and cultural technique and DNA sequencing for species level diagnosis [4]. Literature evidence shows an incidence of 3.4% to 24.7% in Indian population [5,6].

These infections have greater clinical implications as they easily mimic pyogenic bacterial infections making it difficult to treat [7]. Predisposing factors to RGM include surgical procedures, pulmonary disorders in old age and a suppressed immune system. These infections have a protracted course, thus demanding prolonged therapy and surgical intervention [5]. Hence, this review was conducted to answer the research question “What is the occurrence and progress of RGM infection in postsurgical wounds?”

MATERIALS AND METHODS

Protocol and registration: The present review followed the Preferred Reporting Items for Systematic Reviews and Meta-Analyses (PRISMA) checklist protocol utilised for reporting systematic reviews and quantitative analysis [8].

Eligibility Criteria

The research question was focused using the Population, Intervention, Comparison, Outcomes and Study (PICOS) framework.

Population- Adult patients, of both genders with postsurgical wounds.

Intervention- Development of atypical mycobacterium during the period of observation.

Comparison- Not applicable.

Outcome- Occurrence of atypical mycobacteria was the primary outcome assessed. Secondary outcomes evaluated were recurrence and complications.

Study design- Clinical Trials, Retrospective or prospective cohort study, case-control study.

Inclusion criteria: Studies, both prospective and retrospective types which assessed the pre-determined outcome of atypical *mycobacterium* in postsurgical wound patients published in English language were included. Studies reporting on patients with any type of surgery amongst adults were analysed.

Exclusion criteria: Editorials, case reports, commentaries, animal studies and articles written in language other than English were excluded.

Information Sources

Search engines like MEDLINE, Ovid, Google Scholar, Scopus and Journal on web databases were searched for literature. All searches were performed through EBSCO (last accessed on

August 22nd, 2021). All relevant articles identified, which were obtained in full text, via electronic and other search methods were checked. Abstract and conference proceedings were used to search and identify unpublished studies. Literature search was set from March 2010 to December 2020 as the concluding year, with only sources in English incorporated.

Search Strategy

Keywords: Key terms used for the present search included “atypical mycobacteria”; “NTM”; “rapidly progressing mycobacteria”; “RGM”; “postsurgical wounds”; “surgical site infection”; “wound site”; “port hole infections” [Table/Fig-1].

1.	Atypical mycobacteria and surgical site infection or wound site or port hole infection
2.	Non <i>tuberculous mycobacteria</i> (NTM) and surgical site infection or wound site OR port hole infection
3.	Rapidly progressing mycobacteria and surgical site infection or wound site OR port hole infection
4.	Rapidly Growing Mycobacteria (RGM) and surgical site infection or wound site or port hole infection

[Table/Fig-1]: Combinations of keywords used for search.

Boolean operators: The Boolean operator ‘OR’ was employed to complement truncated synonyms in each search theme. The Boolean operator ‘AND’ makes up the sum of each four main search themes to specifically output papers which give at least one result for each time.

Process of study identification: Endnote X8 was used to import the results of the search data and to remove the duplicates. The screening of abstracts was carried out by the use of the eligibility criteria and for those not excluded, full text articles were searched for. These were, then, assessed for inclusion and upon acceptance, underwent data extraction and quality assessment. Articles failing to meet inclusion criteria, were omitted.

Data collection: All the title and the abstracts were independently screened by the reviewers and upon a meticulous review of the full text articles, the data were extracted and documented in a data extraction table, which shows depicting data items evaluated for the review.

Data items: The data extraction table included study identification (ID), study location, confirmed cases of RGM, clinical presentation, confirmation, organism isolated, recurrence rate, complications and study design.

Quality assessment of included studies: Modified Newcastle Ottawa scale for case-control and cross-sectional studies were employed to evaluate for the quality of included studies. The scale checked for three criteria;

- Selection criteria (representativeness of exposed cohort, selection of non exposed group, ascertainment of exposure);
- Comparability and
- Outcome (assessment, follow-up period and adequacy).

The study was graded of high quality when scored 7 and above, and of medium quality when scored 5 [9].

Reviewers: Two reviewers (AM and SM) assessed the quality of every study independently. Any disagreement which arose between the two was resolved by open discussion with a third reviewer (JP).

Study identification (ID)	Location	Study population	Confirmed cases/ Occurrence	Clinical presentation	Organism isolated	Treatment rendered	Recurrence	Complications	Study design
Pinheiro PYM et al., 2019 [11]	Brazil	125 patients in Infectiology Service of Hospital Universidade Federal Fluminense, operated for cholecystectomy and gynaecological reasons between April 2007 to 2009	125	86.4% presented with wound drainage and peri-surgical nodules noted in 65.6%	<i>M. Massiliense</i> , <i>M. mageritense</i> and <i>M. Fortuitum</i>	Clarithromycin and Amikacin	No relapse in two years follow-up	None	Retrospective multicentric (10 private hospitals)

Data synthesis: A total of 10 articles were qualitatively and quantitatively analysed.

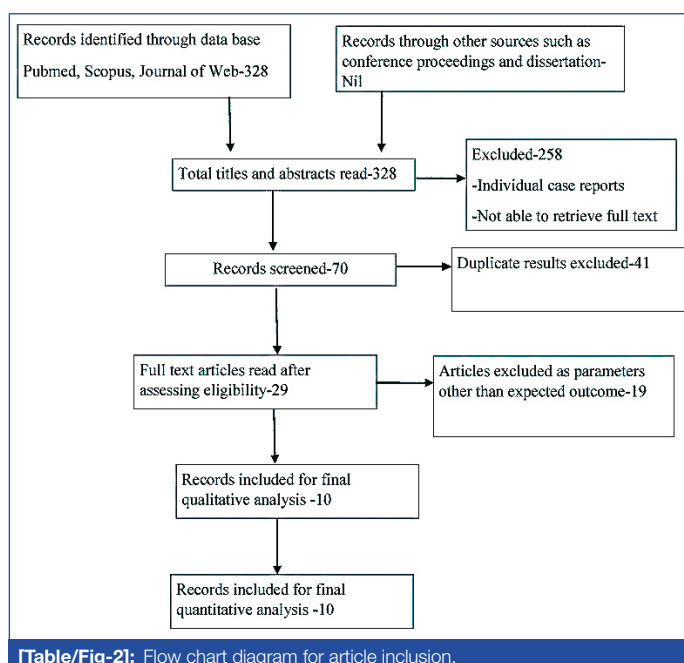
STATISTICAL ANALYSIS

Open meta-analyst software [10] was used for performing meta-analyses for prevalence of RGM in postsurgical site wounds. The heterogeneity of included studies was evaluated using Cochrane Q and the I². Cochrane Q with p-value <0.10 and I² >50 was taken as standard to indicate the presence of heterogeneity of included studies. Based on the results, the random effects or fixed model was used to combine included studies.

Risk of bias: The Newcastle Ottawa Quality assessment tool was used to evaluate the quality of the studies included.

RESULTS

A total of 328 manuscripts were extracted from search results. A total of 258 articles were removed due to the non availability of full texts. A total of 41 studies were further eliminated because of duplication. Another 19 had to be removed as they reported cases of only RGM specifically in surgical wounds. After checking for the eligibility, 10 articles were included for both qualitative and quantitative evaluation [Table/Fig-2].



[Table/Fig-2]: Flow chart diagram for article inclusion.

Ten observational studies fulfilling the eligibility criteria were used for the present analysis. Out of the eligible studies, six were reported from India, two from Korea and two from Brazil. Seven of them were of prospective nature and three of retrospective type.

Data characteristics of each study are presented in [Table/Fig-3] [11-20]. All of them were of fair quality when assessed on Ottawa scale [Table/Fig-4] [11-20]. A total of 592 sample were analysed, out of which 241 cases of NTM were detected accounting to a prevalence of 56.40% (95% CI-33.0; 79.80) at p-value <0.001, which was highly significant [Table/Fig-5]. The most commonly detected microbes were *M.Chelonae*, *M.Abscessus* and *M.fortuitum*. One study reported *M.massiliense* and *M.mageritense* organism. *M.massiliense*

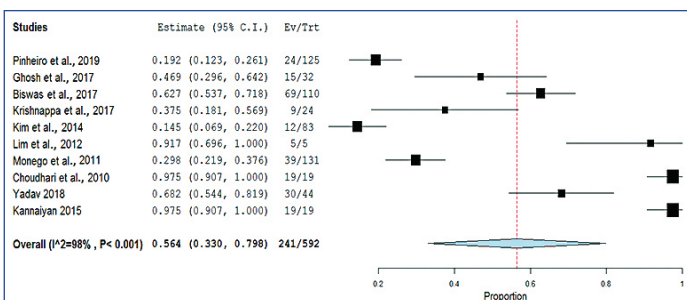
Ghosh R et al., 2017 [12]	India	32 patients, experiencing postsurgical wounds following laproscopic surgery in Surgery department of a teaching hospital of Kolkata from January 2015 to March 2016	15	Lengthened wound healing, Wound breakdown post initial healing, redness or discharge, nodules in or around the vicinity of the wounds	<i>M. Abscessus</i> , <i>M. Fortuitum</i>	Clarithromycin, Amikacin and Imipenem	None	Not mentioned	Prospective study
Biswas P et al., 2017 [13]	India	110 patients with Surgical Site Infections following surgeries of herniorrhaphy, cholecystectomy, appendectomy and gastrectomy from November 2012 to April 2013	87	Nodular cutaneous lesions and abscesses at incision area which progressed later to chronic discharging sinus	<i>M. abscessus</i> -61 <i>M. fortuitum</i> with 19 <i>M. chelonae</i> - 7	Organisms were sensitive to Imipenem, Linezolid, Amikacin and Ciprofloxacin	None	None	Prospective study
Krishnappa R and Samarasam I, 2017 [14]	India	35 patients admitted to Christian Medical College, Vellore, with chronic surgical site infection a five year duration	9		<i>M. Fortuitum</i> and <i>M. Chelonae</i>	Surgical debridement and long term antibiotic administration (Ciprofloxacin, Clarithromycin and Amikacin)	3 out of 24 cases shows recurrence	No other complications	Retrospective study
Kim HR et al., 2014 [15]	Korea	83 patients with postsurgical skin and subcutaneous infection not responding to standard treatment protocols	12	Presented with erythema, abscess and sinus tract at infection site	<i>M. Fortuitum</i> , <i>M. Chelonae</i> and <i>M. Abscessus</i>	Surgical debridement and combined antibiotics (Clarithromycin and Moxifloxacin)	None	None	Retrospective study
Lim JM et al., 2012 [16]	Korea	5 patients observed between January 2009 to December 2010 after surgical procedure presenting with abscesses and chronic inflammation	5	Erythematous nodules, induration, pustules and abscess	<i>M. Fortuitum</i> , <i>M. Abscessus</i> and <i>M. conceptionense</i>	Amikacin, Ciprofloxacin and Cefazolin during hospitalisation followed by Clarithromycin when discharged	None	None	Prospective study
Monego F et al., 2011 [17]	Brazil	131 patients in 7 major private hospitals of Curitiba medical university	39	Abscess in surgical site	<i>M. massiliense</i>	Amikacin and Clarithromycin	None	None	Prospective study
Choudhuri S et al., 2010 [18]	India	19 patients (16 females: 3 males) in median age of 42.5 years	19	Erythematous swelling and pus discharge	Not mentioned specifically	Majority were susceptible to Clarithromycin and Ciprofloxacin	None	None	Prospective study
Yadav RP et al., 2018 [19]	India	44 patients in 2 different private hospitals in Jhapa district of Nepal in the mean age of 28.4 years.	30 (confirmed with AFB staining)		<i>M. Chelone</i>	Antibiotic combination- Clarithromycin and Tobramycin			Prospective study
Kannaiyan K et al., 2015 [20]	India	19 patients (13 females; 6 males) between 18-60 years after C-section, hernioplasty, laproscopy and reduction mammoplasty presenting to Aarupadai Veedu Medical College from October 2012 to September 2013	19	Sinus tract, non healing ulcers, subcutaneous abscesses, subcutaneous fluctuant or firm nodules of varying size, and erythema in association with ulcers or chronic drainage from prior surgical wounds	<i>M. fortuitum</i> and <i>M chelonae</i>	Amikacin, Linezolid and Clarithromycin	2 cases of recurrence	None	Prospective study

[Table/Fig-3]: Data characteristics of included studies [11-20].

Study identification (ID)	Is the case design adequate?	Selection			Comparability of cases and controls	Ascertainment of exposure	Outcome		Total score
		Case representativeness	Control selection	Definition of controls			Same method of ascertainment	Non response	
Pinheiro PYM et al., [11]	*	*	-	-	-	**	*	-	5
Ghosh R et al., [12]	*	*	-	-	-	**	*	-	5
Biwas P et al., [13]	*	*	-	-	-	**	*	-	5
Krishnappa R and Samarasam I, [14]	*	*	-	-	-	**	*	-	5
Kim HR et al., [15]	*	*	-	-	-	**	*	-	5
Lim JM et al., [16]	*	*	-	-	-	**	*	-	5
Monego F et al., [17]	*	*	-	-	-	**	*	-	5

Choudhuri S et al., [18]	*	*	-	-	-	**	*	-	5
Yadav RP et al., [19]	*	*	-	-	-	**	*	-	5
Kannaiyan K et al., [20]	*	*	-	-	-	**	*	-	5

[Table/Fig-4]: Ottawa rating for included studies [11-20].



[Table/Fig-5]: Forest plot depicting prevalence of Rapidly Growing Mycobacteria (RGM).

was also isolated in another study. The organisms were sensitive to commonly administered antibiotics like clarithromycin, amikacin, ciprofloxacin, imipenem and linezolid.

The I^2 results showed a heterogeneity of 98% at p -value <0.001. Hence, we used the continuous random effect model. The variance in the studies could be attributed to difference in methodological procedures, sample size and geographical variation.

DISCUSSION

Rapidly growing mycobacteria have surfaced as imperative human host pathogens, resulting in several infections in both healthy and immunocompromised individuals. The infection mostly arises after surgeries, injections of intramuscular types, penetrating traumatic conditions getting contaminated with soil and water. The last three decades have witnessed an increase in reporting of these organisms following surgery and traumatic abrasions and even in infections because of contaminated instruments.

The present review demonstrated a greater prevalence (56.4%) of RGM infection in postsurgical wounds, suggesting a higher risk. The present review records a slightly higher occurrence of RGM, which demonstrates an increasing trend of this infection over the years across the globe. Clinical presentation varied from abscess, nodules, induration and discharging sinus which also correlated with delay from initial manifestations to diagnosis due to late reporting. Overt systemic illness was rarely noted in the studies included. The onset of symptoms in most of our studies was between 3-4 weeks which corresponds to the duration of incubation period.

As reported in results, most of the infections were noted in closed surgeries such as laparoscopic procedure. Literature evidence also supports these findings [21,22]. This is due to the incubation layer on the instruments restricting the usage of autoclave for sterilisation purposes. Additionally improper cleaning of instruments leaves beyond blood deposits and charred tissue accumulating at the instrument joints. These act as hub for endospores, which traverses to subcutaneous tissues during surgeries [14]. They germinate later to appear as clinical symptoms after an incubation period of 3-4 weeks [18].

Furthermore, the source of infection is often the boiled tap water used for cleansing of the instruments after immersion in glutaraldehyde. Literature also documents that immersion of laparoscope equipment in 2-2.5% glutaraldehyde solution does not attain sterilisation [22].

Studies support the use of ethylene oxide gas sterilisation which is effective in reduction of RGM following laparoscopic procedures. A strong recommendation in this regard is for disposable laparoscopic instrument usage as in Western nations. Advanced sterilisation techniques like STERRAD™ utilising gas plasma technology aiming spores at lower temperatures is also beneficial [23].

M. fortuitum, *M. chelonae* and *M. abscessus* were the most commonly isolated organism in the present analysis. The study of Kim HR et al., also demonstrated *Stenotrophomonas maltophilia*, bacterial infection of uncommon occurrence which was treated with moxifloxacin intravenously [15]. *M. massiliense* was the uncommon organism not corroborating with existing studies. Previous studies have mentioned resistance to glutaraldehyde based disinfectants because of defects in porin expression. Porins are cell wall proteins seen in Mycobacteria which facilitates channels allowing passage of small hydrophilic molecules including antibiotics, via the highly hydrophobic mycobacterial cell wall [24,25]. In addition, mutations add on to defect in porin expression preventing antibiotic delivery into the cell of the organism, thus rendering resistance [26]. It has hence been suspected that prolonged exposure to disinfectants containing glutaraldehyde enhances drug resistant in RGM strains.

Majority of the patients were given combination antibiotics. Antibiotic intervention for NTM is of debatable concern. Generally, second line antitubercular TB drugs are used in combination because of resistance to first line medication. Duration of treatment ranged from six weeks to four months.

Ottawa scale employed in the current review is most commonly employed for assessing quality and risk of bias in observational studies. It is a validated tool, with quick application in case-control and longitudinal studies [27,28].

Limitation(s)

However, the review has certain limitations. The studies analysed had an unclear element of randomisation which could alter the effect of prognostic factors on outcome and thus, in turn questions the generalisability of the results. In this context, a great demand for multicentre trials adopting precise randomisation and standardised methodology ensuring high quality studies arises. A factor unexplained is the selective or sporadic cases getting infected despite normal immune system and no predisposing medical disorder. Hence forth, studies are recommended that focus on other variables which could predispose to infection.

CONCLUSION(S)

Rapidly growing mycobacterium have been an emerging infectious spectrum, particularly in the Asian continent. With a prevalence of 56.40%, it has a higher tendency to affect infected surgical sites. The most commonly detected organisms include *M. fortuitum*, *M. chelonae* and *M. abscessus* which are resistant to antibiotics. Early diagnosis, utilisation of appropriate antibiotics based on susceptibility tests, and appropriate surgical intervention are the keys to this issue.

REFERENCES

- [1] Ananthanarayanan, Paniker. Textbook of Microbiology. Universities press. 8th edition.
- [2] Desai AN, Hurtado RM. Infections and outbreaks of non tuberculous mycobacteria in hospital settings. *Curr Treat Options Infect Dis*. 2018;10(2):169-81.
- [3] Umrao J, Singh D, Zia A, Saxena S, Sarsaiya S, Singh S, et al. Prevalence and species spectrum of both pulmonary and extrapulmonary nontuberculous mycobacteria isolates at a tertiary care center. *Int J Mycobacteriol*. 2016;5(3):288-93.
- [4] Maurya AK, Nag VL, Kant S, Kushwaha RA, Kumar M, Singh AK, et al. Prevalence of nontuberculous mycobacteria among extrapulmonary tuberculosis cases in tertiary care centers in northern India. *Biomed Res Int*. 2015;2015:465403.
- [5] Gundavda MK, Patil HG, Agashe VM, Soman R, Rodrigues C, Deshpande RB. Nontuberculous mycobacterial infection of the musculoskeletal system in immunocompetent hosts. *Indian J Orthop*. 2017;51:205-12.
- [6] Karak K, Bhattacharyya S, Majumdar S, De PK. Pulmonary infection caused by Mycobacteria other than *M. tuberculosis* in and around Calcutta. *Indian J Pathol Microbiol*. 1996;39(2):131-34.

- [7] Romero FA, Powell EA, Babady NE, Kaltsas A, Figueroa CJ, Pulitzer M, et al. Nontuberculous mycobacterial infections after silicone breast implant reconstruction emphasize a diversity of infecting mycobacteria. *Open Forum Infect Dis.* 2017;4(4):ofx189.
- [8] Moher D, Liberati A, Tetzlaff J, Altman DG, PRISMA Group (2009) Preferred reporting items for systematic reviews and meta-analyses: The PRISMA statement. *PLoS Med* 6.
- [9] Wells G, Shea B, O'Connell J, Robertson J, Peterson V, Welch V, et al. Full-text. NewcastleOttawa scale assess. Qual. Nonrandomised Stud. Meta-analysis. Available http://www.evidencebasedpublichealth.de/download/Newcastle_Ottawa_Scale_Pope_Bruce.pdf.
- [10] Wallace BC, Dahabreh IJ, Trikalinos TA, Lau J, Trow P, Schmid CH. Closing the gap between methodologists and end-users: r as a computational back-end. *Journal of Statistical Software.* 2012;49(5):01-15.
- [11] Pinheiro PYM, Setúbal S, Oliveira SA. Postsurgical atypical mycobacteriosis in 125 patients in Rio de Janeiro. *Rev Soc Bras Med Trop.* 2019;52:e20190039.
- [12] Ghosh R, Das S, De A, Kela H, Saha ML, Maiti PK. Port-site infections by nontuberculous mycobacterium: A retrospective clinico-microbiological study. *Int J Mycobacteriol.* 2017;6:34-37.
- [13] Biswas P, Gupta A, Sriram R. Rapidly growing mycobacteria an often overlooked cause of surgical site infections. *Int J Curr Microbiol App Sci.* 2017;6(5):2777-82.
- [14] Krishnappa R, Samarasam I. Atypical mycobacterial infection in post laparoscopy surgical wounds: Our observations and review of literature. *Int Surg J.* 2017;4:2943-46.
- [15] Kim HR, Yoon ES, Kim DW, Hwang NH, Shon YS, Lee BI, et al. Empirical treatment of highly suspected nontuberculous mycobacteria infections following aesthetic procedures. *Arch Plast Surg.* 2014;41:759-67.
- [16] Lim JM, Kim JH, Yang HJ. Management of infections with rapidly growing mycobacteria after unexpected complications of skin and subcutaneous surgical procedures. *Arch Plast Surg.* 2012;39:18-24.
- [17] Monego F, Duarte RS, Nakatani SM, Araújo WN, Riediger IN, Brockelt S, et al. Molecular identification and typing of *Mycobacterium massiliense* isolated from postsurgical infections in Brazil. *Braz J Infect Dis.* 2011;15(5):436-41.
- [18] Choudhuri S, Sarkar D, Mukherji R. Diagnosis and management of atypical mycobacterial infection after laparoscopic surgery: *Indian J Surg.* 2010;72(6):438-42.
- [19] Yadav RP, Baskota B, Ranjitkar RR, Dahal S. Surgical site infections due to non tuberculous mycobacteria. *J Nepal Med Assoc.* 2018;56(211):696-700.
- [20] Kannaiyan K, Ragnathan L, Sakthivel S, Sasidar AR, Muralidaran, Venkatachalam GK. Surgical site infections due to rapidly growing mycobacteria in Puducherry, India. *Journal of Clinical and Diagnostic Research.* 2015;9(3):DC05-08.
- [21] Muthusami JC, Vyas FL, Mukundan U, Jesudason MR, Govil S, Jesudason SR. *Mycobacterium fortuitum*: An iatrogenic cause of soft tissue infection in surgery. *ANZ J Surg.* 204;74(8):662-66.
- [22] Chauhan A, Gupta AK, Satyanarayan S, Jena J. A case of nosocomial atypical mycobacterial infection. *MJFAI.* 2007;63:201-02.
- [23] Vijayraghavan R, Chandrashekhar R, Sujatha Y, Belagavi CS. Hospital outbreak of atypical mycobacterial infection of port sites after laparoscopic surgery. *J Hosp Infect.* 2006;64(4):344-48.
- [24] Svetilkova Z, Skovierova H, Niederweis M, Gaillard JL, McDonnell G, Jackson M. Role of porins in the susceptibility of *Mycobacterium smegmatis* and *Mycobacterium chelonae* to aldehyde based disinfectants and drugs. *Antimicrob Agents Chemother.* 2009;53(9):4015-18.
- [25] Mukhopadhyay S, Basu D, Chakrabarti P. Characterization of a porin from *Mycobacterium smegmatis*. *J Bacteriol.* 1997;179(19):6205-07.
- [26] Danilchinka O, Pavlenov M, Niederwies M. Role of porins in the uptake of antibiotics by *Mycobacterium smegmatis*. *Antimicrob Agents Chemother.* 2008;52(9):3127-34.
- [27] Luchini C, Stubbs B, Solmi M, Veronese N. Assessing the quality of studies in meta-analyses: Advantages and limitations of the Newcastle Ottawa Scale. *World J Meta-Anal.* 2017;5(4):80-84.
- [28] Stang A. Critical evaluation of the Newcastle-Ottawa scale for the assessment of the quality of nonrandomized studies in meta-analyses. *Eur J Epidemiol.* 2010;25:603-05.

PARTICULARS OF CONTRIBUTORS:

1. Medical Director and Professor, Department of General Surgery, People's College of Medical Science and Research Centre, Bhopal, Madhya Pradesh, India.
2. Professor and Head, Department of Oral Pathology, People's College of Dental Science and Research Centre, Bhopal, Madhya Pradesh, India.
3. Director and Professor, Department of General Surgery, MGM Institute of Biosciences and Technology, Aurangabad, Maharashtra, India.
4. Associate Professor, Department of Microbiology, People's College of Medical Science and Research Centre, Bhopal, Madhya Pradesh, India.
5. Project Assistant, Department of Medicine, ICMR, Bhopal, Madhya Pradesh, India.

NAME, ADDRESS, E-MAIL ID OF THE CORRESPONDING AUTHOR:

Shubhangi Mhaske,
Professor and Head, Department of Oral Pathology, People's College of Dental Science and Research Centre, Bhopal, Madhya Pradesh, India.
E-mail: mhaske_shubhangi@yahoo.com

PLAGIARISM CHECKING METHODS: [Lain H et al.](#)

- Plagiarism X-checker: Sep 29, 2021
- Manual Googling: Oct 08, 2021
- iThenticate Software: Nov 06, 2021 (17%)

ETYMOLOGY: Author Origin

AUTHOR DECLARATION:

- Financial or Other Competing Interests: None
- Was Ethics Committee Approval obtained for this study? No
- Was informed consent obtained from the subjects involved in the study? No
- For any images presented appropriate consent has been obtained from the subjects. No

Date of Submission: **Sep 28, 2021**

Date of Peer Review: **Oct 20, 2021**

Date of Acceptance: **Nov 08, 2021**

Date of Publishing: **Dec 01, 2021**