

# Live Pregnancy with Chronic Abruption-oligohydramnios Sequence: A Case Report

PRAGATI JAIN<sup>1</sup>, REENA YADAV<sup>2</sup>, NISHTHA JAISWAL<sup>3</sup>, KIRAN AGARWAL<sup>4</sup>

## ABSTRACT

Chronic Abruption-Oligohydramnios Sequence (CAOS) is a diagnosis during pregnancy, which is characterised by chronic antepartum haemorrhage and oligohydramnios. The CAOS affects foetal outcome as it is associated with preterm delivery and high chances of foetal mortality. Chronic abruption should be judiciously differentiated from other acute cause of antepartum haemorrhage and bleeding in early trimester. Here, a very rare entity of CAOS was reported, in which a 22-year-old primigravida presented at 29 weeks of gestation with a live pregnancy. Ultrasound was done which showed a live foetus of 27 weeks gestation, with reduced liquor (Amniotic Fluid Index (AFI)=2-3) with intra-placental collection of depth (7cm) and a large retroplacental collection (9.2×6.7 cm). In the present case, timely intervention and decision for termination, lead to favourable foetal and maternal outcomes. As CAOS is related with high foetal mortality, interventions to expedite foetal lung maturity should be planned and weighing upon the maternal and foetal outcomes, termination should be considered.

**Keywords:** Live birth, Placenta, Prematurity, Vaginal bleeding

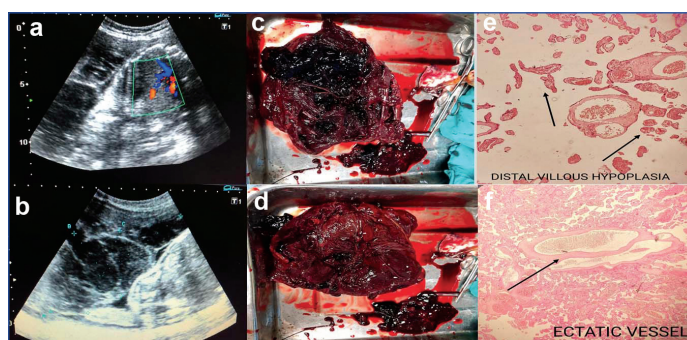
## CASE REPORT

A 22-year-old primigravida visited antenatal clinic at 29 weeks of gestation for a routine check-up with history of one episode of minimal bleeding per vaginum one day prior. There was no history of leaking per vaginum or abdominal trauma or recent intercourse. No other significant past, personal, or family history was noted. On clinical examination her vitals were stable. Abdominal examination revealed gravid uterus with fundal height corresponding to 30-32 weeks period of gestation and normal basal tone of uterus. There was no active bleeding seen on per speculum examination. Ultrasound was done which showed a live foetus of 27 weeks gestation, with reduced liquor (AFI=2-3) with intra-placental collection of depth 7cm and a large retroplacental collection of 9.2×6.7 cm [Table/Fig-1a,b].

The patient was haemodynamically stable with mild anaemia (Haemoglobin 10.2 g/dL) found upon investigations. Eventually, the diagnosis of chronic abruption with oligohydramnios sequence was made on the basis of clinical examination and ultrasound findings. Decision for termination of pregnancy was taken keeping in concern the risks of maternal and foetal outcome in continuing the pregnancy. The risks associated with the preterm baby and its long term consequences was explained to the patient. Dexamethasone injections were given to enhance foetal lung maturity followed by induction of labour. Patient had preterm vaginal delivery at 30 weeks 3 days of gestation with baby weight of 866 gm and placental weight of 450 gms. There were retroplacental clot of 120 gm [Table/Fig-1c,d]. Placenta was sent for histopathological examination which showed subchorionitis in placental membranes, and both foetal and maternal surface of placenta showed ductal villous hypoplasia, ectatic vessel, areas of infarction and vascular congestion [Table/Fig-1e,f]. Baby was shifted to Neonatal Intensive Care Unit (NICU) postdelivery for one month and was discharged in satisfactory condition. The patient and baby both were followed-up after three months and six months and were in good health.

## DISCUSSION

Abruption complicates around 1% of all the pregnancies. Massive abruption with foetal death and maternal morbidity is seen in 10%



**[Table/Fig-1]:** a) Ultrasound doppler image showing live foetus with intra-placental haematoma; b) Ultrasound image of large retroplacental clot; c) Gross examination of placenta showing intra-placental clot on the maternal side of the placenta; d) Foetal surface of placenta with blood clot; e) Histopathological findings (100X) of the placenta (H&E stain) showing distal villous hypoplasia (top) and f) ectatic vessel.

of these occurring anytime during pregnancy. While 40% of these will occur at more than 37 weeks of gestation (term pregnancy) with remaining 50% occurring at a gestational age of less than 37 weeks (preterm pregnancy). Approximately, 30% of these preterm pregnancies will deliver within seven days of diagnosis of abruption [1]. About 20% of the remaining patients will continue pregnancy beyond seven days and are diagnosed to have chronic abruption with potential risk for developing CAOS [2]. The CAOS was originally defined by Elliott JP et al., by the following criteria: clinically significant vaginal bleeding in the absence of placenta previa or other identifiable source of bleeding, amniotic fluid volume initially documented as normal and oligohydramnios (AFI  $\leq$  5 cm) eventually developing in absence of concurrent evidence of ruptured membranes [3-5]. The CAOS complicating pregnancy is associated with increased risk of preterm delivery and a high neonatal mortality rate because of associated respiratory complications like dry lung syndrome, pulmonary hypertension, and chronic lung disease [6,7]. The present report is a rare case of chronic abruption with a live pregnancy outcome at 29 weeks of gestation.

Approximately, 60% of patients with chronic abruption are found to have CAOS. There are two types of placental abruption: Arterial and Venous. Arterial separation mostly presents as acute maternal bleeding resulting in disseminated intravascular coagulation in mother and acute foetal distress leading to increased risk of

perinatal mortality. In contrast to this, venous separation which was also seen in index case has usually a less complicated clinical course during pregnancy with mild or no disturbance of the fetomaternal condition. Haemorrhage in the peripheral vein of the placenta results in development of CAOS. There is a subchorionic clot seen invariably on ultrasound in 75% of patients diagnosed with CAOS. Prolonged venous bleeding in placenta leads to formation of this subchorionic haematoma which further separates the amnion and the chorion away from the decidua. This results in decreased blood and nutrient supply to amnion and chorion. Subsequently, placental dysfunction leading to suboptimal foetal renal perfusion which may be responsible for the oligohydramnios. The separation of amnion and chorion eventually contributes to chorioamnionitis and premature rupture of the membranes in this group of patients.

In patients with CAOS the mean gestational age is 31 weeks at delivery when the first haemorrhage occurs at more than 20 weeks gestation. However, if the first bleeding occurs at less than 20 weeks gestation, CAOS results in delivery occurring 6.9 weeks earlier. The mean gestational age at delivery was 28 weeks in index case with CAOS. However, it is interesting to note and difficult to explain the low incidence of intrauterine growth retardation in these patients. In the study by Elliot JP et al., mean age of first episode of bleeding was 19.4 weeks and mean age of delivery was 28 weeks which was similar to what was observed in index case [3]. Another similar case was also reported as index case by Grace K and Peterson R in which patient presented with haemorrhage around 22 weeks and by comprehensive holistic care and complete bed rest, there was a live and healthy baby and mother at 33 weeks [8].

## CONCLUSION(S)

Pregnant women presenting with vaginal bleeding and oligohydramnios should be carefully examined with a detailed history, aided with an expert ultrasound for confirming the suspected clinical diagnosis. Timely intervention and keeping in mind the possibilities of adverse maternal and foetal risks can actually result in good maternal and foetal outcome. Careful evaluation should be done for status of foetal membranes as a reason for oligohydramnios. Since prematurity is very likely, delivery should be carried out at a centre where facilities of antepartum and intrapartum foetal surveillance as well as intensive newborn care are available.

## REFERENCES

- [1] Sholl JS. Abruptio placentae: Clinical management in non-acute cases. *Am J Obstet Gynecol.* 1987;156:40-51.
- [2] Bond AL, Edersheim TG, Curry L, Druzin ML, Hutson JM. Expectant management of abruptio placentae before 35 weeks gestation. *American Journal of Perinatology.* 1989;6(2):121-23.
- [3] Elliott JP, Gilpin B, Strong TH Jr, Finberg HJ. Chronicabruption-oligohydramnios sequence. *J Reprod Med.* 1998;43:418-22.
- [4] Shenker L, Reed KL, Anderson CF, Borjon NA. Significance of oligohydramnios complicating pregnancy. *Am J Obstet Gynecol.* 1991;164(6 Pt 1):1597-99.
- [5] Ohyama M, Itani Y, Yamanaka M, Goto A, Kato K, Ijiri R, et al. Maternal, neonatal, and placental features associated with diffuse chorioamniotic hemosiderosis, with special reference to neonatal morbidity and mortality. *Pediatrics.* 2004;113(4):800-05.
- [6] Morita A, Kondoh E, Kawasaki K, Fujita K, Mogami H, Minamiguchi S, et al. Therapeutic amnioinfusion for chronic abruptio-oligohydramnios sequence: A possible prevention of the infant respiratory disease. *J Obstet Gynaecol Res.* 2014;40(4):1118-23.
- [7] Kobayashi A, Minami S, Tanizaki Y, Shiro M, Yamamoto M, Yagi S, et al. Adverse perinatal and neonatal outcomes in patients with chronic abruptio-oligohydramnios sequence. *J Obstet Gynaecol Res.* 2014;40(6):1618-24.
- [8] Grace K, Peterson R. Chronic abruptio oligohydramnios sequence. *J Obstet Gynaecol & Neonatal Nursing.* 2020;49(6):31. Doi: 10.1016/j.jogn.2020.09.053.

### PARTICULARS OF CONTRIBUTORS:

1. Senior Resident, Department of Obstetrics and Gynaecology, Lady Hardinge Medical College, New Delhi, India.
2. Director Professor and Unit Head, Department of Obstetrics and Gynaecology, Lady Hardinge Medical College, New Delhi, India.
3. Associate Professor, Department of Obstetrics and Gynaecology, Lady Hardinge Medical College, New Delhi, India.
4. Director Professor, Department of Pathology, Lady Hardinge Medical College, New Delhi, India.

### NAME, ADDRESS, E-MAIL ID OF THE CORRESPONDING AUTHOR:

Dr. Nishtha Jaiswal,  
203, Type 4 LHMC Faculty Flats, New Delhi, India.  
E-mail: nishtha.amu@gmail.com

### PLAGIARISM CHECKING METHODS: [Jain H et al.]

- Plagiarism X-checker: May 23, 2021
- Manual Googling: Oct 27, 2021
- iThenticate Software: Nov 19, 2021 (12%)

### ETYMOLOGY: Author Origin

### AUTHOR DECLARATION:

- Financial or Other Competing Interests: None
- Was informed consent obtained from the subjects involved in the study? Yes
- For any images presented appropriate consent has been obtained from the subjects. Yes

Date of Submission: **May 21, 2021**

Date of Peer Review: **Sep 30, 2021**

Date of Acceptance: **Oct 28, 2021**

Date of Publishing: **Dec 01, 2021**