

# Evaluation and Management of Suspicious Adnexal Masses in Pregnancy- A Retrospective Study

KAVITHA SUKUMAR<sup>1</sup>, DELPHIN SUPRIYA<sup>2</sup>, P USHA<sup>3</sup>

## ABSTRACT

**Introduction:** The incidence of suspicious ovarian masses in pregnancy is on the rise due to the increased use of ultrasonography in recent times. However little is known about their management during pregnancy due to the lack of large randomised trials.

**Aim:** To evaluate the incidence, nature and management of suspicious adnexal masses diagnosed during pregnancy at our institution.

**Materials and Methods:** This was a retrospective study of 33 pregnant women who presented with suspicious ovarian masses at the Department of Gynaec Oncology at the Institute of Obstetrics and Gynaecology, Madras Medical College, Chennai, Tamil Nadu, India, from August 2018 to September 2020. Patients were evaluated with imaging studies as per the International Ovarian Tumour Analysis (IOTA) ultrasound rules

along with Magnetic Resonance Imaging (MRI) and tumour markers and surgical intervention were performed for cases with definite indications. The Statistical Package for Social Science (SPSS) version 28.0 was used for statistical analysis.

**Results:** Mean age of the patients was 26.1±2.1 years (20-33 years). Most common gestational age of presentation was the 2<sup>nd</sup> trimester of pregnancy (mean-18.9 weeks). Out of 33 patients, 27 were benign (81.82%) and 6 (18.18%) malignant. Surgical intervention was done for 18 cases (54.55%) and 15 (45.45%) patients were kept under observation. Five were primary ovarian and one was metastatic from carcinoma stomach.

**Conclusion:** Thorough clinical evaluation with personalised imaging and appropriate timely intervention aid in the diagnosis and management of suspicious adnexal masses in pregnancy.

**Keywords:** Carcinoma ovary in pregnancy, Chemotherapy in pregnancy, International ovarian tumour analysis group, Ovarian mass in pregnancy

## INTRODUCTION

The incidence of ovarian masses in pregnancy is around 0.2-2%, malignancy rate is 1-6%, vast majority of these masses are benign. Most adnexal masses are identified during routine pregnancy ultrasonography [1]. With the widespread use of ultrasonography in pregnancy, the detection rates of suspicious ovarian masses have increased. In general, most adnexal masses are discovered in the first two trimesters of pregnancy, usually in the first trimester early pregnancy scan. 65-80% of these masses are asymptomatic [2]. Most functional cysts regress spontaneously when observed in subsequent scans. However, surgical intervention would be needed in all ovarian masses with imaging features suspicious of malignancy, those that significantly increase in size and those that present with acute pain during pregnancy [3].

Ovarian malignancy in pregnancy is very rare. Irrespective of the gestational age at diagnosis, an ovarian malignancy warrants immediate intervention keeping in mind the well-being of the mother [3]. However, possibility of continuation of pregnancy alongside treatment of the ovarian carcinoma has also been discussed in several case reports [4,5]. In the absence of large prospective randomised trials and cohort studies, there are no standard guidelines for management of these patients. It is necessary to identify surgical strategies with or without antenatal chemotherapy that results in safe oncologic and foetal outcomes. This study was thus undertaken, to help establish institutional guidelines for the management of suspicious ovarian masses complicating pregnancy.

## MATERIALS AND METHODS

The present study was a single centre retrospective study conducted in the Department of Gynaec Oncology at the Institute of Obstetrics and Gynaecology, Madras Medical College, Chennai, Tamil Nadu, India, by

reviewing the departmental records of patients diagnosed and treated with suspicious ovarian masses between August 2018 to September 2020. The analysis of the data was done in October 2020.

**Inclusion criteria:** All patients diagnosed with suspicious adnexal masses in pregnancy that satisfy the IOTA M (Malignant) rules and those that were considered inconclusive according to IOTA classification were included in the study [6]. The criteria also included ovarian masses which showed rapid increase in size in successive scans and/or presence of ascites or evidence of extra ovarian disease.

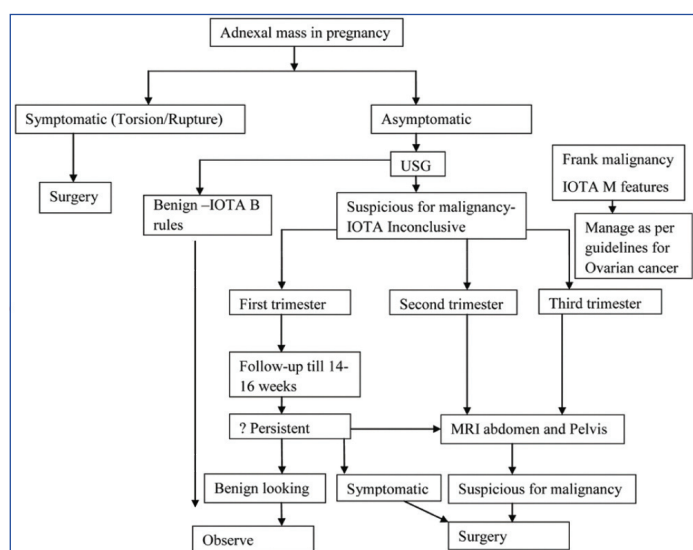
**Exclusion criteria:** Benign looking cysts that satisfy the IOTA B (Benign) rules, small (size ≤5 cm) cysts, simple/functional cysts and dermoid cysts or endometriotic cysts with typical imaging features were excluded.

Patient records were verified for demographic characteristics, Ultrasonography (USG) features, Ca125 (cancer antigen 125) and Carcinoembryonic Antigen (CEA) levels and Magnetic Resonance Imaging (MRI) abdomen and pelvis if available. Other specific tumour markers were noted if done. Masses diagnosed in first trimester were followed-up if not suggestive of malignancy.

Surgical intervention was done in selected cases. The criteria for surgical intervention included large masses ≥10 cm, masses suspicious of malignancy and those that increased in size when observed from the first trimester through the second trimester. Also, cases that presented with acute abdominal pain suggestive of torsion or rupture were taken up for emergency laparotomy irrespective of the gestational age. Elective laparotomies were done between 16 to 18 weeks as second trimester of pregnancy is considered to be the safest for surgical intervention. Those who did not meet the criteria for surgical intervention were kept under close follow-up with monthly ultrasonogram.

For those who underwent surgical intervention, a fertility sparing staging including peritoneal washings cytology, thorough inspection and palpation of entire abdominal cavity, Unilateral Salpingo-oophorectomy, pelvic peritoneal biopsies and infracolic omentectomy was done. Use of “hands off the Uterus” technique was ensured for safe handling of the uterus to reduce the risk of miscarriage and preterm labour [7]. Postoperatively patients received progesterone supplements and uterine tocolytics according to their gestational age.

The final histopathology and clinical outcomes were analysed. Those patients who were reported to have malignancies on histopathology were counselled regarding the options of continuation of pregnancy, need for chemotherapy during pregnancy, risks to the foetus, prognosis and probable stage of the disease, the need for completion surgery at the time of delivery, the need for further adjuvant chemotherapy and the risk of recurrence post delivery. Follow-up records of the cases were analysed with regards to recurrence and survival. The mean follow-up was 18 months. The institutional protocol deciphered through present study is as follows [Table/Fig-1].



**[Table/Fig-1]:** Institutional protocol for management of suspicious adnexal masses in pregnancy.

### STATISTICAL ANALYSIS

The Statistical Package for Social Science (SPSS) version 28.0 was used for statistical analysis.

### RESULTS

There were 33 patients with ovarian masses complicating pregnancy, 30 were diagnosed during pregnancy and the other three were incidentally diagnosed at caesarean section. The incidence of suspicious ovarian masses in pregnancy was found to be 1/929 deliveries (from 2018-2020), from 30,657 deliveries at our hospital. Furthermore, the incidence of ovarian carcinomas in pregnancy was found to be 1 in 5109 deliveries.

The mean age of the study group was 26.1±2.1 years (20-33 years). Mean time of diagnosis of ovarian tumour was 18.9 weeks (range 8 to 40 weeks of gestational age). In the patients diagnosed during pregnancy, 72.7% (24/33) of cases were asymptomatic. Ca125 levels were available for 30 cases. It was normal in all but one case, which was a case of metastatic ovarian cancer with primary in the stomach. The mean value of Ca125 in present study was 18.4±2.7 U/l. Alpha Feto Protein was available for 22 cases and it was elevated in one case of germ cell tumour.

Intervention was done in 18 out of 33 cases (54.55%) of which 17 underwent uterus preserving staging laparotomy. One patient was a case of advanced carcinoma stomach diagnosed at eight weeks underwent Medical Termination of Pregnancy followed by chemotherapy. Among the 17 laparotomies, 15 were elective and two were emergencies in view of suspected torsion. The most common period of intervention was the second trimester (mean

gestational age at intervention 21.4±1.5 weeks) (Range 13-32 weeks). The characteristics of patients with ovarian mass during pregnancy were indicated in [Table/Fig-2].

Parameters	No. of patients	%
Age of the patient (years)	Mean age 26.1±2.1 (20-33)	
<b>Parity</b>		
Primigravida	22	66.67
Multigravida	11	33.33
<b>Time at diagnosis</b>		
First trimester	10	30.30
Second trimester	15	45.46
Third trimester	8	24.24
<b>Time of surgical intervention</b>		
First trimester	1	5.56
Second trimester	11	61.11
Third trimester	5	27.77
Puerperium	1	5.56
<b>Time of delivery</b>		
Term	30	90.91
Preterm	2	6.06
<b>Delivery mode</b>		
Normal vaginal delivery	21	63.64
Caesarean section	11	33.33
Yet to deliver (Antenatal)	1	3.03

**[Table/Fig-2]:** Characteristics of patients with ovarian mass during pregnancy.

Elective laparotomy was done between 16-18 weeks. However, 2 cases went in for emergency laparotomy, 1 at 12 weeks and another at 1 month postdelivery respectively in view of torsion.

Among the cases, decided for observation and follow-up (n=15) with monthly ultrasonogram, complete resolution of mass was observed in eight cases while significant regression in size was observed in five cases. These cases were followed upto six months postdelivery with serial ultrasound [Table/Fig-3].

Cases	n (%)
Mass resolved	8 (53.33%)
Mass regressed in size	5 (33.33%)
Under observation	1 (6.67%)
Lost follow-up	1 (6.67%)

**[Table/Fig-3]:** Cases kept under observation (N=15).

Among 18 patients who underwent surgical intervention, 12 (70.58%) cases turned out to be benign, four being serous tumours, five mucinous, one case of endometriotic cyst, one case of mucinous cystadenoma arising in a dermoid cyst and one case of hyper reactio leutealis.

Histological type	No. of patients (%)
Benign	Total- 12 (70.58)
Serous	4 (33.33)
Mucinous	5 (41.67)
Dermoid with mucinous differentiation	1 (8.33)
Endometriotic cyst	1 (8.33)
Hyper reactio leutealis	1 (8.33)
Malignancies	Total- 6 (35.29%)
	Primary ovarian-5 (83.33%)
	Metastatic-1 (16.67%)

**[Table/Fig-4]:** Histopathologic characteristics of patients who underwent surgery.

In spite of including only suspicious ovarian masses for evaluation, the final histopathology was still benign in 70.58% of cases [Table/Fig-4].

S. No.	Diagnosis	History	Management
1.	Clear cell carcinoma	-30 years, Primigravida -Bilateral complex ovarian mass -Uterus sparing staging at 13 weeks -Stage III a (microscopic omental deposits)	-4 cycles paclitaxel+carboplatin adjuvant chemotherapy -Cytoreduction along with Caesarean Section -Mother and baby well -On follow-up disease free for 3 years
2.	Mucinous cystadenocarcinoma	-24 years, Primigravida -Unilateral 25*25 cm mass -Uterus sparing staging at 20 weeks -Stage I C 3	-5 cycles adjuvant chemotherapy -Caesarean-section at 38 weeks -Not willing for completion surgery -Recurrence at four months postpartum -Expired due to disease 6 months postpartum
3.	Yolk sac tumour	-32 years, Primigravida -Unilateral complex mass at 22 weeks. U/L Salphingo-Oophorectomy done -Ascites+omental deposits -Stage III C	-3 cycles BEP (Bleomycin, Etoposide, Cisplatin) -C-section at 36 weeks -Not willing for completion surgery -Recurrence at 12 months postpartum -Underwent secondary cytoreduction and second line chemotherapy -Disease free for 2.5 years
4.	Recurrent immature teratoma	-32 years, G2P1L1/Previous LSCS -39+5 weeks with labour pains. Emergency Caesarean Section with Caesarean Section -History of unilateral Salphingo-Oophorectomy for immature teratoma at 19 years	-Advised completion surgery -Not willing for hysterectomy -Lost follow-up
5.	Low grade serous carcinoma	-29 years, Primigravida, 20 weeks+4 days -Unilateral complex ovarian mass 6x7 cm with solid areas -Uterus sparing staging at 20 weeks -Stage III A2	-On adjuvant chemotherapy with antenatal foetal surveillance -completion surgery at the time of delivery -Currently disease free
6.	Krukenberg tumour	-22 years, Primigravida, Bilateral complex mass at 8 weeks	-Upper GI scopy- Antral growth -Biopsy- Adenocarcinoma -MTP done at 8 weeks and referred for chemotherapy

**[Table/Fig-5]:** Management of the ovarian malignancies in pregnancy.

Six cases of ovarian malignancies were reported in present study, five of which were primary ovarian and one metastatic from stomach primary.

Of the five primary ovarian malignancies, 3 (60%) were epithelial carcinomas and 2 (40%) were germ cell tumours [Table/Fig-5]. Of the epithelial ovarian carcinomas seen, one case of clear cell carcinoma, one case of primary mucinous ovarian carcinoma and one case of low grade serous carcinoma respectively. There was one case of yolk sac tumour and one case of immature teratoma as well. There was one case of krukenberg tumour with primary in the stomach. Of these six patients with ovarian malignancies, four received chemotherapy during pregnancy; one underwent termination of pregnancy at 12 weeks (metastatic ca stomach); and one was a case of recurrent immature teratoma diagnosed at the time of caesarean section. The intraoperative picture of clear cell carcinoma is shown in [Table/Fig-6]. All four patients who had antenatal chemotherapy had full term delivery of healthy babies without any congenital malformations. Two patients (clear cell carcinoma and low grade serous carcinoma) underwent completion surgery in the form of hysterectomy and contralateral salphingoophorectomy at the time of delivery and the other two were kept under observation. Of the two patients who had fertility sparing treatment, the one with yolk sac tumour developed recurrence at 14 months after the first conservative surgery. She was treated with secondary cytoreduction and adjuvant second line chemotherapy. The patient with primary mucinous cystadenocarcinoma refused completion surgery at delivery and presented with recurrence at the para-aortic nodes four months postpartum. Since, she was

platinum resistant, she was started on second line chemotherapy, but she unfortunately progressed and succumbed to the disease six months postpartum.

The krukenberg case and immature teratoma were lost to follow-up. However, the other three ovarian malignancies are currently under follow-up and are disease free.

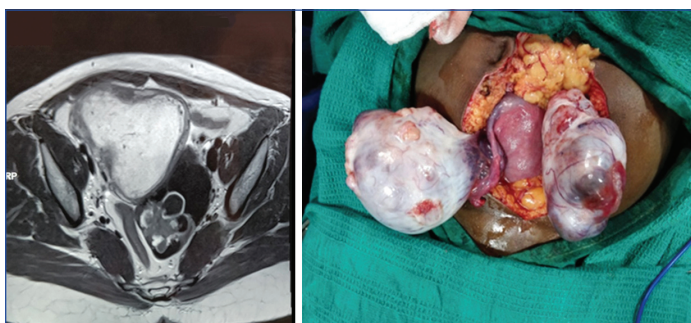## DISCUSSION

Detection of suspicious ovarian masses in pregnancy is usually incidental, often diagnosed by routine early pregnancy ultrasonogram. These patients however have the important advantage of being diagnosed at early stages of the disease, mostly stage 1 [8].

Functional cysts are the most common ovarian masses encountered in pregnancy [9]. Follicular cysts and haemorrhagic cysts are also common in pregnancy. All these were excluded from present study as these are clear cut benign conditions. The other most commonly encountered cystic adnexal lesion was mature cystic teratoma (dermoid cyst). These lesions are benign with <2% malignant transformation rate into invasive carcinoma [10]. Dermoid cysts have typical sonographic features which makes their diagnosis less doubtful. In present study, dermoid cysts with typical imaging findings were excluded. Therefore, only one case of mature cystic teratoma with mucinous differentiation was reported.

Endometrioma (chocolate cyst) can also occur in pregnancy with suspicious imaging findings and one such case has been reported in present study. Endometriomas can have altered appearance in imaging during pregnancy because of decidualised walls due to high levels of progesterone [11]. A previous history of symptoms of endometriosis can be indicative. However, when the diagnosis remains uncertain further investigation is advised to rule out a malignant neoplasm.

Surgical management of an adnexal mass in pregnancy creates a dilemma to gynaecologists. Sometimes, it is difficult to discriminate ovarian malignancies from functional cysts or benign ovarian tumours. If an adnexal mass, larger than 10 cm or has complex features on imaging, or ascites or shows significant increase in size, surgical management is critical for obtaining a final histological diagnosis and ruling out malignancy. Elective surgery for suspicious ovarian masses should be delayed until the second trimester (16-18 weeks of gestation), as the risk for spontaneous abortion is comparatively



**[Table/Fig-6]:** Preoperative imaging and intraoperative picture of clear cell carcinoma in pregnancy.

low in this period of pregnancy. Also, in the first trimester, the rate of spontaneous abortion after surgery is around 10%, while 76.3% patients progress to full-term delivery. When a mass is first noticed in the third trimester, it is ideal to wait for foetal maturity as long as the clinical suspicion of malignancy is low [12]. In present study also, all elective laparotomies (n=12) were performed between 16-18 weeks. Patients had no complications postoperatively and all pregnancies continued till term. One case of emergency laparotomy, performed at 30 weeks of gestation in view of torsion, subsequently went in for preterm delivery and the baby could not be salvaged in view of extreme prematurity.

The advantages of laparoscopy over laparotomy for benign masses are discussed increasingly, claiming that laparoscopy is superior with significantly lesser operative time, perioperative morbidity, length of hospital stay, and decreased postoperative pain resulting in faster postoperative ambulation [13,14]. However, in present study only laparotomy has been done in all cases requiring surgical intervention as all cases included were suspicious for malignancy.

The incidence of suspicious ovarian masses detected during pregnancy is 1/300 to 1/556 pregnancies. Of these, the incidence of ovarian malignancy is 1/15,000 to 1/32,000 in most reports [11]. A higher incidence of ovarian malignancy in pregnancy of 1 in 1684 was reported by Ueda M and Ueki M but population selective bias could not be excluded in their study [15]. In present study, detection of suspicious ovarian masses during pregnancy occurred in 1/929 deliveries that is around 33 cases out of 30,657 deliveries in two years (2018-2020) at our hospital. Furthermore, the incidence of ovarian cancers in pregnancy was found to be 1 in 5109 deliveries. This high incidence could be explained by the fact that our institute is a tertiary care and referral centre for gynaecological oncology cases again contributing to population selection bias.

The most common primary ovarian malignancies reported in pregnancy are germ cell tumours followed by borderline tumours and then epithelial ovarian cancers presumably due the younger age group involved [16].

Out of 33 patients in present study, 81.82% (n=27) were benign and 18.18% (n=6). In present study, the most common ovarian malignancies were epithelial followed by germ cell tumours. No case of borderline ovarian tumour was observed. This disparity may be due to the small sample size of present study. Most of the ovarian tumours in pregnancies are reportedly asymptomatic at presentation and diagnosed by routine ultrasound [17,18]. In present study too, 72.7% were asymptomatic at presentation.

Majority of reported ovarian cancers in pregnancy were identified in early stages [19,20]. However, in present study only one case (mucinous carcinoma) presented in an early stage (IC3). Others were all advanced. This may be attributed to the fact that epithelial ovarian cancers were the most common tumours seen in present study which inherently are known to present at advanced stages. Even the yolk sac tumour in present study series presented at an advanced disease of stage III C. Similar incidences of aggressive growth and recurrence of ovarian germ cell tumours in pregnancy have been previously reported [21,22]

The management of advanced ovarian malignancy detected during pregnancy is controversial. Available evidence suggests that most women chose to terminate pregnancy in favour of treatment of the ovarian cancers. However, neoadjuvant chemotherapy for advanced epithelial ovarian cancer with paclitaxel and carboplatin in the second trimester of pregnancy has been described with completion surgery at the time of delivery [23,24]. In present study, there were four cases of advanced ovarian cancer where neoadjuvant chemotherapy was given during pregnancy. Three cases received carboplatin and paclitaxel doublet whereas one case received BEP chemotherapy since it was a germ cell tumour. All patients tolerated chemotherapy well and had no complications of chemotherapy and delivery was planned three weeks from the last dose.

Chemotherapy when administered in the first trimester can lead to congenital malformations at the rate of around 10-20%. Chemotherapy can be administered after 14 weeks of pregnancy with careful monitoring of the mother and foetus. However, there is an increased incidence of prematurity, low birth weight, intrauterine growth restriction and neonatal blood count reduction [25]. Delivery should be planned atleast three weeks after the last cycle of chemotherapy in order to prevent myelosuppression and chemotherapy should not be given after 35 weeks as patient may enter spontaneous labour. In present study, no such complications were observed in all patients who received antenatal chemotherapy. All the four patients had term deliveries with normal birth weight. None of the babies had myelosuppression and are currently doing well. Breast feeding during chemotherapy is not encouraged [26]. In present study too, breast feeding was withheld for all these patients since there were to be started on adjuvant chemotherapy. The long term health effects on children exposed to chemotherapeutic agents in utero remain unknown as there are no long term studies.

Termination of pregnancy is the treatment of choice for women presenting with advanced stage disease in early pregnancy warranting chemotherapeutic treatment. Hence, the case of carcinoma stomach with ovarian krukenberg tumour was offered termination of pregnancy followed by chemotherapy

The prognosis of ovarian cancers in pregnancies depends on the histological type and stage at presentation. Good outcomes have been reported for germ cell tumours and borderline ovarian tumours. However, epithelial ovarian malignancies have a poor outcome more so if identified at advanced stages. In a report of 23 ovarian cancers in pregnancy, all three cases of advanced epithelial ovarian cancers succumbed to the disease [27]. In present study, one patient with mucinous ovarian cancer had an aggressive disease course and succumbed to the disease. The other two cases of advanced epithelial cancer and one case of advanced germ cell tumour are currently disease free.

The strength of the study lies in the fact that a multidisciplinary approach comprising the Gynaec Oncologist, Gynaecologist and Medical Oncologist was involved in the management of each of the cases.

### Limitation(s)

However, small sample size and need for longer period of follow-up for the patients who were diagnosed with malignancy as well as the children born to mothers who were treated with antenatal chemotherapy could be considered the limitations of the study. It is further recommended that this study could be continued for a longer period of follow-up in order to draw better conclusions.

### CONCLUSION(S)

Each case of suspicious adnexal mass in pregnancy should be thoroughly evaluated, keeping in mind the risk of malignancy and treatment be tailored accordingly. Malignant appearing masses must be offered surgery. Chemotherapy can be offered in pregnancy after the first trimester and pregnancy can be continued with careful monitoring. However, malignant ovarian tumours in pregnancy must be taken care of by a multidisciplinary team consisting of Gynaecologists, Gynaecological Oncologists, Medical Oncologists and Paediatricians. Hence, these patients must be referred to centers with such facilities.

### REFERENCES

- [1] de Haan J, Verheeecke M, Amant F. Management of ovarian cysts and cancer in pregnancy. *Facts Views Vis Obgyn*. 2015;7(1):25-31.
- [2] Grigoriadis C, Eleftheriades M, Panoskaltis T, Bacanu AM, Vitoratos N, Kondi-Pafitti A, et al. Ovarian cancer diagnosed during pregnancy: Clinicopathological characteristics and management. *G Chir*. 2014;35(3-4):69-72.
- [3] Cavaco-Gomes J, Jorge Moreira C, Rocha A, Mota R, Paiva V, Costa A. Investigation and management of adnexal masses in pregnancy. *Scientifica (Cairo)*. 2016;2016:3012802. Doi: 10.1155/2016/3012802.

- [4] Makrydimas G, Sotiriadis A, Paraskevaidis E, Pavlidis N, Agnantis N, Lolis D. Clear cell ovarian carcinoma in a pregnant woman with a history of infertility, endometriosis and unsuccessful IVF treatment. *Eur J Gynaecol Oncol.* 2003;24(5):438-41.
- [5] Hummeida ME, Hamad K, Gadir AF, Ali AA. Ovarian cancer during pregnancy: A case report and literature review. *Clin Pract.* 2015;5(2):727.
- [6] Garg S, Kaur A, Mohi JK, Sibia PK, Kaur N. Evaluation of IOTA simple ultrasound rules to distinguish benign and malignant ovarian tumours. *J Clin Diagn Res.* 2017;11(8):TC06-09. Doi: 10.7860/JCDR/2017/26790.10353.
- [7] Giuntoli RL 2, Vang RS, Bristow RE. Evaluation and management of adnexal masses during pregnancy. *Clin Obstet Gynaecol.* 2006;49(3):492-505.
- [8] D'Ambrosio V, Brunelli R, Musacchio L, Del Negro V, Vena F, Boccuzzi G, et al. Adnexal masses in pregnancy: An updated review on diagnosis and treatment. *Tumori.* 2021;107(1):12-16. 2020.107.030089162090914. 10.1177/0300891620909144.
- [9] Drake J. Diagnosis and management of the adnexal mass. *Am Fam Physician.* 1998;57(10):2471-76, 2479-80.
- [10] Galczyński K, Józwiak M, Lewkowicz D, Semczuk-Sikora A, Semczuk A. Ovarian endometrioma- a possible finding in adolescent girls and young women: A mini-review. *J Ovarian Res.* 2019;12:104. 10.1186/s13048-019-0582-5.
- [11] Hakoun AM, Abou Al-Shaar I, Zaza KJ, Abou-Al-Shaar H, A Salloum MN. Adnexal masses in pregnancy: An updated review. *Avicenna Med.* 2017;7:153-57.
- [12] Webb KE, Sakhel K, Chauhan SP, Abuhamad AZ. Adnexal mass during pregnancy: A review. *Am J Perinatol.* 2015;32:1010.
- [13] Shigemi D, Aso S, Matsui H, Fushimi K, Yasunaga H. Safety of laparoscopic surgery for benign diseases during pregnancy: A nationwide retrospective cohort study. *Journal of Minimally Invasive Gynaecology.* 2019;26(3):501-06.
- [14] Kurihara K, Minagawa M, Masuda M, Fukuyama M, Tanigaki K, Yamamoto A, et al. The evaluation of laparoscopic surgery on pregnant patients with ovarian cysts and its effects on pregnancy over the past 5 years. *Gynaecol Minim Invasive Ther.* 2018;7(1):01-05.
- [15] Ueda M, Ueki M. Ovarian tumours associated with pregnancy. *Int J Gynaecol Obstet.* 1996;55:59-65.
- [16] Morice P, Uzan C, Gouy S, Verschraegen C, Haie-Meder C. Gynaecological cancers in pregnancy. *Lancet.* 2012;379:558-69.
- [17] Goff BA, Paley PJ, Koh WJ, et al. Cancer in the pregnant patient. In *Principles and Practice of Gynaecologic Oncology 3<sup>rd</sup> edition.* Edited by: Hoskins WJ, Perez CA, Young RC. Philadelphia: Lippincott Williams & Wilkins; 2000:501-28.
- [18] Behtash N, Zarchi MK, Gilani MM, Ghaemmaghami F, Mousavi A, Ghotbizadeh F. Ovarian carcinoma associated with pregnancy: A clinicopathologic analysis of 23 cases and review of the literature. *BMC Pregnancy Childbirth.* 2008;8:3.
- [19] Zanotti KS, Belinson JL, Kennedy AW. Treatment of gynaecologic cancers in pregnancy. *Semin Oncol.* 2000;27:686-98.
- [20] Partridge EE, Phillips JL, Menck HR. The National Cancer Data Base report on ovarian cancer treatment in United States hospitals. *Cancer.* 1996;78:2236-46.
- [21] Karlen JR, Akbari A, Cook WA. Dysgerminoma associated with pregnancy. *Obstet Gynaecol.* 1979;53:330-35.
- [22] Gershenson DM. Management of early ovarian cancer: Germ cell and sex cord-stromal tumours. *Gynaecol Oncol.* 1994;55:S62-72.
- [23] Méndez LE, Mueller A, Salom E, González-Quintero VH. Paclitaxel and carboplatin chemotherapy administered during pregnancy for advanced epithelial ovarian cancer. *Obstet Gynaecol.* 2003;102(5 Pt 2):1200-02.
- [24] Doi D, Boh Y, Konishi H, Asakura H, Takeshita T. Combined chemotherapy with paclitaxel and carboplatin for mucinous cystadenocarcinoma of the ovary during pregnancy. *Arch Gynaecol Obstet.* 2009;280(4):633-36. Doi: 10.1007/s00404-009-0950-2. Epub 2009 Feb 11.
- [25] Dekrem J, Van Calsteren K, Amant F. Effects of fetal effects to maternal chemotherapy. *Paediatr Drugs.* 2013;15:329-34.
- [26] Weed JC, Roh RA, Mendenhall HW. Recurrent endodermal sinus tumour during pregnancy. *Obstet Gynaecol.* 1997;54:653-56.
- [27] Motegi M, Takakura S, Takano H, Tanaka T, Ochiai K. Adjuvant chemotherapy in a pregnant woman with endodermal sinus tumour of the ovary. *Obstet Gynaecol.* 2007;109(2):537-40.

**PARTICULARS OF CONTRIBUTORS:**

1. Associate Professor, Department of Gynaec Oncology, Institute of Obstetrics and Gynaecology, Madras Medical College, Chennai, Tamil Nadu, India.
2. Fellow Postgraduate, Department of Gynaec Oncology, Institute of Obstetrics and Gynaecology, Madras Medical College, Chennai, Tamil Nadu, India.
3. Fellow Postgraduate, Department of Gynaec Oncology, Institute of Obstetrics and Gynaecology, Madras Medical College, Chennai, Tamil Nadu, India.

**NAME, ADDRESS, E-MAIL ID OF THE CORRESPONDING AUTHOR:**

Dr. Delphin Supriya,  
BS-2, Navin's Aradhana Apartments, No. 1, Church Road, Perungudi,  
Chennai, Tamil Nadu, India.  
E-mail: delphinsupriya.j@gmail.com

**PLAGIARISM CHECKING METHODS:** [Jain H et al.]

- Plagiarism X-checker: Oct 17, 2020
- Manual Googling: Oct 30, 2021
- iThenticate Software: Dec 15, 2021 (9%)

**ETYMOLOGY:** Author Origin**AUTHOR DECLARATION:**

- Financial or Other Competing Interests: None
- Was Ethics Committee Approval obtained for this study? No
- Was informed consent obtained from the subjects involved in the study? Yes
- For any images presented appropriate consent has been obtained from the subjects. Yes

Date of Submission: **Oct 16, 2020**  
Date of Peer Review: **Dec 18, 2021**  
Date of Acceptance: **Nov 08, 2021**  
Date of Publishing: **Jan 01, 2022**