

Acute Presentation of Upper Limb Ischaemia Requiring Amputation: A Case Report

SHRIYA HIMMAT THACKER¹, MUKESH CHANDE², MANISH RAVAL³, NAVIN GAGAL⁴

ABSTRACT

Peripheral Artery Disease (PAD) of the upper extremities is common. It is most often asymptomatic but may cause exertional pains, ischaemic pains, gangrene or ulceration. The risk factors for PAD are smoking, obesity, hypertension, diabetes, hypercholesterolaemia and end stage renal disease. Here the authors reported a case of 45-year-old male patient, presenting with severe aching type of pain associated with paraesthesia and numbness and blue, cold and gangrenous right forearm which was amputated below the elbow. After amputation, the condition advanced and led to weakness of the right upper arm with bone necrosis and surrounding skin was hyperaemic and oedematous with differential warmth, therefore the patient undergone amputation of the right upper arm and was managed postoperatively with antibiotics and the wound was closed with non absorbable sutures and was on oral anticoagulant therapy and after complete recovery, patient was discharged. On follow-up, removal of sutures was done and patient was referred for physiotherapy for muscle strengthening and prosthesis fitment.

Keywords: Dermatome, Hypochoic thrombus, Peripheral artery disease

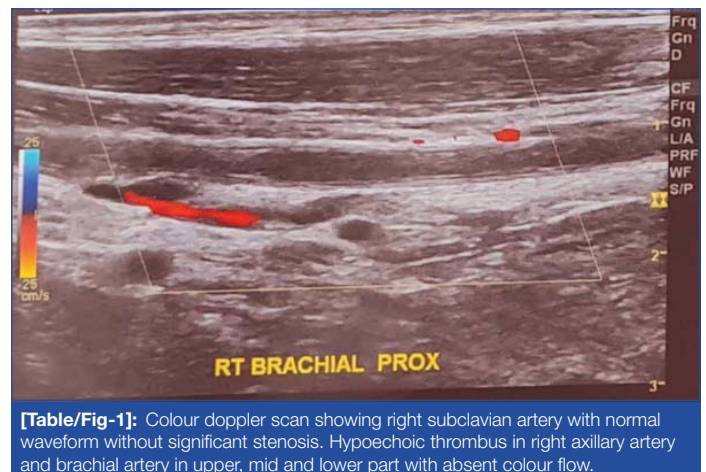
CASE REPORT

A 45-year-old male patient presented to a primary health centre in June 2021 with blue cold and blackish discoloration of forearm since one week. No past history of Coronavirus Disease-19 (COVID-2019) infection. The patient had severe pain which was sudden on onset, numbness and prickling sensation in his right forearm since four days. There was progression in pain which worsened and localised in his right forearm below the elbow. The condition worsened and weakness of the right forearm was perceived. Right forearm progressed to gangrenous condition which was amputated below the elbow. The patient was shifted to another hospital due to intolerable pain in the right upper arm. The patient did not have a history of hypertension and diabetes mellitus, negative family history of atherosclerosis and no aetiology to explain thrombogenesis except the account of smoking 30 bidis per day since 30 years and drinking 90 mL of alcohol per day since 30 years.

On local examination, the amputated wound was open and necrosed bones were seen. Surrounding skin was hyperaemic, oedematous with differential warmth in the proximal arm. There was a sensory deficit at C4-C5 dermatome level with absent motor activity in all the muscles (anterior compartment muscles: biceps brachii, brachialis, coracobrachialis and posterior compartment muscles: triceps brachii, anconeus) above the elbow. Brachial pulses were not palpable at elbow in the right upper limb except for right axillary artery pulsation which was feeble. Over the deltoid region at C4-C5 dermatome level hyperaesthesia was perceived. The left upper limb was normal. All other peripheral pulsations on the left side were palpable.

At the time of admission Total Leucocyte Count (TLC) was 3.44 million/cmm (Normal value: 4.5-5.5 million/cumm) reduced with elevated C-reactive Protein (CRP) of 167.81 mg/L (Normal value: 0.0-1.0 mg/L). TLC of 4.84 million/cmm and CRP reduced to 39.59 mg/L the time of discharge. Calcium oxalate crystals and a few pus cells were seen on urine examination. Random blood sugar levels were normal and enzyme-linked immunosorbent assay test for human immunodeficiency virus was negative.

Colour doppler studies showed the right subclavian artery with normal waveform without significant stenosis. Hypochoic thrombus in right axillary artery and brachial artery in upper, mid and lower part with absent colour flow [Table/Fig-1].

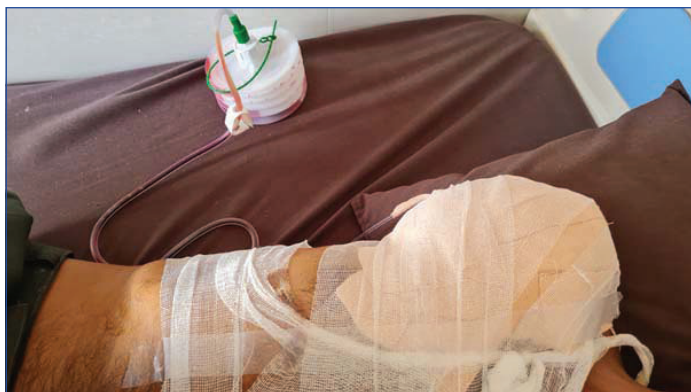

[Table/Fig-1]: Colour doppler scan showing right subclavian artery with normal waveform without significant stenosis. Hypochoic thrombus in right axillary artery and brachial artery in upper, mid and lower part with absent colour flow.

Because of unsalvageable right upper limb, an amputation was done above elbow on the right side under general anaesthesia. Intraoperatively, there was thrombus found in brachial artery, at the C4-C5 dermatome level. All anterior compartment muscles were necrosed, thus were removed and the stump was closed with sutures. Injectable cefoperazone+sulbactam (1 g+0.5 g) was given in the postoperative period to the patient. The patient was advised on injectable tazar 4.5 (piperacillin 4000 mg+tazobactam 500 mg), amikacin, pantodec (pantoprazole 40 mg), emset (Ondansetron 4 mg). Negative pressure wound therapy with colistin instillation (NPWTi) was commenced in view of infected muscle compartments, encouragement of granulation tissue and for assisting closure.

On re-evaluating the wound after five days, healthy granulation tissue was seen and the wound was partially closed reinitiating NPWTi with colistin instillation. The wound appeared clean and healthy after reassessing on 10th day. After a thorough wash with betadine and hydrogen peroxide, the wound was secured with non absorbable sutures [Table/Fig-2]. The patient was started on anticoagulant ecospirin and was discharged.

On discharging, the patient was asked to follow-up after 10 days. His sutures were taken off and wound was clean and healthy and he was referred for physiotherapy for muscle strengthening and prosthesis fitment.



[Table/Fig-2]: Image showing right-sided upper limb amputation in the patient.

DISCUSSION

Acute upper limb ischaemia is rare and it may be caused by obstruction of the upper limb arteries at different levels, above and below the elbow [1]. The common causes are smoking, hypertension, diabetes, obesity, high triglyceride levels and kidney failure. Below the elbow disease is seen more frequently in patients with diabetes. Early diagnosis and appropriate surgical therapy is generally indicated in patients with upper limb ischaemia [2]. In most of the cases of subclavian and axillary artery occlusive disease, females who are diabetic predominates [3]. But in the present case, there is male who is non diabetic with brachial artery involvement. As far as reconstruction and bypass surgery are concerned, lower extremity ischaemia constitutes higher percentage as compared to upper extremity ischaemia and henceforth data availability is concised [4]. In a case report by Ramachandran R et al., a male patient of 44-year-old with uncontrolled diabetes mellitus and COVID-19 positive has to lost the limb due to arterial thrombosis as a COVID-19 sequelae [5], but in our case 45-year-old male who is a non diabetic and negative for COVID-19 has to lost his limb due to occlusion of the brachial artery.

Vascular insufficiency can be due to aneurysm, thrombosis, vasculitis, stroke and Raynaud's disease [6]. In the present case, it is due to occlusive disease as the patient had history of smoking and alcohol. In upper limb ischaemia major amputations are very rare and most of the cases are treated non operatively [7]. In upper limb ischaemia which is acute on onset generally requires amputation because of end stage gangrene [8]. Therefore, as acute upper limb ischaemia is rare, the only resort is amputation of the limb. Also, conservative management as primary therapy is reserved for the patients who are unfit for interventional therapy [9]. Since, acute non traumatic upper limb ischaemia is often missed among common diagnosis it remains the major cause of hospital mortality and morbidity [10]. An effectual

and beforehand management of acute upper limb ischaemia is prudent and efficacious which lessens the risk of incapacitation [11]. In most of the cases of upper limb ischaemia it is the right upper arm which is most commonly affected [12]. Vascular surgeons are concerned on increasing death rates of patients suffering from acute limb ischaemia and there is need for the development of alternative therapies [13]. There are different interventions for treating the acute limb ischaemia, but surgical revascularisation in the present case was opted over other modalities [14].

CONCLUSION(S)

Acute limb ischaemia is common and generally overlooked which leads to morbidity and mortality. Over decades, surgeons prefer surgical management due to best outcomes over non surgical management.

REFERENCES

- [1] McNamara MF, Takaki HS, Yao JS, Bergan JJ. A systematic approach to severe hand ischemia. *Surgery*. 1978;83(1):01-11.
- [2] Welling RE, Cranley JJ, Krause RJ, Hafner CD. Obliterative arterial disease of the upper extremity. *Arch Surg*. 1981;116(12):1593-96. Doi: 10.1001/archsurg.1981.01380240073012.
- [3] Harris RW, Andros G, Dulawa LB, Oblath RW, Salles-Cunha SX, Apyan R. Large-vessel arterial occlusive disease in symptomatic upper extremity. *Arch Surg*. 1984;119(11):1277-82. Doi: 10.1001/archsurg.1984.01390230047011.
- [4] Bergqvist D, Ericsson BF, Konrad P, Bergentz SE. Arterial surgery of the upper extremity. *World J Surg*. 1983;7(6):786-91. Doi: 10.1007/BF01655222.
- [5] Ramachandran R, Vasudevan Pillai A, Raja S, Sailesh S. Axillary artery thrombosis resulting in upper limb amputation as a COVID-19 sequela. *BMJ Case Rep*. 2021;14(1):e240981. Doi: 10.1136/bcr-2020-240981. PMID: 33500313; PMCID: PMC7839882.
- [6] Higgins JP, McClinton MA. Vascular insufficiency of the upper extremity. *J Hand Surg Am*. 2010;35(9):1545-53. Doi: 10.1016/j.jhnsa.2010.06.011.
- [7] Cheun TJ, Jayakumar L, Sheehan MK, Sideman MJ, Pounds LL, Davies MG. Outcomes of upper extremity interventions for chronic critical ischemia. *J Vasc Surg*. 2019;69(1):120-28.e2. Doi: 10.1016/j.jvs.2018.04.056.
- [8] Jones NF. Acute and chronic ischemia of the hand: Pathophysiology, treatment, and prognosis. *J Hand Surg Am*. 1991;16(6):1074-83. Doi: 10.1016/s0363-5023(10)80072-3.
- [9] Turner EJ, Loh A, Howard A. Systematic review of the operative and non operative management of acute upper limb ischemia. *J Vasc Nurs*. 2012;30(3):71-76. Doi: 10.1016/j.jvn.2012.03.002.
- [10] Yangni-Angate H, Adoubi A, Adoh Adoh M, Yapobi Y, Coulibaly AO. Ischemies aiguës on traumatiques des membres [Acute nontraumatic limb ischemia]. *West Afr J Med*. 2006;25(2):101-04.
- [11] Evers P, Earnshaw JJ. Acute non traumatic arm ischaemia. *Br J Surg*. 1998;85(10):1340-46. Doi: 10.1046/j.1365-2168.1998.00884.
- [12] Pentti J, Salenius JP, Kuukasjärvi P, Tarkka M. Outcome of surgical treatment in acute upper limb ischaemia. *Ann Chir Gynaecol*. 1995;84(1):25-28.
- [13] Morris-Stiff G, D'Souza J, Raman S, Paulvannan S, Lewis MH. Update experience of surgery for acute limb ischaemia in a district general hospital- are we getting any better? *Ann R Coll Surg Engl*. 2009;91(8):637-40. Doi: 10.1308/003588409X12486167521271.
- [14] Khan S, Hawkins BM. Acute limb ischemia interventions. *Interv Cardiol Clin*. 2020;9(2):221-28. Doi: 10.1016/j.iccl.2019.12.002.

PARTICULARS OF CONTRIBUTORS:

1. Student, Department of Surgery, Krishna Institute of Medical Sciences, Karad, Maharashtra, India.
2. Private Practitioner, Department of Surgery, Fusion Hospital, Bhuj, Gujarat, India; Associate Professor, Department of Surgery, Gujarat Adani Medical College, Bhuj, India.
3. Private Practitioner, Department of Surgery, Institute of Kidney Disease and Research Centre, Ahmedabad, Gujarat, India.
4. Private Practitioner, Department of Orthopaedics, Fusion Hospital, Bhuj, Gujarat, India.

NAME, ADDRESS, E-MAIL ID OF THE CORRESPONDING AUTHOR:

Dr. Shriya Himmat Thacker,
Hostel No. 1, KIMSUDU, Karad, Maharashtra, India.
E-mail: shriuthacker@gmail.com

AUTHOR DECLARATION:

- Financial or Other Competing Interests: None
- Was informed consent obtained from the subjects involved in the study? Yes
- For any images presented appropriate consent has been obtained from the subjects. Yes

PLAGIARISM CHECKING METHODS: [Jain H et al.]

- Plagiarism X-checker: Aug 24, 2021
- Manual Googling: Nov 05, 2021
- iThenticate Software: Dec 30, 2021 (20%)

ETYMOLOGY: Author Origin

Date of Submission: **Aug 23, 2021**
Date of Peer Review: **Oct 06, 2021**
Date of Acceptance: **Dec 09, 2021**
Date of Publishing: **Jan 01, 2022**