

# Burkholderia cepacia - An unusual organism for sepsis in ICUs.

BENDIGERI MUKHTARAHMED, GEORGE PETER

## ABSTRACT

ICU sepsis is a common situation encountered in practice; and tertiary care centres have a clear antibiotic policy to manage such instances. At times, rare organisms like commensals and non human bacteria which are difficult to treat, are isolated

by culturing tissue fluids. We report here, the successful management of ICU sepsis with *Burkholderia cepacia*, in a 29 year old immuno- competent woman. Native infections due to *B cepacia* are rare; the usual sources of these organisms in ICUs are the vascular and indwelling catheters.

**Key Words:** Immuno -competent, ICU sepsis, *Burkholderia cepacia*, BACTEC culture.

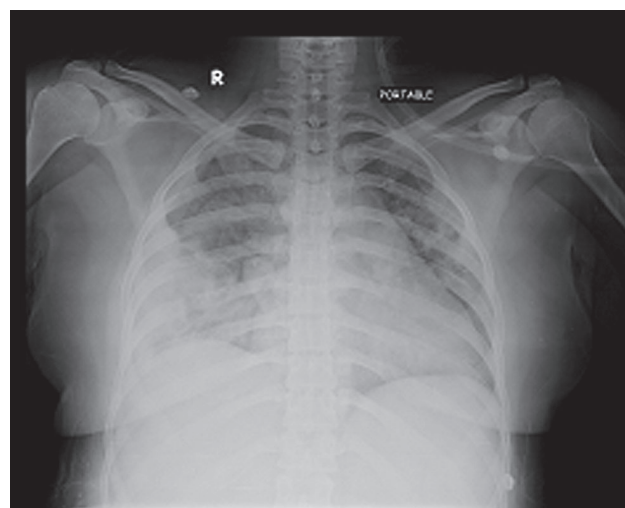
## INTRODUCTION

*Burkholderia cepacia* or the *Burkholderia cepacia* complex (BCC) is a catalase-producing, non-lactose-fermenting, gram-negative bacterium. The *B cepacia* bacteria are subdivided into nine different genomic species that show morphological similarity, which are called genomovars [1]. *B cepacia* is an important human pathogen which often causes pneumonia in immune-compromised individuals with underlying lung disease or malignancies [2,3]. We report here, a case of *B cepacia* induced ICU sepsis in an immune-competent, 29 year old woman. As in earlier reports [4,5], the source of infection was not found in the present case and we postulated it to be from the catheters in situ.

## CASE REPORT

A 29 year old healthy woman, who presented with complaints of left lower limb ache of 10 days and fever of 2 days, was admitted to the orthopaedic ward for evaluation. She was started on oral paracetamol by a local practitioner. A medical consultation was sought, as she had no localising symptoms or signs, and basic investigations normal, the treatment was continued. The next day, she developed shortness of breath and cough with scanty expectoration, along with fever. Her clinical examination was unyielding, except for her tachypnoea. Viral pneumonia was considered, due to its high prevalence in the locality. She was transferred to the multidisciplinary intensive care unit (ICU). Her respiratory distress worsened over the next few hours and she was put through assisted ventilation, broad spectrum antibiotics, anticoagulants and supportive care. Her repeat investigations showed leukocytosis with neutrophilia and non-homogenous bilateral perihilar opacities in the chest X - ray [Table/Fig 1] and her venous Doppler studies showed right femoral vein thrombosis. The initial blood, sputum and urine cultures were sterile and her blood biochemistry was normal. Even after 4 days of treatment, she continued to have fever, leukocytosis and ventilator dependence.

Meanwhile, the evaluations which were done for thrombotic disorders, connective tissue disorders and infective endocarditis were found to be negative. Repeat blood cultures which were done by the BACTEC method grew *Burkholderia cepacia* which was sensitive to ceftazidime and sulfamethoxazole - trimethoprim.



**[Table/Fig-1]:** Portable chest X - ray showing bilateral perihilar non homogenous opacities

She was switched over to sensitive antibiotics, and over the next 5 days, she was weaned of assisted ventilation. The repeat Doppler studies of the lower limb veins were normal and her blood cultures were negative. She was discharged from the hospital on the 15<sup>th</sup> day of admission on anticoagulants and oral sulfamethoxazole - trimethoprim.

## DISCUSSION

In the review of literature, ICU sepsis which is caused by *B cepacia* has been reported, and it has been found to be associated with high mortality [4,5,6]. As in the present case, in most of the reports of culture positive *B cepacia* sepsis, vascular and indwelling catheters were present [4,5]. There are few reports on contaminated fluids and materials which are used for the treatment, as the source for infection [6,7,8,9]. Lu DC et al [10], identified the respiratory tract as the most common portal of entry (17/41), followed by intravascular catheters (11/41).

In the present case, the initial symptoms of fever and lower limb pain may have originated from deep venous thrombosis. Later, multiple pulmonary micro thrombo-embolism from the venous thrombosis would have resulted in hypoxia, with respiratory

symptoms. Viral pneumonia was the differential diagnosis and she was put on broad spectrum antibiotics, assisted ventilation and anti coagulants. After being on assisted ventilation and indwelling catheters, she developed bacteraemia, pneumonia and later, sepsis. We were able to identify the organism by BACTEC cultures, but failed to identify the source of the bacteraemia. We presumed that the bacteraemia could be from the catheters in situ. With treatment with appropriate antibiotics, the patient recovered and was discharged. As she had a major thrombotic episode, she was advised to continue on the oral anti coagulants.

The literature of over 20 years was reviewed by Coutinho HD [11]. Most of the B cepacia infections were found to be opportunistic infections, in immune-compromised individuals, especially those with cystic fibrosis and HIV infection. B cepacia, over the years, has emerged as a major killer among the immune-compromised patients who are admitted to ICUs the world over. Douce RW et al [8] have reported an epidemic of catheter-induced sepsis due to B cepacia from Ecuador, in 2008, and contaminated water ampoules were found to be the source of this outbreak. Speert HT concluded that close personal contact facilitated the transmission of the B cepacia infection [12].

B cepacia is resistant to most of the antibiotics and it should be treated with a combination of antimicrobials [10,11]. Most of the strains are susceptible to ceftazidime (95%), piperacillin, minocycline, and cefotaxime; and are resistant to aminoglycosides, tetracycline, carbenicillin and ticarcillin. The drug of choice for the empirical treatment of B cepacia bacteraemia is ceftazidime and sulfmethoxazole - trimethoprim, unless B cepacia is proved to be resistant to these [8,10]. In the present case, the isolated B cepacia was sensitive to ceftazidime and sulfmethoxazole-trimethoprim and the patient responded well to the treatment.

Considerable progress has been made in the past decade, to understand the natural biology and the clinical features of the infections which are caused by B cepacia [12,13,14]. Newer and precise diagnostic methods have to be standardised for the easier identification of this group of organisms, which will reduce the mortality and improve the treatment outcome.

## CONCLUSION

As more infections by B cepacia are being reported, this opportunistic pathogen is emerging as a major risk factor to patients and health care facilities across the world. Through this

report, we are highlighting that B cepacia is a not-so-uncommon organism in causing ICU sepsis. Clinicians, especially from the tropics and the developing nations, must be made aware as to how to detect and combat this emerging infection with a potentially fatal outcome.

## REFERENCES

- [1] Lipuma J. Update on the Burkholderia cepacia complex. *Curr Opin Pulm Med*. 2005; 11: 528-33.
- [2] Mahenthalingam E, Urban T, Goldberg J. The multifarious, multireplicon Burkholderia cepacia complex. *Nat Rev Microbiol*. 2005; 3: 144-56.
- [3] Mann T, Ben-David D, Zlotkin A, Shachar D, Keller N, Toren A, et al. An outbreak of Burkholderia cenocepacia bacteremia in immunocompromised oncology patients. *Infection* 2010; 38: 187-94.
- [4] Conly JM, Klass L, Larson L. Pseudomonas cepacia colonization and infection in intensive care units. *Can Med Assoc J*. 1986; 134: 363-6.
- [5] Abe K, D'Angelo MT, Sunenshine R, Noble-Wang J, Cope J, Jensen B, et al. Outbreak of the Burkholderia cepacia bloodstream infection at an outpatient haematology and oncology practice. *Infect Control Hosp Epidemiol*. 2007; 28: 1311-3.
- [6] Held MR, Begier EM, Beardsley DS, Browne FA, Martinello RA, Baltimore RS, et al. Life-threatening sepsis which is caused by Burkholderia cepacia from contaminated intravenous flush solutions which are prepared by a compounding pharmacy in another state. *Pediatrics*. 2006; 118: e212-5.
- [7] Mukhopadhyay C, Bhargava A, Ayyagari A. Two Novel Clinical Presentations of the Burkholderia cepacia Infection. *J Clin Microbiol*. 2004; 42: 3904-5.
- [8] Douce RW, Zurita J, Sanchez O, Cardenas Aldaz P. Investigation of an outbreak of central venous catheter-associated bloodstream infection due to contaminated water. *Infect Control Hosp Epidemiol*. 2008; 29: 364-6.
- [9] Martin M, Christiansen B, Casparib G, Hogardt M, Von Thomsen AJ, Ott E, Mattner F. Hospital-wide outbreaks of Burkholderia contaminans which are caused by pre-fabricated moist washcloths. *Journal of Hospital Infection* 2011; 77: 267-70.
- [10] Lu DC, Chang SC, Chen YC, Luh KT, Lee CY, Hsieh WC. Burkholderia cepacia bacteremia: a retrospective analysis of 70 episodes. *J Formos Med Assoc*. 1997; 96: 972-8.
- [11] Coutinho HD. The Burkholderia cepacia complex: virulence characteristics, importance and relationship with cystic fibrosis. *Indian J Med Sci*. 2007; 61: 422-9.
- [12] Speert DP. Advances in the Burkholderia cepacia complex. *Paediatr Respir Rev*. 2002; 3: 230-5.
- [13] Mahenthalingam E, Baldwin A, Dowson CG. Burkholderia cepacia complex bacteria: opportunistic pathogens with an important natural biology. *J Appl Microbiol*. 2008; 104: 1539-51.
- [14] Leitão JH, Sousa SA, Ferreira AS, Ramos CG, Silva IN, Moreira LM. Pathogenicity, virulence factors, and strategies to fight against the Burkholderia cepacia complex pathogens and related species. *Appl Microbiol Biotechnol* 2010; 87: 31-40.

### AUTHOR(S):

1. Dr Peter George
2. Dr Mukhtharahmed Bendigeri

### PARTICULARS OF CONTRIBUTORS:

1. Corresponding Author
2. Assistant Professor, Department of Medicine, Yenepoya Medical College, University Road, Mangalore, Karnataka State, S India. 575018.

### NAME, ADDRESS, TELEPHONE, E-MAIL ID OF THE CORRESPONDING AUTHOR:

Dr Peter George  
MD, Associate Professor, Department of Medicine,  
Fr Muller Medical College,  
Fr Muller Road, Mangalore -575002, Karnataka State, S India.  
E-mail: drpetergeorge2002@yahoo.com  
Phone: +91 9845177660, +91 824 2238000,  
Fax: +91 824 2436352

### DECLARATION ON COMPETING INTERESTS:

No conflicting Interests.

Date of Submission: **Apr 19, 2011**  
Date of per review: **Aug 01, 2011**  
Date of acceptance: **Aug 04, 2011**  
Date of Publishing: **Nov 11, 2011**