

# Retrieval of Separated Endodontic Ni-Ti Rotary File with the Aid of Hypodermic Needle and K-File: A Case Report

S PALLAVI<sup>1</sup>, NJ NAGARAJ<sup>2</sup>

## ABSTRACT

One of the most prevalent operational errors that can occur during endodontic therapy is instrument separation. A fractured instrument may cause a blockage in the root canal, impeding the cleaning and shaping process. There are numerous recommended ways for retrieving a separated instrument, some of which are challenging to implement in clinical practice. Some of these procedures may need removal of substantial root dentin, which may weaken the tooth structure. This case report describes an alternate method for removing a fractured endodontic instrument from the root canal using a hypodermic needle and a K-file. A 31-year-old female patient came to the Department of Conservative Dentistry and Endodontics with the chief complaint of pain in the upper left front tooth region since two weeks. The clinical and radiographic examination indicated the existence of a broken Nickel-Titanium (Ni-Ti) rotary file along the coronal third of the root canal till apex. Under magnification, the fragment was initially exposed by creating a 2 mm trough around the fractured instrument using ultrasonics. In order to fix the fragment, a hypodermic needle was introduced into the root canal and the K-file was fitted in the needle lumen. Together, the fragment was removed without any complications. This technique can be used as a safe, easy, and low-cost approach of fractured instrument retrieval from the root canal.

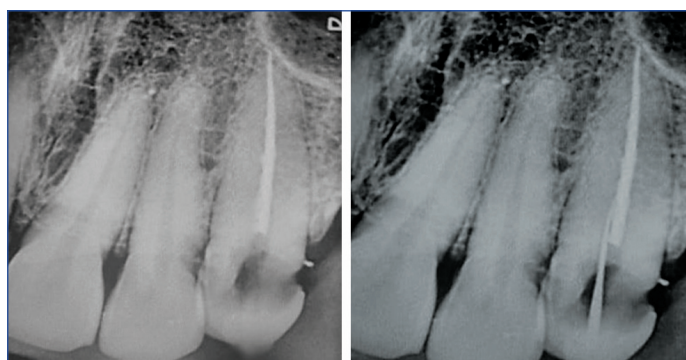
**Keywords:** Fractured instrument, Rotary file, Root canal, Ultrasonics

## CASE REPORT

A 31-year-old female patient presented to the Department of Conservative Dentistry and Endodontics with the primary complaint of pain in the upper left front tooth region since two weeks. Patient history indicated a previously initiated endodontic treatment performed 8 months back on maxillary left canine (23). Her medical history was non contributory. On clinical examination, the concerned tooth was properly aligned in the arch. There was no pain when percussion or palpation was applied, no swelling, and no evidence of a sinus tract. Periodontal examination indicated normal probing depth, gingival tone, and no mobility. A Nickel-Titanium (Ni-Ti) instrument was evident on radiographic inspection, from the coronal one third of the tooth to the apex and confirmed the diagnosis as previously initiated root canal therapy with fractured instrument in relation to tooth number 23 [Table/Fig-1]. The patient was made aware about the instrument fracture, and the treatment plan was decided as removal of the separated fragment. Informed consent was acquired from the patient before beginning the treatment.

A 2% lignocaine hydrochloride and 1:80000 adrenaline (Lignox 2%, Indoco Remedies Ltd., Mumbai) was used to deliver local anaesthesia. Access cavity was modified with a sterile Endo access bur No. 2 (Dentsply Maillefer, Switzerland) under rubber dam isolation (GDC Fine Crafted Dental Pvt., Ltd., India). A 10 mL 3% Sodium Hypochlorite (NaOCl) (Prime Dental Products Pvt. Ltd., Thane, India) was used to irrigate the pulp chamber. Initially, retrieval of the separated instrument was attempted using ultrasonics. Though the fragment became loosened, complete removal of fragment was unsuccessful using this technique. Then, the instrument was exposed by forming a 2 mm trough around the broken instrument using ultrasonics (Acteon, Satelec, France), done under the dental operating microscope (Sanma Medineers Vision Private Limited, Chennai, India). A 15 size K-file (Dentsply Maillefer, Switzerland) was used to partially bypass the instrument within the canal [Table/Fig-2].

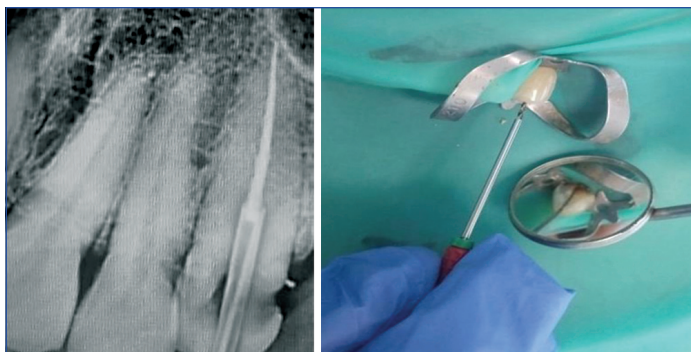
An 18-gauge needle (1.27 mm in outer diameter, 0.84 mm in inner diameter) was converted into a microtube by straightening the bevel of the needle using carborundum disc. The prepared needle was fitted to the coronal end of the separated instrument. Following



**[Table/Fig-1]:** Preoperative radiograph of 23 showing separated instrument.  
**[Table/Fig-2]:** Radiograph showing the insertion of 15 size K-file to bypass the separated fragment. (Images from left to right)

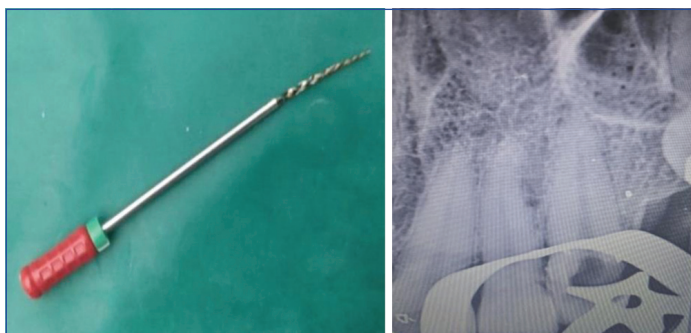
proper adaptation within the root canal and the free portion of the broken instrument, a 25 size K-file (Dentsply Maillefer, Switzerland) was introduced in a clockwise manner through the needle, to create a wedging effect between the needle and the coronal aspect of the separated fragment [Table/Fig-3]. K-file, needle, and the separated instrument were ensured to be in tight contact. Together, the set was pulled out coronally, by grabbing on the handle of the K-file [Table/Fig-4].

With this movement, the fractured instrument was successfully retrieved from the canal [Table/Fig-5] and a radiograph was taken to confirm the same [Table/Fig-6]. Following that, working length was determined with 25 size K-file. Chemomechanical root canal preparation was performed using crown-down technique till size F3 (6% taper) using protaper gold rotary system (Dentsply Tulsa Dental, OK, USA). Calcium hydroxide (ApexCal, Ivoclar Vivadent, Schaan, Liechtenstein) intracanal medicament was placed for a fortnight. Obturation was done using single cone technique with F3 gutta percha point (Dentsply Maillefer, Switzerland) and AH Plus resin-based sealer (Dentsply DE Trey, Konstanz, Germany) in the following appointment. Permanent coronal seal was placed using bulkfill composite restorative material (Tetric N Ceram, Ivoclar Vivadent, AG) [Table/Fig-7].



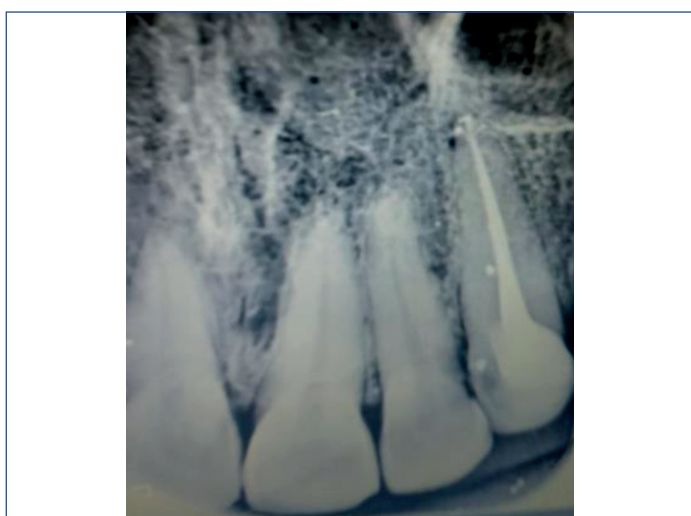**[Table/Fig-3]:** Radiograph showing hypodermic needle inserted into the coronal aspect of separated instrument along with 25 K-file.

**[Table/Fig-4]:** Retrieval of fractured instrument with the help of Hypodermic needle and 25 size K-file. (Images from left to right)



**[Table/Fig-5]:** Hypodermic needle, 25 K-file and separated instrument retrieved as a single unit.

**[Table/Fig-6]:** Radiograph taken post instrument retrieval. (Images from left to right)



**[Table/Fig-7]:** Postoperative radiograph after obturation and permanent restoration in 23.

## DISCUSSION

Instrument fracture within the root canal causes metallic pieces to block the intracanal space, compromising complete chemomechanical debridement and jeopardising a successful root canal therapy. When such an event is clinically confirmed, the fragment may be removed, bypassed, and sealed inside the root canal, or true blockage may be caused. Instrument fractures may also be attributed to a lack of knowledge regarding the procedure, over usage of the instrument, and the number of sterilisation cycles undergone by the instrument [1]. The presence of broken fragment in the root canal indicates a negative prognosis for the case, since cleaning and shaping of the obstructed root canal may be difficult [2].

The usage of Ni-Ti file system has altered the way we shape the root canal system. Ni-Ti alloys have several advantages including super elasticity, shape memory effect, and resistance to corrosion, all of which contributed to their extensive usage in a variety of dental applications. However, as compared to stainless steel, Ni-Ti alloy has a lower ultimate tensile strength and yield strength, making it at

increased risk to fracture at reduced loads [3]. Despite the numerous benefits and increasing popularity of Ni-Ti instruments, the chances of procedural errors are significantly higher (1.3% and 10%, respectively) than for stainless steel instruments (0.25% and 6%, respectively) [4]. The success rate for retrieving separated instruments is shown to be between 55% and 79% [5]. There are several methods for removing broken instruments, including the conventional approach using manual instruments, ultrasonics, the Masseran kit, the Terauchi kit, the Canal Finder and the Instrument Removal System (IRS), etc., [6]. However, no systematic approach for the removal of intracanal metallic obstacles has been developed. Many of these techniques, however, result in excessive radicular dentin removal and cause decreased resistance to tooth fracture [7].

In the present case, a Ni-Ti rotary instrument was fractured to the full length of the canal, and fully bypassing the canal was difficult. Initial retrieval attempt was made using ultrasonics, but the fragment was not able to be dislodged, since it was entrapped within the root canal wall. Stainless steel files are relatively easier to retrieve using ultrasonics because they tend to not break further during the process of removal. When ultrasonics is used to remove Ni-Ti instruments, heat build-up may cause additional breakage [8]. As a result, for the removal of fractured fragment, authors employed a low-cost, conservative method using a prepared stainless steel hypodermic needle in conjunction with a 25 size K-file. Literature research had shown that similar approaches were attempted for separated instrument retrieval previously [Table/Fig-8] [2,5,6,9-13].

Author	Year	Technique used for separated instrument retrieval
Roig-Greene JL [9]	1983	Hypodermic needle+Steel wire
Suter B [10]	1998	Hypodermic needle+H-file
Eleazer PD and O'Connor RP [11]	1999	Hypodermic needle+Cyanoacrylate
Andrabi SM et al., [5]	2013	Hypodermic needle+Cyanoacrylate
Monteiro JC et al., [12]	2014	Hypodermic needle+K-file
Brito-Júnior M et al., [6]	2015	Hypodermic needle+Steel wire
Frota LM et al., [13]	2016	Hypodermic needle+Cyanoacrylate
Loureiro C et al., [2]	2021	Hypodermic needle+K-file

**[Table/Fig-8]:** Literature review showing the separated instrument retrieval using hypodermic needle [2,5,6,9-13].

Ingle JI and Bakland LK recommended a second tool inserted into the needle lumen in order to wedge the fractured fragment to aid in removal [14]. The use of hypodermic needle for instrument removal was originally reported by Eleazer PD and O'Connor R [11]. There are several advantages of using a hypodermic needle to loosen or remove a blockage from the root canal. A hypodermic needle removes much less dentin than a rotary trepan since it does not have the ability to cut the dentinal walls [15]. The current instrument retrieval approach was previously reported by Monteiro JC et al., who used a prepared stainless steel needle in conjunction with a K-file [12]. This permits the clinician to constantly consider removing the broken instrument as a clinical alternative for enhancing the patient's prognosis.

Suter B suggested utilising a small length of stainless steel cylindrical tube, put over the visible tip of the fractured instrument and an H-file pushed through the tube in a clockwise rotating manner to entrap between the tube and the end of the instrument [10]. K-file was chosen instead of H-file in this case due to its structural characteristics. According to Monteiro JC et al., there is an increased chance of additional instrument separation during the tight adaptation between the fractured segment and the H-file. Furthermore, because the active blade is at a lower angle in reference to the instrument's long axis, K-file allows for increased penetration between the fractured fragment and the inner lumen of the needle [12]. Coronal removal of fractured fragment is aided by the extended adaptation of the endodontic file between the fractured fragment and the inner lumen

of the stainless steel needle, especially when the fragment is smooth [12]. The fragment removal with K-file justifies a greater capture and adaptation to improve the separated instrument removal approach.

## CONCLUSION(S)

To conclude, the use of prepared hypodermic surgical needle and K-file led to the successful retrieval of the broken instrument. Adjunctive use of ultrasonics may be beneficial. This technique also provides the added benefit of minimal root dentin removal.

## REFERENCES

- [1] Parashos P, Messer HH. Rotary NiTi instrument fracture and its consequences. *J Endod.* 2006; 32(11):1031-43. Doi: 10.1016/j.joen.2006.06.008.
- [2] Loureiro C, Piazza FA, Jacinto R de C, Cintra LTA, Gomes-Filho JE. Removal of fractured endodontic NiTi file in the apical third of the root canal using an alternative approach. A case report. *Research, Society and Development.* 2021;10(3):e13810313097. Doi: 10.33448/rsd-v10i3.13097.
- [3] Cujé J, Bargholz C, Hülsmann M. The outcome of retained instrument removal in a specialist practice. *Int Endod J.* 2010; 43:545-54. Doi: 10.1111/j.1365-2591.2009.01652.x.
- [4] Shen Y, Peng B, Cheung GS. Factors associated with the removal of fractured NiTi instruments from root canal systems. *Oral Surg Oral Med Oral Pathol Oral Radiol Endod.* 2004; 98(5):605-10. Doi: 10.1016/j.tripleo.2004.04.011.
- [5] Andrabi SM, Kumar A, Iftekhhar H, Alam S. Retrieval of a separated nickel-titanium instrument using a modified 18-gauge needle and cyanoacrylate glue: A case report. *Restor Dent Endod.* 2013; 38(2):93-97. Doi: 10.5395/rde.2013.38.2.93.
- [6] Brito-Júnior M, Normanha JA, Camilo CC, Faria-e-Silva AL, Saquy PC, Ferraz MÃ, et al. Alternative techniques to remove fractured instrument fragments from the apical third of root canals: Report of two cases. *Braz Dent J.* 2015;26(1):79-85. Doi: 10.1590/0103-6440201302446.
- [7] Romeed SA, Dunne SM, Madarati AA. The impact of fractured endodontic file removal on vertical root fracture resistance: Three-dimensional finite element analysis. *Eur J Prosthodont Restor Dent.* 2012;20(2):86-91. Doi: 10.1922/EJPRD\_1069.
- [8] Souter NJ, Messer HH. Complications associated with fractured file removal using an ultrasonic technique. *J Endod.* 2005; 31:450-52. Doi: 10.1097/01.don.0000148148.98255.15.
- [9] Roig-Greene JL. The retrieval of foreign objects from root canals: A simple aid. *J Endod.* 1983; 9(9):394-97. Doi: 10.1016/S0099-2399(83)80193-9.
- [10] Suter B. A new method for retrieving silver points and separated instruments from root canals. *J Endod.* 1998;24(6):446-48. Doi: 10.1016/S0099-2399(98)80032-0.
- [11] Eleazer PD, O'Connor RP. Innovative uses for hypodermic needles in endodontics. *J Endod.* 1999;25(3):190-91. Doi: 10.1016/S0099-2399(99)80140-X.
- [12] Monteiro JC, Kuga MC, Dantas AA, Jordão-Basso KC, Keine KC, Ruchaya PJ, et al. A method for retrieving endodontic or atypical non endodontic separated instruments from the root canal: a report of two cases. *J Contemp Dent Pract.* 2014; 15(6):770-74. Doi: 10.5005/jp-journals-10024-1615.
- [13] Frota LM, Aguiar BA, Aragão MG, de Vasconcelos BC. Removal of separated endodontic k-file with the aid of hypodermic needle and cyanoacrylate. *Case Rep Dent.* 2016; 2016:3970743. Doi: 10.1155/2016/3970743.
- [14] Ingle JL, Bakland LK. *Endodontics.* 4<sup>th</sup> ed. Baltimore: Williams & Wilkins, 1994:300. Doi:10.14219/JADA.ARCHIVE.1995.0138.
- [15] Vivekananda Pai AR, Arora V. Using a syringe needle to cut dentin and dislodge and remove a metallic obstruction from the root canal. *J Conserv Dent.* 2018;21:230-32. Doi: 10.4103/JCD.JCD\_316\_16.

### PARTICULARS OF CONTRIBUTORS:

1. Senior Lecturer, Department of Conservative Dentistry and Endodontics, Rajas Dental College and Hospital, Kavalkinaru, Tamil Nadu, India.
2. Senior Lecturer, Department of Conservative Dentistry and Endodontics, Rajas Dental College and Hospital, Kavalkinaru, Tamil Nadu, India.

### NAME, ADDRESS, E-MAIL ID OF THE CORRESPONDING AUTHOR:

NJ Nagaraj,  
Senior Lecturer, Department of Conservative Dentistry and Endodontics,  
Rajas Dental College and Hospital, Kavalkinaru-627105, Tamil Nadu, India.  
E-mail: dr.njendo1992@gmail.com

### PLAGIARISM CHECKING METHODS: [Jan H et al.]

- Plagiarism X-checker: Sep 06, 2021
- Manual Googling: Jan 03, 2022
- iThenticate Software: Jan 28, 2022 (12%)

### ETYMOLOGY: Author Origin

### AUTHOR DECLARATION:

- Financial or Other Competing Interests: None
- Was informed consent obtained from the subjects involved in the study? Yes
- For any images presented appropriate consent has been obtained from the subjects. Yes

Date of Submission: **Sep 04, 2021**

Date of Peer Review: **Nov 23, 2021**

Date of Acceptance: **Jan 12, 2022**

Date of Publishing: **Mar 01, 2022**