

# Management of Mirizzi Syndrome in a Tertiary Care Centre of Southern India- A Series of 10 Cases

ROHITH MUDDASETTY<sup>1</sup>, SIVAKUMAR KALYANASHANMUGAM<sup>2</sup>, PRABHAKARAN RAJU<sup>3</sup>, SUGUMAR CHIDAMBARANATHAN<sup>4</sup>, NAGANATHBABU OBLA LAKSHMANAMOORTHY<sup>5</sup>



## ABSTRACT

Mirizzi syndrome is a rare condition characterised by obstructive jaundice due to compression of Common Hepatic Duct (CHD) by a stone impacted in the neck of gall bladder. Incidence is around 1-2% in patients with symptomatic cholelithiasis. Preoperative diagnosis and management is challenging. Authors have retrospectively analysed the records of patients undergoing cholecystectomy in our institute for the past five years and selected those patients who had final diagnosis of Mirizzi syndrome were reviewed and following results were arrived. From January 2016 to February 2021, 446 patients underwent cholecystectomy. Out of these, 10 (2.24%) patients had final diagnosis of Mirizzi syndrome. Male:Female ratio was 3:7. Mean age at presentation was 49.5 years. Most common presenting symptoms were pain abdomen and jaundice. Mirizzi syndrome was preoperatively diagnosed only in 3 (30%) patients. Others were diagnosed during surgery. Type I in four patients, type II in three patients, type III in two patients and type IV in one patient. These patients were treated with either total or subtotal cholecystectomy. Open approach was used in 8 (80%) patients and laparoscopic approach in 2 (20%) patients. Biliary drainage procedure was done in all patients, T-tube drainage in 5 (50%); Roux-en-Y Hepaticojejunostomy (HJ) in 3 (30%) and Hepaticoduodenostomy in 2 (20%) patients. Thus, the authors concluded Mirizzi syndrome being one of a rare complication of long standing cholelithiasis, which poses a challenging task for diagnosis and management. High index of suspicion is required to identify and treat Mirizzi syndrome in order to avoid bile duct injuries.

**Keywords:** Choledocholithiasis, Cholelithiasis, Hepaticojejunostomy, Hepaticoduodenostomy

## INTRODUCTION

Pablo Luis Mirizzi, Argentinean Surgeon described "Common Hepatic Duct (CHD) syndrome" in 1948 which was later named after him as Mirizzi syndrome [1]. Mirizzi syndrome can occur up to 0.7-1.4% of patients undergoing biliary surgeries. Incidence may be around 2.7% in high risk population [2]. The pathophysiology is explained by McSherry C and Csendes A et al., [3,4]. Gall stone impacted at the cystic duct or infundibulum or neck of gall bladder lead to compression and obstruction of the CHD. Inflammation sets in the area secondary to pressure ulcer. Eventually stone erodes the common wall leading to formation of fistula [3,4].

Various classifications systems have been described namely Sherry, Puestow, Corlette and Beltran based on the extent of CHD compression or fistulisation. Modified Csendes classification is widely accepted and followed, as it describes the degree of CHD involvement and also includes cholecystoenteric fistula [5].

Type I: External compression of bile duct by a large stone impacted in the cystic duct of Hartmann's pouch.

Type II: Erosion of bile duct wall by gall stones, involving less than one third of its circumference.

Type III: Erosion of bile duct wall by gall stones, involving up to two third of its circumference.

Type IV: Complete destruction of bile duct wall with gall bladder completely fused to bile duct forming single structure.

Type Va: Cholecystoenteric fistula without gall stone ileus.

Type Vb: Cholecystoenteric fistula with gall stone ileus.

Incidence of various types as described by Csendes, Type I: 10.5-78%; Type II: 15-41%; Type III: 3-44%; Type IV: 1-4%; Type V: 29% [6].

Diagnosis is usually done by MRI abdomen with cholangiogram reconstruction. It shows largestones impacted in the gall bladder neck or cystic duct, inflammation gall bladder with proximal dilatation of biliary ducts.

Mirizzi syndrome is a challenge, not only in the diagnosis but also intraoperative management. It can mimic malignancy [6]. It is associated with high risk of bile duct injury and incidence was found to be 0-22% in various reports [6,7].

Standard treatment guidelines have not been established due to rarity and complexity of the disease. Hereby, authors discuss the management of Mirizzi syndrome in the Institute.

## CASE SERIES

Authors have retrospectively analysed records of patients undergoing cholecystectomy in the Institute between January 2016 and February 2021. Among these patients we studied those who had final diagnosis of Mirizzi syndrome. Following data were reviewed: sex, age, symptoms, preoperative imaging, blood investigations, intraoperative findings and procedure done. The diagnosis of Mirizzi syndrome was on the intraoperative finding of CHD compression or fistulisation. Classification was based on Modified Csendes classification [5].

Total of 446 cholecystectomies were performed during this period. Total 10 patients were diagnosed to have Mirizzi syndrome with incidence of 2.24%. Among them three were male and seven were female (M:F=3:7). Mean age of presentation was 49.5±10.86 years. Pain abdomen and jaundice were most common presenting symptoms seen in 9 patients (90%). Fever was present in 6 patients (60%). Loss of appetite was present in 4 patients (40%). On routine investigations, total counts were elevated in seven patients with mean value of 12,997 cells/mm<sup>3</sup>. Elevated bilirubin values were seen in 8 patients (80%) with mean values total bilirubin 7.08 mg/dL and direct bilirubin 5.25 mg/dL. Serum alkaline phosphatase was elevated in 8 patients (80%) with mean value of 459.2 IU/L. All patients had undergone MRCP evaluation in the preoperative period. Among the 10 patients with final diagnosis of Mirizzi syndrome, findings of MRCP were as follows- gall bladder stones identified in 10 patients, dilated CHD in 10 patients and dilated Common Bile Duct (CBD)

in two patients, choledocholithiasis in seven patients. MRCP was suggestive of Mirizzi syndrome in three out of 10 patients (30%) with one patient each having type I, II and III [Table/Fig-1]. Endoscopic Retrograde Cholangiography (ERC) and stone retrieval was successful in three patients who had choledocholithiasis, but ERC was not suggestive of Mirizzi syndrome. One patient had imaging suggestive of gall bladder malignancy in which CA19-9 was 199 U/L, however, intraoperative finding lead to diagnosis of Mirizzi syndrome.

| Parameter                      | Number             |
|--------------------------------|--------------------|
| <b>Sex</b>                     |                    |
| Male                           | 3                  |
| Female                         | 7                  |
| <b>Age (years)</b>             |                    |
| Mean±SD                        | 49.5±10.86         |
| <b>Symptoms</b>                |                    |
| Pain abdomen                   | 9 (90%)            |
| Jaundice                       | 9 (90%)            |
| Fever                          | 6 (60%)            |
| Loss of appetite               | 4 (40%)            |
| <b>Blood investigations</b>    | <b>Mean values</b> |
| Haemoglobin                    | 11.3 g%            |
| Albumin                        | 3.45 g/dL          |
| Total counts                   | 12,997/cumm        |
| Bilirubin                      | 7.08/5.25 mg/dL    |
| Alkaline phosphatase           | 459.2 IU/L         |
| <b>Imaging findings</b>        |                    |
| Gall stones                    | 9 (90%)            |
| Dilated Common Hepatic Duct    | 9 (90%)            |
| Choledocholithiasis            | 7 (70%)            |
| Suggestive of Mirizzi syndrome | 3 (30%)            |

[Table/Fig-1]: Baseline characteristic of patients.

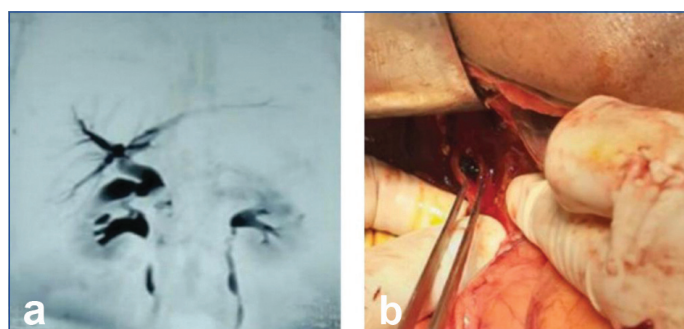
All 10 patients underwent surgery. Eight went for open procedure and two patients for laparoscopic procedure. Total cholecystectomy was done in five patients and subtotal cholecystectomy was done in five patients (50% each). All patients had calculi in gall bladder neck or cystic duct compressing CHD. Size of stone ranged 6-20 mm. Cholecystobiliary fistula was identified in six patients. CBD exploration was done in all the patients and choledocholithiasis was present in six patients. Primary repair of CBD over a T-tube was done in five patients, hepaticoduodenostomy in two patients and Roux-en-Y HJ

in three patients. Based on the above findings and in concurrence with Modified Csendes classification [5], Mirizzi syndrome was classified as Type I in four patients; Type II in two patients; Type III in three patients; Type IV in one patient [Table/Fig 2].

All patients had uneventful postoperative course in hospital. T-tube cholangiogram was performed after six weeks and removed after confirming no residual CBD stones. MRCP image and intraoperative picture of a patient in the present series described in [Table/Fig 3]. Summary of all patients presented in [Table/Fig-4].

| Parameter                       | Number  |
|---------------------------------|---------|
| <b>Approach</b>                 |         |
| Open                            | 8 (80%) |
| Laparoscopic                    | 2 (20%) |
| Total cholecystectomy           | 5 (50%) |
| Subtotal cholecystectomy        | 5 (50%) |
| Choledocholithiasis             | 7 (70%) |
| Cholecystobiliary fistula       | 6 (60%) |
| <b>Drainage</b>                 |         |
| T-tube                          | 5 (50%) |
| Hepaticoduodenostomy            | 2 (20%) |
| Roux-en-Y HJ                    | 3 (30%) |
| <b>Type of Mirizzi syndrome</b> |         |
| I                               | 4 (40%) |
| II                              | 2 (20%) |
| III                             | 3 (30%) |
| IV                              | 1 (10%) |

[Table/Fig-2]: Operative details.



[Table/Fig-3]: a) Magnetic resonance cholangiopancreatography (MRCP) picture showing dilated CHD with cut-off at level of cystic duct insertion; b) Intraoperative picture showing stone at neck of gall bladder after subtotal cholecystectomy.

| Case | Age (in years) | Sex | Symptoms                      | Preoperative diagnosis                   | Final diagnosis           | Procedure done                             | Postoperative period                     |
|------|----------------|-----|-------------------------------|--|---------------------------|--|--|
| 1    | 36             | F   | Jaundice, fever               | Choledocholithiasis                      | Mirizzi syndrome type III | OC, CBDE, Roux-en-Y HJ                     | Uneventful                               |
| 2    | 65             | F   | Pain abdomen, jaundice        | Mirizzi syndrome                         | Mirizzi syndrome type I   | Open SC, CBDE, T-tube                      | T-tube removed after 6 weeks. Uneventful |
| 3    | 55             | M   | Pain abdomen, jaundice        | Choledocholithiasis                      | Mirizzi syndrome type I   | Open SC, CBDE, T-tube                      | T-tube removed after 6 weeks. Uneventful |
| 4    | 65             | F   | Jaundice, fever               | Choledocholithiasis                      | Mirizzi syndrome type III | Open SC, CBDE, T-tube                      | T-tube removed after 6 weeks. Uneventful |
| 5    | 62             | F   | Pain abdomen                  | Mirizzi syndrome/Gall bladder malignancy | Mirizzi syndrome type II  | Open SC, CBDE, Hepaticoduodenostomy        | Uneventful                               |
| 6    | 38             | M   | Jaundice, fever               | Choledocholithiasis                      | Mirizzi syndrome type I   | LC, CBDE, T-tube                           | T-tube removed after 6 weeks. Uneventful |
| 7    | 48             | F   | Jaundice, fever               | Mirizzi syndrome                         | Mirizzi syndrome type III | OC, CBDE, Roux-en-Y HJ                     | Uneventful                               |
| 8    | 43             | F   | Pain abdomen, Jaundice, fever | Choledocholithiasis                      | Mirizzi syndrome type II  | OC, CBDE, Hepaticoduodenostomy             | Uneventful                               |
| 9    | 38             | M   | Pain abdomen, jaundice, fever | Choledocholithiasis                      | Mirizzi syndrome type IV  | OC, CBDE, Roux-en-Y HJ                     | Uneventful                               |
| 10   | 45             | F   | Pain abdomen, jaundice        | Choledocholithiasis                      | Mirizzi syndrome type I   | Lap subtotal cholecystectomy, CBDE, T-tube | T-tube removed after 6 weeks. Uneventful |

[Table/Fig-4]: Summary of patient details.

M: Male; F: Female; OC: Open cholecystectomy; LC: Laparoscopic cholecystectomy; SC: Subtotal cholecystectomy; CBDE: Common bile duct exploration

## DISCUSSION

Mirizzi syndrome is a rare complication of gall stone disease. Incidence of Mirizzi syndrome in the present study is 2.24% which was comparable to incidence mentioned in various literature 1-2% [2] and 4.7% [8]. The mean age of presentation varies between 53-70 years and has a female preponderance (70% patients in literature) [6]. Mirizzi syndrome commonly presents with obstructive jaundice (60-100% patients) and abdomen pain (50-100% patients) [6]. Biochemical investigations routinely show elevated bilirubin and serum alkaline phosphatase values. Cancer Antigen (CA)19-9 values have also been found elevated in Mirizzi syndrome due to proliferating biliary epithelium due to inflammation [9].

Ultrasonography is initial investigation; it shows a contracted gall bladder with stone in the infundibulum or cystic duct, atrophied gall bladder wall and upstream dilation of CHD. Common bile duct may be normal [10]. Computed tomography scans mainly help to rule out malignant tumours [6,10]. MRCP is the preferred modality of imaging; it shows presence of stone at infundibulum compressing the biliary tree with upstream dilation. However, MRCP cannot effectively localise fistula [10]. The diagnostic accuracy of MRCP is only 50% [10,11]. Endoscopic Retrograde Cholangiopancreatography (ERCP) being an invasive procedure can identify the compression of CHD and also presence of fistula. Diagnostic accuracy of ERCP reaches 55-90% [11,12]. In up to 50% of the cases diagnosis of Mirizzi Syndrome will be done intraoperatively, where findings of shrunken gall bladder, distorted Calot's triangle, stone impacted in the neck or cystic duct, reflux of bile as the impacted stone is removed are seen [7]. In the present case series, only 30% of patients had preoperative diagnosis of Mirizzi syndrome.

Type I Mirizzi syndrome is most common type to be encountered, 10.5-78% incidence. Followed by type II and III; 15-41% and 3-44%, respectively. Comparison of various parameters with literature data has been tabulated in [Table/Fig-5] [2,6,8,10,11]. Treatment of

Mirizzi syndrome is always surgical. It has increased risk of bile duct injury due to tissue oedema, inflammation, dense adhesions and distorted anatomy [13]. Open approach is preferred, however, as advances in laparoscopy are made, it is also an alternative [14]. Subtotal cholecystectomy and removal of impacted stone is the treatment of choice. In the presence of fistula, reconstruction of bile duct would be necessary. It can be done as primary repair over T-tube or choledochoplasty with remnant gall bladder wall or bilio-enteric anastomosis. Baer HU et al., have described cholecysto-choledochoduodenostomy for Mirizzi syndrome type II or higher [13]. Safioleas M et al., have described cholecysto-choledochojejunostomy [15]. Standard Roux-en-Y HJ is also advocated. All patients should undergo CBDE since, there is high chance of choledocholithiasis.

In the present series, type I cases were treated with total or subtotal cholecystectomy and bile duct drained over a T-tube. In both type II cases, subtotal cholecystectomy was done and hepaticoduodenostomy was done. In type III cases, total or subtotal cholecystectomy was done with Roux-en-Y HJ as preferred method of drainage. In type IV case, total cholecystectomy and Roux-en-Y HJ was done. These patients had uneventful postoperative period.

## CONCLUSION(S)

Mirizzi syndrome is one of the rare complications of long standing cholelithiasis. High index of suspicion is required in diagnosis especially in elderly females presenting with obstructive jaundice or cholangitis. Elevated tumour marker may mislead us to diagnose malignancy. Hence, it should be carefully considered in presence of jaundice. Imaging studies may miss the diagnosis in more than half of cases. Meticulous surgery can prevent inadvertent bile duct injury and spare patients from long term morbidity.

## Acknowledgement

Authors would like to acknowledge the help of all our colleagues of the Institute in publication of the present article.

## REFERENCES

- [1] Leopardi LN, Maddern GJ. Pablo Luis Mirizzi: The man behind the syndrome. ANZ J Surg. 2007;77(12):1062-64.
- [2] Abou-Saif A, Al-Kawas FH. Complications of gallstone disease: Mirizzi syndrome, cholecystocholedochal fistula, and gallstone ileus. Am J Gastroenterol. 2002;97(2):249-54.
- [3] MCSherry C. The Mirizzi syndrome: Suggested classification and surgical therapy. Surg Gastroenterol. 1982;1:219-25.
- [4] Csendes A, Diaz JC, Burdiles P, Maluenda F, Nava O. Mirizzi syndrome and cholecystobiliary fistula: A unifying classification. Br J Surg. 1989;76(11):1139-43.
- [5] Beltran MA, Csendes A, Cruces KS. The relationship of Mirizzi syndrome and cholecystoenteric fistula: Validation of a modified classification. World J Surg. 2008;32(10):2237-43.
- [6] Beltrán MA. Mirizzi syndrome: History, current knowledge and proposal of a simplified classification. World J Gastroenterol. 2012;14;18(34):4639-50. Available from: <https://www.ncbi.nlm.nih.gov/pmc/articles/PMC3442202/>.
- [7] Lai EC, Lau WY. Mirizzi syndrome: History, present and future development. ANZ J Surg. 2006;76(4):251-57.
- [8] Ruiz MC, García AV. Frequency of the Mirizzi syndrome in a teaching hospital. Cir Gen. 2003;25(4):334-37.
- [9] Sanchez M, Gomes H, Marcus EN. Elevated CA 19-9 levels in a patient with Mirizzi syndrome: Case report. South Med J Birm Ala. 2006;99(2):160-63.
- [10] Chen H, Sivo EA, Khu M, Tian Y. Current trends in the management of Mirizzi Syndrome: A review of literature. Medicine (Baltimore). 2018;97(4):e9691.
- [11] Safioleas M, Stamatakos M, Safioleas P, Smyrnis A, Revenas C, Safioleas C. Mirizzi Syndrome: An unexpected problem of cholelithiasis. Our experience with 27 cases. Int Semin Surg Oncol. 2008;5:12.
- [12] Boutallaka H, Seddik H, Mrabti S, Addajou T, Sair A, Benhamdane A, et al. Role of ERCP in diagnosis and treatment of Type I Mirizzi Syndrome: A case series with review of literature. J Gastroenterol Hepatol Res. 2020;9(1):3071-76.

| Characteristics                                 | Present study | Literature data | References   |
|---|---------------|-----------------|--|
| Age at presentation in years                    | 36-65         | 53-70           | Beltran MA, Chile 2012 [6]   |
| Incidence                                       | 2.24%         | 1-4.7%          | Abou-Saif A and Al-Kawas FH Washington 2002 [2]<br>Ruiz MC and García AV Mexico 2003 [8] |
| <b>Symptoms</b>                                 |               |                 |  |
| Abdomen pain                                    | 90%           | 60-100%         | Beltran MA, Chile 2012 [6]   |
| Jaundice  | 90%           | 50-100%         |  |
| Preoperative diagnosis by MRCP                  | 30%           | 50%             | Chen H et al., Missouri 2018 [10]<br>Safioleas M et al., Greece 2008 [11]                |
| <b>Distribution of types in final diagnosis</b> |               |                 |  |
| Type I  | 40%           | 10.5-78%        | Beltran MA, Chile 2012 [6]   |
| Type II   | 20%           | 15-41%          |  |
| Type III  | 30%           | 3-44%           |  |
| Type IV   | 10%           | 1-4%            |  |

[Table/Fig-5]: Comparison of present data with various literature [2,6,8,10,11].

- [13] Baer HU, Matthews JB, Schweizer WP, Gertsch P, Blumgart LH. Management of the Mirizzi syndrome and the surgical implications of cholecystocholedochal fistula. *Br J Surg.* 1990;77(7):743-45.
- [14] Yeh CN, Jan YY, Chen MF. Laparoscopic treatment for Mirizzi syndrome. *Surg Endosc.* 2003;17(10):1573-78.
- [15] Safioleas M, Stamatakos M, Revenas C, Chatziconstantinou C, Safioleas C, Kostakis A. An alternative surgical approach to a difficult case of Mirizzi syndrome: A case report and review of the literature. *World J Gastroenterol WJG.* 2006;12(34):5579-81.

**PARTICULARS OF CONTRIBUTORS:**

1. Postgraduate Student, Institute of Surgical Gastroenterology, Madras Medical College, Chennai, Tamil Nadu, India.
2. Assistant Professor, Institute of Surgical Gastroenterology, Madras Medical College, Chennai, Tamil Nadu, India.
3. Associate Professor, Institute of Surgical Gastroenterology, Madras Medical College, Chennai, Tamil Nadu, India.
4. Professor, Institute of Surgical Gastroenterology, Madras Medical College, Chennai, Tamil Nadu, India.
5. Director and Professor, Institute of Surgical Gastroenterology, Madras Medical College, Chennai, Tamil Nadu, India.

**NAME, ADDRESS, E-MAIL ID OF THE CORRESPONDING AUTHOR:**

Naganathbabu Obla Lakshmanamoorthy,  
 Director and Professor, Institute of Surgical Gastroenterology, Madras Medical College,  
 Chennai, Tamil Nadu, India.  
 E-mail: naganathbabu@gmail.com

**PLAGIARISM CHECKING METHODS:** [\[Jan H et al.\]](#)

- Plagiarism X-checker: Jul 26, 2021
- Manual Googling: Nov 13, 2021
- iThenticate Software: Jan 04, 2022 (6%)

**ETYMOLOGY:** Author Origin**AUTHOR DECLARATION:**

- Financial or Other Competing Interests: None
- Was informed consent obtained from the subjects involved in the study? No
- For any images presented appropriate consent has been obtained from the subjects. Yes

Date of Submission: **Jul 23, 2021**  
 Date of Peer Review: **Nov 15, 2021**  
 Date of Acceptance: **Jan 05, 2022**  
 Date of Publishing: **Mar 01, 2022**