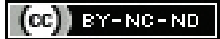

# Percutaneous Balloon Retrieval Technique for Fractured Biliary Drainage Catheter in a Paediatric Patient: Can a Major Surgery be Averted?

AMRIN ISRARAHMED<sup>1</sup>, SOMESH SINGH<sup>2</sup>, RANA VISHWADEEP MALL<sup>3</sup>, RAJANIKANT R YADAV<sup>4</sup>

## ABSTRACT

Percutaneous Transhepatic Biliary Drainage (PTBD) involves temporary placement of an external drainage catheter into an obstructed bile duct prior to internal biliary stenting or surgery. Chronic indwelling PTBD catheters can develop surrounding adhesions and are prone to fractures and retention during their removal. Retained segments can cause impaired biliary drainage, inflammation and recurrent cholangitis. Retrieval of retained catheters can be done by endoscopic/surgical/percutaneous techniques. In patients who have undergone Hepatico-Jejunostomy (HJ), endoscopic removal is not possible and percutaneous/surgical removal are the only options. The authors present a case of a five-year-old child who came for removal of a fractured, retained PTBD catheter, nine months after undergoing HJ. The catheter was removed by a percutaneous balloon retrieval technique. The objective here is to highlight the technical challenges encountered and present a modification of the usual balloon retrieval technique used to successfully remove the catheter and thus avert a major surgery.

**Keywords:** Adhesions, Cholangitis, Hepatico-jejunostomy, Percutaneous transhepatic biliary drainage, Retained catheter

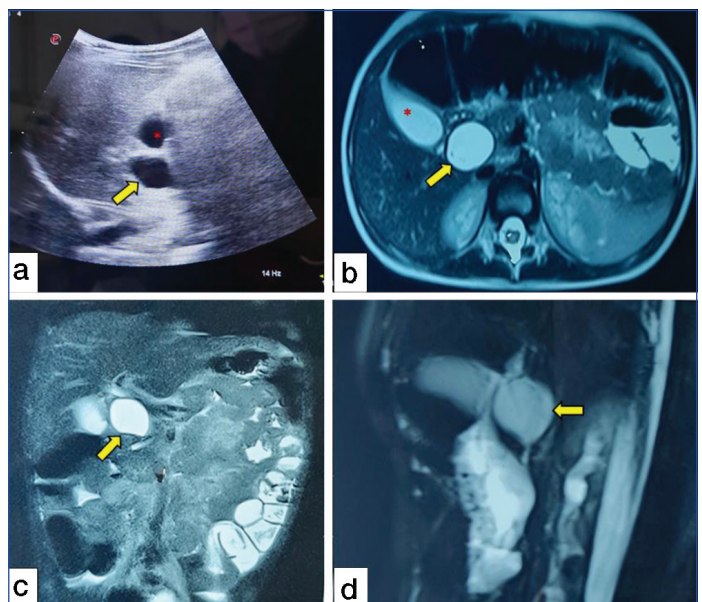
## CASE REPORT

A five-year-old male child presented to the department with complains of abdominal pain, fever and yellowish discoloration of skin for 15 days. Biochemical examination has been summarised in [Table/Fig-1], which revealed features of cholangitis. Abdominal ultrasound showed probe tenderness in the right upper quadrant with cystic dilatation of the Common Bile Duct (CBD) [Table/Fig-2a]. A subsequent Magnetic Resonance Cholangiopancreatography (MRCP) showed findings suggestive of a Type I choledochal cyst [Table/Fig-2b-d]. The patient was diagnosed to have choledochal cyst with cholangitis hence, an emergency segment V PTBD was done. A 10Fr Malecot catheter (Devon Innovations Pvt., Ltd., Bengaluru, Karnataka, India) was placed and adequate antibiotics (intravenous ceftriaxone 50 mg/kg/day for seven days) were given. The child underwent excision of choledochal cyst with Hepatico-Jejunostomy (HJ) after resolution of cholangitis. He developed postoperative cholangitis hence the PTBD catheter was not removed and he was started on antibiotics. After multidisciplinary discussion, the child was discharged with the catheter in situ with a

Parameters	Value	Normal range
<b>Liver function tests</b>		
Total bilirubin	3.6 mg/dL	0.2-1.2 mg/dL
Conjugated bilirubin	2.9 mg/dL	0.1-0.3 mg/dL
Total serum proteins	6.8 gm/dL	6.0-8.0 gm/dL
Serum albumin	3.7 gm/dL	3.8-5.5 gm/dL
Serum SGOT	49 IU/L	8.0-40.0 IU/L
Serum SGPT	56 IU/L	8.0-40.0 IU/L
Serum alkaline phosphatase	1440 IU/L	60.0-270.0 IU/L
<b>Renal function test</b>		
Serum creatinine	0.53 mg/dL	0.5-1.3 mg/dL
<b>Coagulation profile</b>		
Prothrombin time	18.5 s	9.5-13.5 s
International Normalised Ratio (INR)	1.38	<1.3

Haemogram		
Haemoglobin	11.1 g/mL	10.0-14.0 g/mL
Platelets	4,92,000/mL	1,50,000-4,00,000/mL
Total Leukocyte Counts (TLC)	15,000/mL	4,000-11,000/mL
Viral Markers		
HBsAg	Non reactive	
Ant-HCV antibody	Non reactive	
Anti-HAV IgM antibody	Non reactive	
Anti-HEV IgM Antibody	Non reactive	

[Table/Fig-1]: Serological work-up of patient.



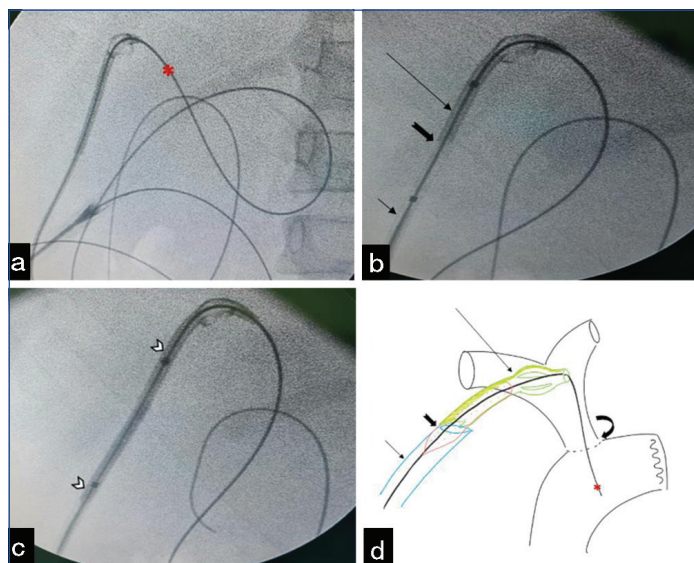
[Table/Fig-2]: Imaging findings; a) Abdominal ultrasound shows a dilated Common Bile Duct (CBD) (yellow arrows a-d); red asterisk in a&b denotes distended normal gall bladder; (b & c) T2 weighted axial and coronal images respectively show dilatation of CBD suggestive of choledochal cyst; c) Thick slab coronal oblique MR cholangiopancreatography shows saccular dilatation of CBD with normalisation of calibre of distal CBD.

plan to review after four weeks with percutaneous cholangiography (to assess HJ patency).

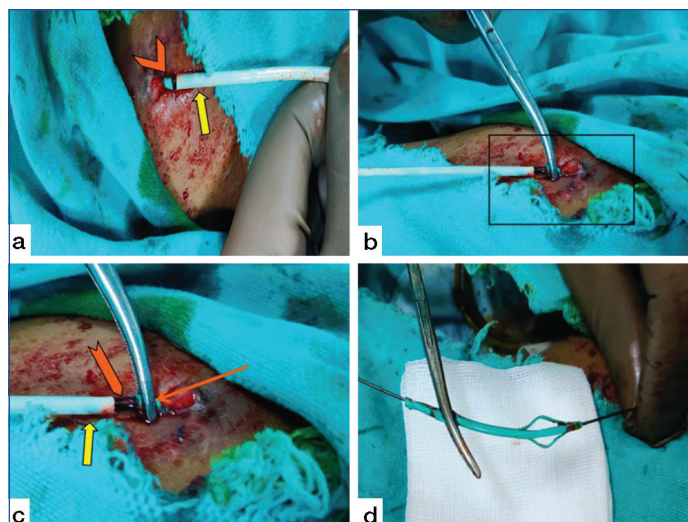
In view of Coronavirus Disease 2019 (COVID-19) pandemic, the patient missed his follow-up and presented nine months after discharge. Abdominal ultrasound showed no dilatation of intrahepatic biliary radicles and a percutaneous cholangiogram via the PTBD catheter showed patent HJ site with free flow of contrast, hence removal of PTBD catheter was planned. While removing the catheter under fluoroscopic guidance the catheter fractured, with nearly 4 cm of catheter within hepatic parenchyma, the tip of which was lying within the duct whereas the outer end was abutting the outer capsular margin of liver.

As one end of the catheter was within the biliary duct and the other end was abutting the hepatic capsule, there was a risk of biloma formation or biliary peritonitis. As the outer end of catheter was not visible externally, so we could not retrieve it with forceps but as the catheter tract had matured, it was re-cannulated using a hydrophilic guide wire of 150 cm (Radifocus, Terumo, Tokyo, Japan) which was secured across the HJ site [Table/Fig-3a]. A 10Fr sheath was introduced over the wire and tip of sheath was carefully approximated with the outer fractured end of catheter under fluoroscopic guidance [Table/Fig-3b]. A 5x40 mm balloon catheter (Mustang, Boston Scientific, Natick, MA, USA) was partially deployed such that the distal half of balloon (~20 mm) was within the fractured fragment and proximal half within sheath. The balloon was then partially inflated using a 1:1 ratio of water-soluble non ionic iodinated contrast agent (Lohexol {Omnipaque, 300 mg/mL}), GE Healthcare; Marlborough, United States) and normal saline [Table/Fig-3c]. This partially inflated balloon was slowly pulled out while keeping the sheath and catheter closely approximated to each other [Table/Fig-3d]. Thus, the team were able to retrieve the peripheral part of the fractured fragment outside the skin and the outer stem was then gripped with a metallic artery forceps and pulled to completely retrieve it [Table/Fig-4].

Repeat blood investigations revealed normalisation of TLC counts ( $6500/\text{mm}^3$ ), hence the child was discharged with follow-up advised at 3, 6, 12 months in first year and annually thereafter. The child has completed six months of follow-up and is doing well clinically. Written informed consent was obtained prior to performing the procedure. Waiver of consent was obtained from our Institutional Ethics Committee (IEC) in view of retrospective reporting of this case.



**[Table/Fig-3]:** Technical aspects with diagrammatic representation of steps involved in retrieval of fractured biliary catheters; a) guide wire (red asterisk) across the HJ site after traversing through the lumen of broken catheter; b) catheter (long arrow) and sheath (short arrow) approximated to each other (notched arrow); c) partially inflated balloon (white arrow heads) between the sheath and malecot catheter; d) diagrammatic representation of the modified technique of retrieval with green catheter (long arrow) and its distal flower within the biliary system, red asterisk demonstrates the guide wire across the HJ site (curved arrow), blue sheath (short arrow) closely approximated to the broken catheter (notched arrow) with a partially inflated red balloon within it.



**[Table/Fig-4]:** Retrieval of fractured catheter with the help of over the wire balloon catheter and artery forceps; a) green coloured catheter (arrow head) seen just above the skin surface in close approximation to the catheter (yellow arrow); b) artery forceps holding the proximal stem of the broken catheter; c) magnified image with partially inflated balloon (notched arrow) across the sheath (yellow arrow) and proximal stem of the catheter (orange arrow); d) the broken catheter retrieved successfully.

## DISCUSSION

Percutaneous Transhepatic Biliary Drainage (PTBD) is a minimally invasive technique of decompressing the biliary system [1]. The primary aim is to prevent or ameliorate cholangitis [2]. It is a temporary procedure until a more definitive treatment such as biliary stenting or surgery is established.

Prolonged indwelling catheters within the biliary system need regular exchange or flushing as they are prone to adhesions, fracture, obstruction, dislodgement and/or buckling [3,4]. The presurgery (prior to HJ surgery) laboratory investigations as summarised earlier were suggestive of cholangitis, hence PTBD was done in the present case [5]. These catheters should not be left indwelling for a long time. The incidence of fracture increases in patients who are lost to follow-up. Fractured retained catheters are a challenge with respect to their removal. Some authors believe that the fractured segment may be left in situ if it is not causing any significant obstruction [4]. However, these catheters can become a source of biliary obstruction, inflammation, stricture and/or recurrent cholangitis [1]. Moreover, if the fractured segment does not lie entirely within the biliary system (as in the present case); they can cause biloma and liver abscesses [2]. Additionally, in this case, the proximal tip of the catheter was abutting the hepatic capsule with a potential risk of biliary peritonitis.

The various options for retrieval of such fragments include: endoscopic, surgical and percutaneous approaches. Endoscopic retrieval comprises of cannulating the CBD via the ampulla and snaring out the fractured fragment within the biliary system. However, due to altered biliary anatomy (post HJ status) in this patient, this option was technically challenging. Also, as some PTBD catheters are rigid with sharp edges, there can be a risk of bowel obstruction, perforation, or fistula formation using the endoscopic approach [6]. Surgical treatment would be more morbid and would be associated with increased hospital stay.

Few case reports of percutaneous retrieval have been described with the help of biopsy forceps, goose snare or balloon catheters [2,7-9]. As the fractured fragment was not seen at the skin surface, retrieving it by biopsy forceps was not feasible in the present case. Retrieval by balloon catheters or by goose snares require secure placement of a percutaneous sheath within the biliary system. Availability of appropriately sized goose snares is another concern. Balloon retrieval technique by conventional method requires, a secure placement of sheath within the biliary system, followed by balloon inflation central/distal to the fractured segment and then pulling the balloon back

so as to displace the fractured segment proximally into the sheath [2,4]. The balloon can be introduced via the lumen of the fragmented catheter or via a wire parallel to the catheter. Once this is achieved, the fractured segment can be extracted or snared into the sheath [2]. In the present case, the tip of the fractured segment was abutting the hepatic surface and hence placement of sheath securely within biliary system was not feasible. Hence, there was a modification in the balloon retrieval technique as described above. It is important to keep the ends of the sheath and the fractured fragment closely approximated during the entire retrieval process. Failure to do so would result in inflation of the balloon in the liver parenchyma with a potential of bilio-vascular or hepatic capsular injury.

## CONCLUSION(S)

Regular exchanges/flushing/repositioning of prolonged indwelling biliary catheters is essential to avoid complications like catheter blockage, fractures, adhesions and fibrosis. In patients with post HJ status removal of fractured catheters by endoscopy is technically challenging, hence percutaneous retrieval techniques are important. Balloon catheter assisted retrieval of retained fragment with modification of conventional technique can help avert a major surgery in these patients.

## REFERENCES

- [1] Kwan JR, Low KSH, Lohan R, Shelat VG. Percutaneous transhepatic biliary drainage catheter fracture: A case report. *Ann Hepatobiliary Pancreat Surg.* 2018;22(3):282-86.
- [2] Hsien-Tzu L, Hsiao Shan T, Nai Chi C, Yi Yang L, Yi You C, Chien An L. Percutaneous transhepatic techniques for retrieving fractured and intrahepatically dislodged percutaneous transhepatic biliary drainage catheters. *Diagn Interv Radiol.* 2017;23(6):461-64.
- [3] Venkatanarasimha N, Damodharan K, Gogna A, Leong S, Too CW, Patel A, et al. Diagnosis and management of complications from percutaneous biliary tract interventions. *Radiographics.* 2017;37(2):665-80.
- [4] Maher MM, Kealey S, McNamara A, O'Laoidhe R, Gibney RG, Malone DE. Management of visceral interventional radiology catheters: A troubleshooting guide for interventional radiologists. *Radiographics* 2002;22(2):305-22.
- [5] Food and Drug Administration. Investigations operations manual 2021 Appendix C. Blood serum chemistry—normal values <https://www.fda.gov/media/75935/download>.
- [6] Namdar T, Raffel AM, Topp SA, Namdar L, Alldinger I, Schmitt M, et al. Complications and treatment of migrated biliary endoprostheses: A review of the literature. *World J Gastroenterol.* 2007;13:5397-99.
- [7] Gumus B. Percutaneous intervention strategies for the management of dysfunctioning biliary plastic endoprostheses in patients with malignant biliary obstruction. *Diagn Interv Radiol.* 2012;18:503-07.
- [8] Saad WE. Percutaneous transhepatic techniques for removal of endoscopically placed biliary plastic endoprostheses. *Tech Vasc Interv Radiol.* 2008;11:120-32.
- [9] Gupta M. Rare case of removal of intrabiliary retained broken PTBD wire with redo-hepaticojejunostomy. *Int Surg J.* 2019;6(3):1003-06.

### PARTICULARS OF CONTRIBUTORS:

1. Senior Resident, Department of Radiodiagnosis, Sanjay Gandhi Postgraduate Institute of Medical Sciences, Lucknow, Uttar Pradesh, India.
2. Senior Resident, Department of Radiodiagnosis, Sanjay Gandhi Postgraduate Institute of Medical Sciences, Lucknow, Uttar Pradesh, India.
3. Senior Resident, Department of Radiodiagnosis, Sanjay Gandhi Postgraduate Institute of Medical Sciences, Lucknow, Uttar Pradesh, India.
4. Additional Professor, Department of Radiodiagnosis, Sanjay Gandhi Postgraduate Institute of Medical Sciences, Lucknow, Uttar Pradesh, India.

### NAME, ADDRESS, E-MAIL ID OF THE CORRESPONDING AUTHOR:

Rajanikant R Yadav,  
SGPGIMS Campus, Type IV MRA, Staff Residence, Lucknow, Uttar Pradesh, India.  
E-mail: rajani24478@rediffmail.com

### PLAGIARISM CHECKING METHODS: [Jain H et al.]

- Plagiarism X-checker: Sep 14, 2021
- Manual Googling: Jan 18, 2022
- iThenticate Software: Feb 24, 2022 (6%)

### ETYMOLOGY: Author Origin

### AUTHOR DECLARATION:

- Financial or Other Competing Interests: None
- Was informed consent obtained from the subjects involved in the study? Yes
- For any images presented appropriate consent has been obtained from the subjects. Yes

Date of Submission: **Sep 13, 2021**

Date of Peer Review: **Dec 20, 2021**

Date of Acceptance: **Jan 19, 2022**

Date of Publishing: **Mar 01, 2022**