

Respirators and Surgical Masks Artefacts on Phantom using Magnetic Resonance Imaging during COVID-19: A Cross-sectional Study

SHASHI KUMAR SHETTY¹, MM JASEEMUDHEEN², U RAGHURAJ³, R KAYALVIZHI⁴

ABSTRACT

Introduction: It is suitable for a patient to wear a respirator or face mask during any radiological investigation during Severe Acute Respiratory Syndrome Corona Virus 2 (SARS-CoV-2) pandemic. Some face masks may have nanoparticles, or antimicrobial coating, which may comprise metal to help shape the mask according to user face shape. This kind of ferromagnetic substances can cause artefacts in the image.

Aim: To detect and compare the artefacts while using different types of respirators and surgical masks in the Magnetic Resonance Imaging (MRI) phantom images.

Materials and Methods: This was a prospective cross-sectional study which was conducted from July 2021-September 2021. Two not resistant to oil-based aerosols with 95% efficiency to airborne particles (N95) respirators and two types of 3-ply surgical disposable masks with a metal and plastic nose holder were used. The N95 respirators were of Halo N95 Filtering Facepiece 2 Particulate Matter (FFP2) PM 2.5 and Suchi N95 S-7400, while the surgical masks were from Venus 3-ply V-1010 with a metal nose

holder and the Thea Tex Filtra 3-ply with plastic nose holder. A polymethyl methacrylate plastic phantom was used with 1.5 Tesla (Siemens Magnetom Avanto) MRI scanner for imaging.

Results: When exposed to the metal detector both N95 respirators and one of the surgical masks with a metal nose clip showed strong ferromagnetic attraction. Both respirators and a surgical mask with a metal nasal holder showed magnetic susceptibility artefacts. The signal loss is caused by dephasing of spins from metal strip on the image.

Conclusion: All the patients must have a recognised MR safe masks prior to an MRI investigation. When this is not possible to follow, metallic components from the face mask should be removed before the patient's arrival at the MR room. After removing the metal strip from the mask, the paper tape may be applied across the nasal bridge region for adequate transmission control and to maintain the intended function of the mask. The mask with a plastic nasal holder was ideal to use in an MR environment since it doesn't have any distortion in the image.

Keywords: Coronavirus disease-2019, Metal, Nanoparticles, Pandemic, Severe acute respiratory syndrome coronavirus 2

INTRODUCTION

Since the first case of Severe Acute Respiratory Syndrome Coronavirus 2 (SARS-CoV-2) was reported in Wuhan city, China in December 2019, it has spread worldwide, and the World Health Organisation (WHO) has declared it as a pandemic on 11th March 2020 [1]. The SARS-CoV-2 is transmitted through droplets from the affected individuals. The viral Ribonucleic Acid (RNA) has been seen in air sampling in numerous studies [2,3]. Worldwide, all medical professionals and public are affected by the Coronavirus Disease-2019 (COVID-19) infection, which predominantly affects respiratory system. Every hospital and healthcare centres across the world had to adapt and equip themselves to handle the prevalence of the infection depending on their specific characteristics by implementing governments' recommendations and preventative medical measures.

The practice of health service was swamped and had to face up to the new circumstances by radiology department [4]. The MRI scans during the COVID-19 pandemic are a big challenge in the radiology department. Radiology departments across the world had to implement several new recommendations to handle the overwhelming health crisis [5-7]. Performing MRI scan despite the pandemic situation, subject to a risk/benefit analysis. In case of non-critical investigations, the recommendation has been to postpone them and establish levels of priority [8-10]. To detect potential cases, screening questionnaires have been carried out through telephonic conversation before the arrival of patient [11]. Social distancing has

been imposed in waiting rooms, and masks made mandatory for all patients and public coming to radiology department [12].

During COVID-19 pandemic, the usage of masks or various medical devices, like ventilators, in radiology departments becomes inevitable. It is essential to make sure that they are compatible to the MRI atmosphere for safety purposes while ensuring no compromises to the image quality [12-15]. Facemasks by some manufacturers integrate metallic fibres or metallic nanoparticles to improve antimicrobial properties. These metal strips can heat up during MRI and pose a risk of burn to the patients [13]. Furthermore, these metal strips may produce artefacts degrading the image quality. The MR staff members and the patients wearing respirators and facemasks may not be aware of MRI safety of it [16]. However, using face masks in the MR environment are expected to provide some level of protection by reducing the spread of COVID-19 infection to MR personnel and the patients [17,18]. As pandemic changed people's lives, wearing masks has become essential and there is an information gap on how it will affect MR image quality and their safety in MR environment. This study will help to bridge this information gap by detecting and comparing the artefacts in different types of respirators and surgical masks. This will help in analysing their MR safety and their effect on image quality during investigations.

MATERIALS AND METHODS

This was prospective cross-sectional quality-improvement study approved by the Institutional Ethics Committee (IEC) (Reg. No. EC/

NEW/INST/2020/834). The study was conducted from July 2021-September 2021 with the use of 1.5 Tesla MRI scanner (Siemens Magnetom Avanto TIM + DOT system) in the Department of Radiodiagnosis and Imaging, KS Hegde Hospital, Mangalore, Karnataka, India. Four types of face masks were included, two N95 respirators from different companies (HALO N95 FFP2 PM 2.5 and Suchi N95 S-7400) and two types of 3-ply surgical disposable masks, VENUS 3-ply V-1010 with a metal nose holder and the Thea Tex Filtra 3-ply surgical mask with a plastic nose holder. No specific exclusion criteria was there as there was no patient involvement in this study. All four face masks were first exposed under X-ray to assess their radiopacity. Also, they were screened using metal detector to detect the presence of metal in nose bridge strips of the respirators and face masks.

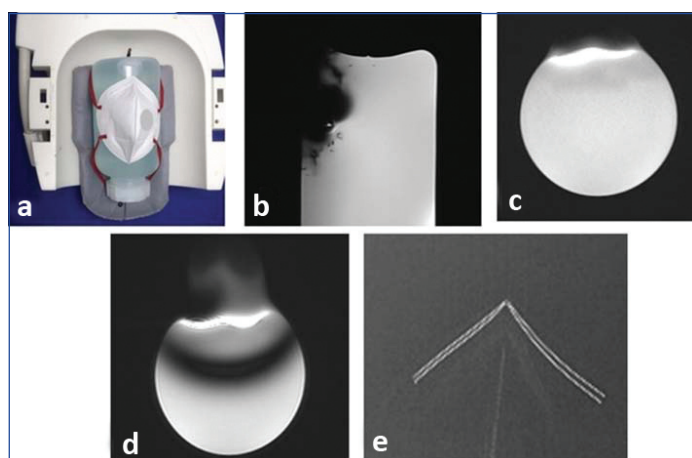
A standard cylindrical water phantom made of polymethyl methacrylate plastic with dimensions of 12x24 cm (diameterxheight), where the head of a hypothetical patient would be positioned. Further, each mask was placed on the MR phantom were imaged individually with a MR head coil with three routine brain spin echo sequences including Fluid Attenuated Inversion Recovery (FLAIR), T2 axial Turbo Spin Echo (TSE) and T1 sagittal TSE was performed [Table/Fig-1].

Sequence	TR (ms)	TE (ms)	FOV (mm)	Matrix	Flip angle	Slice thickness (mm)
FLAIR	9000	95	230	256x256	180°	5
T1 TSE	563	15	230	320x290	90°	5
T2 TSE	4000	104	220	448x406	90°	5

[Table/Fig-1]: MR Sequences and parameters.
 FLAIR: Fluid attenuated inversion recovery; TSE: Turbo spin echo; TR: repetition time; TE: Echo time; FOV: Field of view


RESULTS

When all the four respirator masks were exposed to X-ray, all showed radiopacity with least opacity from Thea Tex Filtra 3-ply surgical mask. They were screened with the metal detector, both N95 respirators (HALO N95 FFP2 PM 2.5 and Suchi N95 S-7400) and VENUS 3-ply V-1010 surgical mask indicated the presence of metal in the nose bridge strips, unlike Thea Tex Filtra 3-ply surgical mask. Additionally, when assessed under MRI, except Thea Tex Filtra 3-ply surgical mask, other three masks underwent considerable translational/torque forces when kept close to the MRI magnet and completely lost contact with the phantom. They were held in place using ear loops around the water phantom. There was a significant susceptibility artefact on spin echo imaging for both N95 respirators [Table/Fig-2,3].

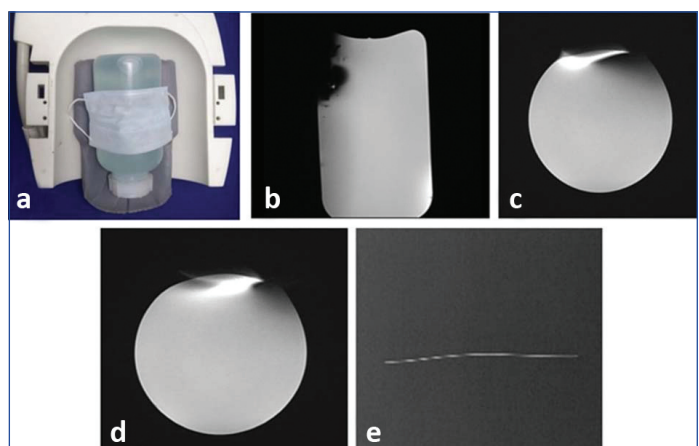


[Table/Fig-2]: Positioning of the N95 (Suchi) respirator in MR head coil (a), Spin-echo sequences showing susceptibility artefact on anterior aspect of the phantom due to the respirator in the T1 Sagittal (b), FLAIR axial (c) and T2 axial (d), Radiopacity shown in exposed respirator (e).

Furthermore, the VENUS 3-ply V-1010 surgical mask had a metal strip in the mask which acts as the nose bridge. This nose bridge strip produced substantial local susceptibility artefact on Spin-echo imaging with no obvious heating [Table/Fig-4].

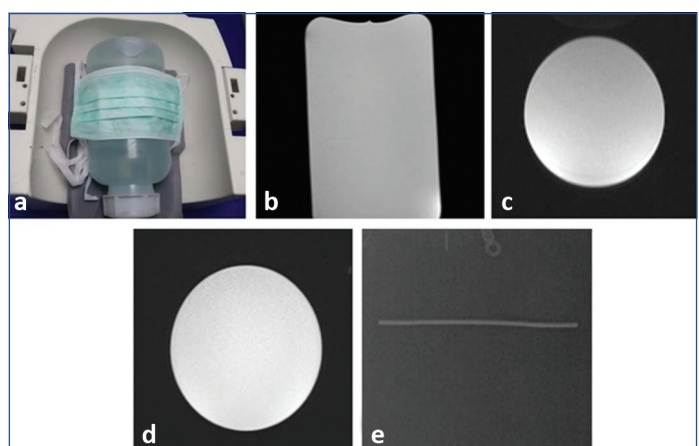


[Table/Fig-3]: Positioning of the N95 (Halo) respirator in MR head coil (a), Spin-echo sequences showing susceptibility artefact on anterior aspect of image of the phantom due to the respirator in the T1 Sagittal (b), FLAIR axial (c) and T2 axial (d), Radiopacity shown in exposed respirator (e).



[Table/Fig-4]: Positioning of the surgical mask with metal nose holder in MR head coil (a), Spin-echo sequences showing susceptibility artefact on anterior aspect of image of the phantom due to the respirator in the T1 Sagittal (b), FLAIR axial (c) and T2 axial (d), Radiopacity shown in exposed mask (e).

The Thea Tex Filtra 3-ply surgical mask did not show any evidence of ferromagnetism to the metal detector or when resting on the phantom on the MRI table since it doesn't contain any metal strip. There was no artefact on Spin-echo imaging [Table/Fig-5].



[Table/Fig-5]: Positioning of the surgical mask with plastic holder in MR head coil (a), Spin-echo sequences showing no artefacts on image of phantom in the T1 Sagittal (b), FLAIR axial (c) and T2 axial (d), Radiopacity shown in exposed mask (e).

DISCUSSION

The MRI provides excellent soft-tissue contrast and allows the evaluation of specific tissue components in different sequences. Given these strengths, MRI has shown diagnostic superiority over Computed Tomography (CT) techniques in various soft tissue associated pathologies in the head and neck region [19]. The use of spin echo sequences over gradient echo sequences was preferred

due to their inherent ability to be less Susceptible to the metal-induced artefacts [20]. It is suitable for a patient to wear a face mask for an MRI during the COVID-19 pandemic. The two N95 respirators and a surgical mask with metal strip were used for the current study and shows susceptibility artefact in the anterior aspect of the phantom. In addition, the study conducted by the Murray OM et al., used two types of masks, one of which had nasal bridge metal holder and the other had bilateral ferromagnetic staples, shown susceptibility artefact on anterior and lateral respectively [21]. Before MRI begins, MR technologists should check the face mask for metal. Some face masks may have nanoparticles, or antimicrobial coating, which may be made up of metal to help shape the mask according to user's face shape. This metal can cause in Radio Frequency (RF)-induced heating [22]. The induced heating can be influenced by the magnetic field strength or use of higher Specific Absorption Rate (SAR) sequences [23]. This may signify a hazard for patients during MRI in COVID-19 pandemic. The magnetic field disparities cause large resonant frequency variations, resulting in a variety of artefacts in MRI. When the field changes quickly with position, there is substantial dephasing of the signal, and subsequent signal loss [24].

The N95 respirators are specifically designed to protect users from small airborne particles, including aerosols. Asadi S et al., found that surgical masks and unventilated KN95 respirators reduced the emission rate of outward particles by an average of 90% and 74% during talking and coughing, respectively [25]. Suspected or proven COVID-19 pneumonia in whom MRI is required should wear a surgical facemask [26]. The current study shows a susceptibility artefact on the image with one of the surgical face masks which was scanned with a nasal bridge metal strip. Similarly, other studies has shown commercially available masks contain ferromagnetic components and are thus regarded as "MRI unsafe" [16,18].

The current study also shows an artefact-free image with a surgical face mask with a nasal bridge plastic strip. As suggested by the American College of Radiology, MRI technologists need to be aware of MR unsafe issues. They are advised to test any respirator used locally with a strong >1,000 gauss hand-held metal detector before MRI scan [16]. Therefore, a surgical mask is a safe alternative for MR staff than the use of respirators in an MRI environment. The WHO recommendation has been adopted locally [27]. Although several metals are believed to be MR safe, they can significantly hide information during imaging for several reasons. This was in contrast to X-ray images in which radiopaque metal looks bright. If there is no MRI signal from the metal, the metal is dark on MR images [28]. These field variations depend on the shape, size and type of metal and orientation in the magnetic field [24]. One case study, described metallic artefacts in the frontal region induced by the metal strip in the face mask covering the nasal bridge region [29]. The metal strip in masks can cause an inhomogeneous static magnetic field, large variation in the precession frequency across the object. The predominant issues arising in imaging are signal loss due to dephasing, failure of fat suppression, and displacement artefacts [24].

The Dahlhausen surgical mask's metal nose-piece made of aluminium caused minimal artefact in gradient echo pulse sequences [21]. Therefore, removal of the nose-piece or facemask may not be necessary before entering the MRI scanner. Indeed, removing the nose-piece would reduce the seal at the nose bridge and risk patient exposure to COVID-19. While visiting outpatient imaging department, many patients will opt to wear face coverings during the COVID-19 pandemic situation. These masks tend to create artefacts more extensive than that induced by cosmetic or dental implantation [30]. Present study comprehended the need for a local risk-benefit analysis to be carried out by MRI technologists, infection control experts and the clinical team regarding imaging parameters and facemask availability.

The purpose of present study was to familiarise the radiologist/technologist with the appearance of the susceptibility related artefacts generated by the N95 respirator or surgical masks. As can be appreciated in present study, the artefacts have a characteristic appearance on phantom MRI.

Limitation(s)

Since present study was not an in-vivo experiment, the artefacts in this study may be different from those obtained in the human body. Also, this study did not explore the effects of different MR sequences other than routine sequences. In addition, the number of respirators and surgical masks assessed in this study were limited, due to their strained availability during an ongoing pandemic. Future studies can explore different types of respirators available globally and their effects on MRI.

CONCLUSION(S)

Most of the currently available N95 respirators and surgical masks contain metal strips producing susceptibility artefact and tend to heat up during MRI investigations. Hence, it is important for the patients to use MR safe masks which does not compromise image quality. On other hand, when this is not possible to follow, metallic components from the face mask should be removed before the patient's arrival to the MR room. After removing of the metal strip from the mask, paper tape may be applied across the nasal bridge region for adequate transmission control and to maintain the intended function of the mask. MRI examinations with metal containing face masks is strongly discouraged.

REFERENCES

- [1] World Health Organization, Mission China Joint. Report of the WHO-China Joint Mission on Coronavirus Disease 2019 (COVID-19). The WHO-China Joint Mission on Coronavirus Disease 2019. 2020;2019:16-24.
- [2] Sommerstein R, Fux CA, Vuichard-Gysin D, Abbas M, Marschall J, Balmelli C, et al. Risk of SARS-CoV-2 transmission by aerosols, the rational use of masks, and protection of healthcare workers from COVID-19. *Antimicrobial Resistance and Infection Control*. 2020;9(1):01-08.
- [3] Guo ZD, Wang ZY, Zhang SF, Li X, Li L, Li C, et al. Aerosol and surface distribution of severe acute respiratory syndrome coronavirus 2 in hospital wards, Wuhan, China, 2020. *Emerging Infectious Diseases*. 2020;26(7):1586-91.
- [4] Carver PE, Phillips J. Novel Coronavirus (COVID-19): What you need to know. *Workplace Health and Safety*. 2020;68(5):250.
- [5] Mossa-Basha M, Azadi J, Ko J, Klein J, Meltzer C. Special Report of the RSNA COVID-19 Task Force: Crisis Leadership of Major Health System for Radiology Departments during COVID-19. *Radiology*. 2020;(April):01-07.
- [6] Mossa-Basha M, Linnau KF, Sahani DV. Radiology department preparedness in the Coronavirus Disease 2019 (COVID-19) Postshutdown Environment. *Journal of the American College of Radiology*. 2020;17(7):890-93.
- [7] Davenport MS, Bruno MA, Iyer RS, Johnson AN, Herrera R, Nicola GN, et al. ACR Statement on Safe Resumption of Routine Radiology Care During the Coronavirus Disease 2019 (COVID-19) Pandemic. *Journal of the American College of Radiology*. 2020;17(7):839-44.
- [8] Prosch H, Ginsberg M OAE. Radiology Fighting COVID-19 | Maintaining Quality Imaging- Developing Guidelines and Protocols in Times of Crisis. *ESR Connect* (2020).
- [9] Vagal A, Mahoney M, Allen B, Kapur S, Udstuen G, Wang L, et al. Rescheduling nonurgent care in radiology: Implementation during the Coronavirus Disease 2019 (COVID-19) pandemic. *Journal of the American College of Radiology*. 2020;17(7):882-89.
- [10] González-Ortiz S, Medrano S, Maiques JM, Capellades J. Challenges in neuroimaging in COVID-19 pandemic. *Frontiers in Neurology*. 2020;11:01-04.
- [11] Chen RC, Tan TT, Chan LP. Adapting to a new normal? 5 key operational principles for a radiology service facing the COVID-19 pandemic. *European Radiology*. 2020;30(9):4964-67.
- [12] Chen RC, Cheng LTE, Liang Lim JL, Gogna A, Ng DCE, Yi Teo LZ, et al. Touch me not: Safe distancing in radiology during Coronavirus Disease 2019 (COVID-19). *Journal of the American College of Radiology*. 2020;17(6):739-42.
- [13] American College of Radiology. ACR Guidance on COVID-19 and MR Use; (<https://www.acr.org/Clinical-Resources/Radiology-Safety/MR-Safety/COVID-19-and-MR-Use>) [Internet]. ACR. 2020. [cited 2021 Jul 27]. Available from: <https://www.acr.org/Clinical-Resources/Radiology-Safety/MR-Safety/COVID-19-and-MR-Use>.
- [14] Kooraki S, Hosseiny M, Raman SS, Myers L, Gholamrezanezhad A. Coronavirus Disease 2019 (COVID-19) precautions: What the MRI suite should know. *Journal of the American College of Radiology*. 2020;17(7):830.
- [15] Cheng LT, Heilbrun M SD. RSNA Hosts Second Webinar on Radiology Surge and Second Surge Preparedness [Internet]. 2020 [cited 2021 Jul 25]. Available from: <https://www.rsna.org/news/2020/June/COVID-19-Surge-Preparedness-Part-Two>.

- [16] Kanal E, Barkovich AJ, Bell C, Borgstede JP, Bradley WG, Froelich JW, et al. ACR guidance document on MR safe practices. *Journal of Magnetic Resonance Imaging*. 2013;37(3):501-30.
- [17] CDC, NIOSH. Respirator Trusted-Source Information [Internet]. Section 3: Ancillary Respirator Information. 2016 [cited 2021 Jul 30]. Available from: https://www.cdc.gov/niosh/npptl/topics/respirators/disp_part/respsource.html.
- [18] World Health Organization, Mission China Joint, Sommerstein R, Fux CA, Vuichard-Gysin D, Abbas M, et al. Efficacy of masks and face coverings in controlling outward aerosol particle emission from expiratory activities. *Journal of the American College of Radiology*. 2020;17(7):890-93.
- [19] Chockattu SJ, Suryakant DB, Thakur S. Unwanted effects due to interactions between dental materials and magnetic resonance imaging: A review of the literature. *Restorative Dentistry & Endodontics*. 2018;43(4):01-20.
- [20] Gaeta M, Cavallaro M, Vinci SL, Mormina E, Blandino A, Marino MA, et al. Magnetism of materials: theory and practice in magnetic resonance imaging. *Insights into Imaging* [Internet]. 2021;12(1):179. Available from: <https://pubmed.ncbi.nlm.nih.gov/348643382/>.
- [21] Murray OM, Bisset JM, Gilligan PJ, Hannan MM, Murray JG. Respirators and surgical facemasks for COVID-19: Implications for MRI. *Clinical Radiology*. 2020;75(6):405-07.
- [22] Park SM, Kamondetdacha R, Amjad A, Nyenhuis JA. MRI safety: RF-induced heating near straight wires. *IEEE Transactions on Magnetics*. 2005;41(10):4197-99.
- [23] Menachem Gold M. Unmasking Artifacts. *Radiology- RSNA Journals* [Internet]. 2020 [cited 2021 Jul 22]; Available from: https://pubs.rsna.org/page/radiology/blog/2020/5/brief_communications_202318.
- [24] Hargreaves BA, Worters PW, Pauly KB, Pauly JM, Koch KM, Gold GE. Metal-induced artifacts in MRI. *American Journal of Roentgenology*. 2011;197(3):547-55.
- [25] Asadi S, Cappa CD, Barreda S, Wexler AS, Bouvier NM, Ristenpart WD. Efficacy of masks and face coverings in controlling outward aerosol particle emission from expiratory activities. *Scientific Reports*. 2020;10(1):01-13.
- [26] US Food and Drug Administration. N95 Respirators, Surgical Masks, and Face Masks [Internet]. *Medical Devices*. 2020 [cited 2021 Jul 30]. p. 5. Available from: <https://www.fda.gov/medical-devices/personal-protective-equipment-infection-control/n95-respirators-surgical-masks-and-face-masks>.
- [27] WHOc. Mask use in the context of COVID-19. *Who* [Internet]. 2020 [cited 2021 Aug 20]; (December):1-10. Available from: [https://www.who.int/publications/item/advice-on-the-use-of-masks-in-the-community-during-home-care-and-in-healthcare-settings-in-the-context-of-the-novel-coronavirus-\(2019-ncov\)-outbreak](https://www.who.int/publications/item/advice-on-the-use-of-masks-in-the-community-during-home-care-and-in-healthcare-settings-in-the-context-of-the-novel-coronavirus-(2019-ncov)-outbreak).
- [28] Schenck JF. The role of magnetic susceptibility in magnetic resonance imaging: MRI magnetic compatibility of the first and second kinds. *Medical Physics*. 1996;23(6):815-50.
- [29] El-Feky M, O'Donnell C. PPE-associated artifact on MRI brain [Internet]. *Radiopaedia.org*. Radiopaedia.org; 2020 [cited 2021 Jul 23]. Available from: <http://radiopaedia.org/cases/ppe-associated-artifact-on-mri-brain>.
- [30] Wang ZJ, Park YJ, Morriss MC, Seo Y, Nguyen T, Hallac RR, et al. Correcting B0 field distortions in MRI caused by stainless steel orthodontic appliances at 1.5 T using permanent magnets- A head phantom study. *Scientific Reports*. 2018;8(1):01-09.

PARTICULARS OF CONTRIBUTORS:

1. Assistant Professor, Department of Radiodiagnosis, KS Hegde Medical Academy, NITTE Deemed to be University, Mangalore, Karnataka, India.
2. Assistant Professor, Department of Radiodiagnosis, KS Hegde Medical Academy, NITTE Deemed to be University, Mangalore, Karnataka, India.
3. Professor, Department of Radiodiagnosis, KS Hegde Medical Academy, NITTE Deemed to be University, Mangalore, Karnataka, India.
4. Assistant Professor, Department of Radiodiagnosis, KS Hegde Medical Academy, NITTE Deemed to be University, Mangalore, Karnataka, India.

NAME, ADDRESS, E-MAIL ID OF THE CORRESPONDING AUTHOR:

Mr. MM Jaseemudheen,
Assistant Professor, Department of Radiodiagnosis, KS Hegde Medical Academy,
NITTE Deemed to be University, Mangalore, Karnataka, India.
E-mail: jaseemudheen12@gmail.com

PLAGIARISM CHECKING METHODS: [\[Jain H et al.\]](#)

- Plagiarism X-checker: Sep 17, 2021
- Manual Googling: Jan 01, 2022
- iThenticate Software: Jan 06, 2022 (22%)

ETYMOLOGY: Author Origin**AUTHOR DECLARATION:**

- Financial or Other Competing Interests: None
- Was Ethics Committee Approval obtained for this study? Yes
- Was informed consent obtained from the subjects involved in the study? NA
- For any images presented appropriate consent has been obtained from the subjects. NA

Date of Submission: **Sep 16, 2021**
Date of Peer Review: **Dec 16, 2021**
Date of Acceptance: **Jan 06, 2022**
Date of Publishing: **Mar 01, 2022**