

Bilateral Xanthogranulomatous Oophoritis Mimicking Malignancy- A Rare Case Report

HARDIK KABRA¹, PRAJNA DAS², DEVIKA CHAUHAN³, SAROJINI RAMAN⁴, URMILA SENAPATI⁵



ABSTRACT

Xanthogranulomatous Oophoritis is an uncommon form of chronic inflammation of genitourinary system. The exact aetiology of this entity is unknown, but it shares similar histopathological findings to those occurring in various other organs, including the gallbladder and kidney. It is often mistaken for ovarian malignancy clinically and radiologically. A vigilant histopathological evaluation is important to diagnose the disease. The current case is of 38-year-old, premenopausal female who presented with fever and lower abdominal pain. The case was suspected as bilateral malignant adnexal mass by imaging and tumor marker studies. Final diagnosis of bilateral xanthogranulomatous oophoritis was established after histopathological examination.

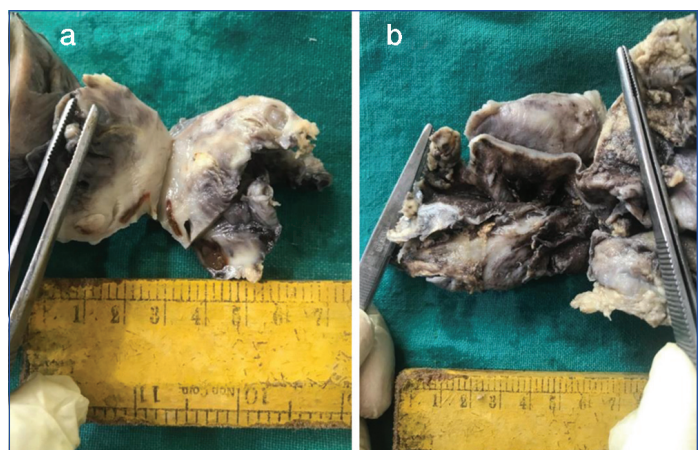
Keywords: Adnexal mass, Genitourinary system, Histopathology, Radiology

CASE REPORT

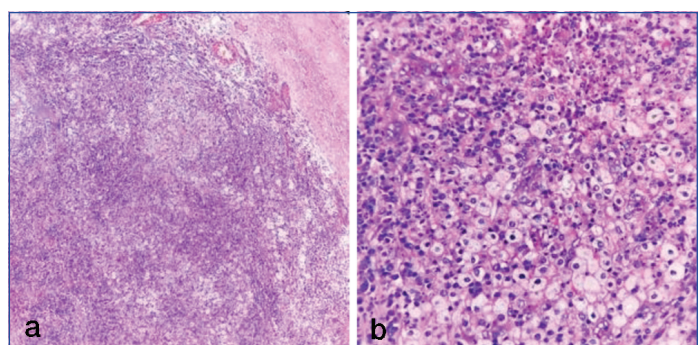
A 38-year-old married, premenopausal female came to Outpatient Department of Gynaecology with history of intermittent fever and lower abdominal pain since 15 days. Her menstrual history was normal with regular cycles. On examination, abdomen was tender in both side iliac fosse and was mildly distended. Routine investigations included, haemoglobin was 10 gm/dL, total leukocyte count was 9,500/cumm and erythrocyte sedimentation rate was 45 mm in first hour. Urine microscopic examination revealed 12-15 pus cells/hpf (high power field). Ultrasound of lower abdomen and pelvis showed bilateral thick walled ovarian cysts, left side measuring 5x5 cm and right side measuring 11x6 cm. Cancer Antigen-125 (CA-125) was 38.70 U/mL (normal range is 0-35 U/mL). Thinking the possibility of neoplastic pathology, total abdominal hysterectomy with bilateral salpingo-oophorectomy was done and the specimen was received in Department of Pathology for histopathological evaluation.

On gross examination, by cutting open the uterus, a Copper Intrauterine device was present in the endometrial cavity. Uterus cervix measured 8.5x6x3.5 cm and endomyometrium measured 0.2x1.7 cm. Bilateral fallopian tubes measured 2.5 cm long each. Left and right sided ovarian cysts measured 4.5x4.3x1.5 cm and 10.5x5x3.5 cm respectively. On cut section of both the cysts, dirty greyish brown fluid came out. There were solid and cystic areas in both the ovarian cysts [Table/Fig-1a,b]. Wall thickness of the cysts varied from 0.2 to 1.5 cm. Solid areas appeared greyish yellow with irregular surfaces. Cut section of these solid areas was firm to soft with focal patchy yellowish areas.

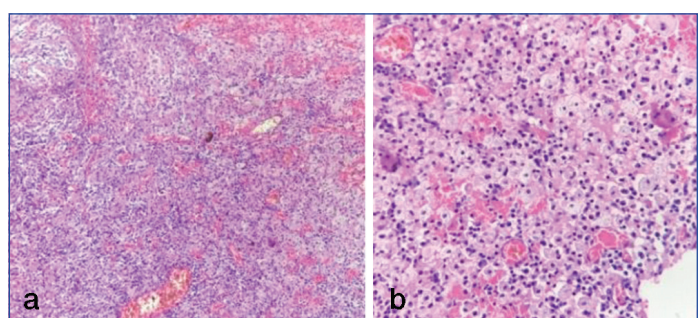
Microscopic examination revealed uterus, cervix and both side fallopian tubes were normal in morphology. Bilateral ovarian cysts showed normal ovarian stroma, haemorrhagic cysts, and follicular cysts along with sheets of foamy macrophages, mixed inflammatory cells comprising of mostly lymphocytes, plasma cells, few neutrophils and occasional multinucleated giant cells [Table/Fig-2a,b, 3a,b]. With this histopathological findings to rule out possibilities of fungal infection and tuberculosis, Periodic acid Schiff (PAS) stain and Zeihl Nelson stain for acid fast bacilli were done. Both the stains were negative. So, final histopathological diagnosis of bilateral xanthogranulomatous oophoritis was given. The postoperative period of the patient was uneventful. The patient was cured after proper antibiotics, analgesics and routine postoperative management.



[Table/Fig-1]: a) Cut-section of left ovary showing greyish yellow solid areas; b) Cut-section of right ovary showing thickened cystic wall with greyish yellow solid areas.



[Table/Fig-2]: Left ovary- Sheets of foamy histiocytes, lymphocytes and few neutrophils a) (H&E, 100X); b) (H&E, 400X).



[Table/Fig-3]: Right ovary- sheets of foamy histiocytes, lymphocytes and few neutrophils a) (H&E 100X); b) (H&E, 400X).

DISCUSSION

Xanthogranulomatous inflammation is an unusual type of chronic inflammation that leads to destruction of the involved organs by inflammatory cells comprising of abundant lipid laden macrophages, lymphocytes, plasma cells and occasional neutrophils [1]. It has been commonly seen in kidney, gallbladder, urinary bladder, bones, stomach, testis and epididymis [2]. It is quite rare in female genital tract with cases usually limited to endometrium. Only few cases of involvement of female genital tract have been reported in India [3]. Reported cases with involvement of ovaries are very few [1]. Searching extensively past literature, only few reported cases of xanthogranulomatous oophoritis with fallopian tube involvement have been reported in the literature. Report of six cases in different age groups was found which were misdiagnosed clinico-radiologically as malignant ovarian neoplasm [4]. First case of xanthogranulomatous inflammation of serosa of uterus, left fallopian tube and ovary was reported as inflammatory pseudotumour of the pelvis in 1976 by Kunakemakorn P et al., [5]. Involvement of adjacent structures in pelvis creates diagnostic difficulties for the clinicians. Moreover, imaging studies shows thickened cystic walls with solid areas in the ovaries raises suspicion of neoplastic pathology.

The exact aetiology of xanthogranulomatous oophoritis is not clear yet. Many theories have been suggested like association with leiomyoma, infection, endometriosis, use of Intrauterine Contraceptive Device (IUCD), inefficient or inappropriate drugs and abnormalities of lipid metabolism etc., [6]. Infection being the most accepted theory as there is clinical evidence of infection and growth of bacteria like *Escherichia coli*, *Bacteroides fragilis*, *Proteus vulgaris* and *Salmonella typhi* in the affected tissue by culture and sensitivity study [3]. Xanthogranulomatous oophoritis was described as a complication of typhoid by Singh UR et al., [7]. It is hypothesised that colonisation of the IUCD in the endometrial cavity leads to bacterial shedding in the lumen of fallopian tube [8]. During the time of ovulation the ovarian surface is exposed to bacteria from the tubes, the corpus luteum becomes infected and cause ovarian abscess [8].

It commonly affects 2-84 years of age with sign and symptoms of lower abdominal or suprapubic pain, fever, menorrhagia, adnexal tenderness and a pelvic mass radiologically [9]. Its presentation as a mass lesion in pelvic cavity and infiltration of surrounding tissue can mimic a neoplastic lesion clinically and radiologically. It usually poses diagnostic and therapeutic challenges for the clinician.

On gross examination the affected ovary shows well circumscribed, solid, yellowish, lobulated mass along with cystic change. Microscopically, there is large infiltration by lipid laden macrophages known as xanthoma cells and inflammatory cells comprising of lymphocytes, plasma cells along with few neutrophils [3,6,8,10]. Most recommended treatment for xanthogranulomatous oophoritis is oophorectomy but as it mimics malignancy, extensive surgery is often performed [2-5,7-11].

CONCLUSION(S)

Xanthogranulomatous oophoritis is a rare chronic inflammatory condition of the female reproductive tract whose clinical manifestations, imaging modalities and gross features can mimic ovarian malignancy. Thus, a proper preoperative diagnosis of this entity is essential for prevention of needless radical surgery and unwarranted psychological burden to patient.

REFERENCES

- [1] Gami N, Mundhra R, Guleria K, Arora VK, Garg S. Recurrent pyometra and xanthogranulomatous salpingitis: A rare pathologic association in a postmenopausal lady. *J Mid-life Health*. 2014;5:156-58.
- [2] Gray Y, Libbey NP. Xanthogranulomatous Salpingitis and Oophoritis. *Arch Pathol Lab Med*. 2001;125(2):260-63.
- [3] Shukla S, Pujani M, Singh SK, Pujani M. Xanthogranulomatous oophoritis associated with primary infertility and endometriosis. *Indian J Pathol Microbiol*. 2010;53:197-98.
- [4] Farooq S, Abbas F, Abbas R, Beigh A, Reshi R, Khuroo M. Xanthogranulomatous salpingo-oophoritis mimicking an ovarian malignancy: Clinical dilemma. *Int J Reprod Contracept Obstet Gynecol*. 2020;9(5):1934-37.
- [5] Kunakemakorn P, Ontai G, Balin H. Pelvic inflammatory pseudotumor: A case report. *Am J Obstet Gynecol*. 1976;126(2):286-87.
- [6] Sheng ZX, Yan DH, Lei ZL, Desouki MM, Zhao C. Xanthogranulomatous inflammation of the female genital tract: Report of three cases. *J Cancer*. 2012;3(1):100-06.
- [7] Singh UR, Revathi G, Gita R. Xanthogranulomatous Oophoritis: An unusual complication of typhoid. *J Obstet Gynaecol*. 1995;21(5):433-36.
- [8] Kalloli M, Bafna UD, Mukherjee G, Gurubasavangouda DK, Rathod PS. A rare xanthogranulomatous oophoritis presenting as ovarian cancer. *Ovarian Cancer Online J Health Allied Scs*. 2012;11(2):01-02.
- [9] Patel KA, Chothani KP, Patel B, Lanjewar DN. Xanthogranulomatous salpingo-oophoritis: A case report and review of literature. *IJRCOG*. 2020;9(10):4316-19.
- [10] Raj JA, Jagadeesha M, Naveen S, Ramachandra U. Xanthogranulomatous oophoritis: Pathologic findings with clinical correlation. *J Indian Med Assoc*. 2012;110(8):653-54.
- [11] Chechia A, Bahri N, Felah R, Khairredine A, Sakouhi M, Zakhama A. Tubo-ovarian xanthogranulomatous inflammation. Report of a case. *Tunis Med*. 1999;77(11):593-96.

PARTICULARS OF CONTRIBUTORS:

1. Postgraduate, Department of Pathology, Kalinga Institute of Medical Sciences, Bhubaneswar, Odisha, India.
2. Associate Professor, Department of Pathology, Kalinga Institute of Medical Sciences, Bhubaneswar, Odisha, India.
3. Postgraduate, Department of Pathology, Kalinga Institute of Medical Sciences, Bhubaneswar, Odisha, India.
4. Associate Professor, Department of Pathology, Kalinga Institute of Medical Sciences, Bhubaneswar, Odisha, India.
5. Professor and Head, Department of Pathology, Kalinga Institute of Medical Sciences, Bhubaneswar, Odisha, India.

NAME, ADDRESS, E-MAIL ID OF THE CORRESPONDING AUTHOR:

Prajna Das,
Plot No-784/786, Lane-3, Jaydev Vihar, Unit-16, Bhubaneswar-751013, Odisha, India.
E-mail: prajnad68@gmail.com

AUTHOR DECLARATION:

- Financial or Other Competing Interests: None
- Was informed consent obtained from the subjects involved in the study? Yes
- For any images presented appropriate consent has been obtained from the subjects. Yes

PLAGIARISM CHECKING METHODS: [Jain H et al.]

- Plagiarism X-checker: Aug 20, 2021
- Manual Googling: Sep 07, 2021
- iThenticate Software: Jan 11, 2022 (17%)

ETYMOLOGY: Author Origin

Date of Submission: **Aug 19, 2021**
Date of Peer Review: **Nov 27, 2021**
Date of Acceptance: **Jan 14, 2022**
Date of Publishing: **Apr 01, 2022**