

Acute Necrotising Pancreatitis in a Patient with Situs Inversus Totalis- A Rare Case Report

ROHITH MUDDASETTY¹, KOLANDASAMY CHINNUSAMY², PRABHAKARAN RAJU³, SUGUMAR CHIDAMBARANATHAN⁴, NAGANATHBABU OBLA LAKSHMANAMOORTHY⁵



ABSTRACT

Situs inversus totalis is a rare congenital anomaly occurring in one per 4000-20000 live births. It can present in early life due to gut rotation abnormality, however majority of them are asymptomatic and identified later in life when they undergo imaging for other reasons. Although acute pancreatitis is a common disease in young adults, presence of situs inversus alters the approach for necrosectomy when it is necessary. Here, author reports a 29-year-old male patient who had acute necrotising pancreatitis and incidentally found to have situs inversus totalis. Since the patient required drainage of necrotic collection there was a change in approach to right flank region rather than the routine left flank. This case was reported to emphasise on identification of situs anomalies and need to alter surgical approach.

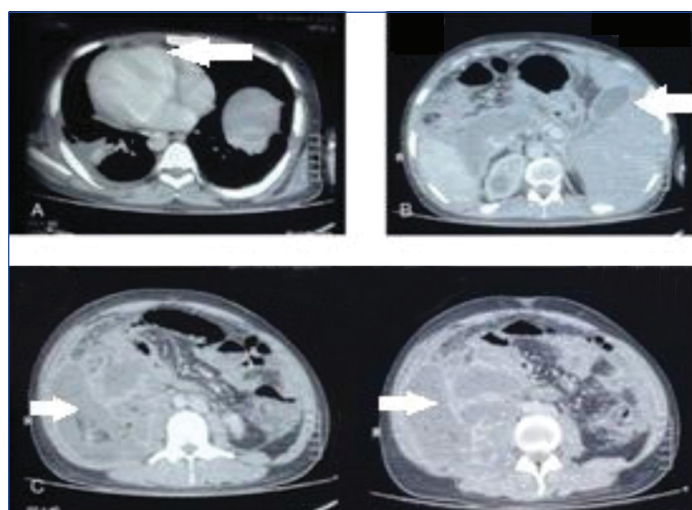
Keywords: Congenital anomalies, Intestinal rotation anomalies, Minimal invasive necrosectomy, Necrotic fluid collection, Situs solitus

CASE REPORT

A 29-year-old male, presented to the Institute of Surgical Gastroenterology with sudden onset of upper abdomen pain following binge alcohol drinking for two weeks. The patient had episodes of fever with chills in past. On examination, he was febrile, pulse rate of 130/min, respiratory rate of 28/min, mildly dehydrated. Abdomen examination revealed tenderness and guarding in the epigastric, right hypochondriac and lumbar regions.

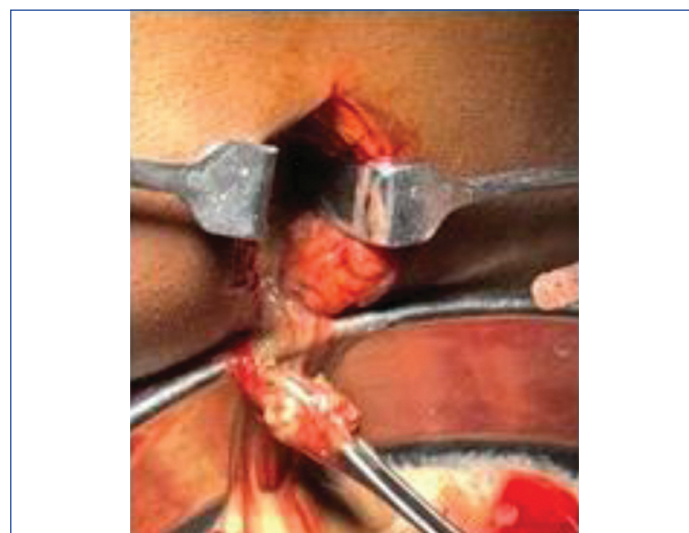
Blood investigations revealed leucocytosis of 22000/cumm, serum amylase of 560 U/L and serum lipase of 1200 U/L. Renal and liver function tests were within normal limits. Ultrasound abdomen suggested altered placement of liver and spleen with collection in right paracolic region.

Contrast Enhanced Computed Tomography (CECT) of abdomen and chest was done which confirmed findings of situs inversus totalis. In addition to that bilateral pleural effusion, well-defined heterodense collection suggestive of necrotic collection in the body and tail of pancreas extending along the right paracolic gutter upto right iliac fossa was also identified [Table/Fig-1].



[Table/Fig-1]: Upper images showing placement of heart and liver on opposite sides as marked by arrows. Lower images showing collection along the right paracolic gutter (marked by arrows).

In view of Systemic Inflammatory Response Syndrome (SIRS) and presence of both solid and liquid component in necrotic collection, patient was planned for retroperitoneal drainage of necrotic collection. Under anaesthesia, a 5 cm right lumbar incision to reach necrotic collection was made [Table/Fig-2]. Around 500 mL of necrotic collection along with solid necrotic tissue in the retro peritoneal space was let out. Thorough saline wash given and two drains were placed.



[Table/Fig-2]: Intraoperative picture showing drainage of necrotic fluid.

Necrotic fluid culture showed growth of *Escherichia coli* sensitive to amikacin. Daily saline wash was given through the drain tubes. Gradually, the patient's inflammatory markers came down to normal. Meanwhile the nutrition was maintained with high protein oral feeds. After confirming no drain output on postoperative day 18, drains were removed sequentially. Patient discharged on postoperative day 24. On one month follow-up, patient was asymptomatic and ultrasound examination showed no intraabdominal collection.

DISCUSSION

Situs anomalies are rare congenital anomaly involving the arrangement of various organs. When all of the organs are in their right positions, it is called situs solitus. Situs inversus is a rare congenital anomaly with left

right transposition of organs. In other words, it is the mirror image of situs solitus [1]. True incidence is not known however; approximately one per 4000 to 20000 live births have been reported [2]. Prevalence of this abnormality is seen in 0.01% of the population [1]. About 20% of them are associated with Immotile Cilia or Kartagener Syndrome [3]. Identification of these anomalies is very important prior to any surgery. Diagnosis of situs anomalies is based on position of stomach, liver, gall bladder, spleen, Inferior Vena Cava (IVC) and aorta, cardiac apex and lungs [1]. Imaging modalities in form of chest X-ray, ultrasound abdomen, Echocardiography and Computed Tomography play an important role in diagnosis. Presence of these anomalies makes surgeries confusing and mandates change in surgical approach.

Acute pancreatitis is one of the common problems encountered in Emergency Department. Early diagnosis can prevent major morbidity and mortality. About 75-80% of patients have mild disease [4]. Identifying the 20-25% of patients who develop severe disease and treating them is challenging. Various scoring and classification systems have been described for this purpose like Ransons scoring, Glasgow Scoring, Bedside Index for Severity in Acute Pancreatitis (BISAP) score [5,6,7]. Modified Atlanta classification is now used worldwide which classifies acute pancreatitis as mild, moderately severe and severe based on presence or absence of local or systemic complications and organ failure [8]. Organ failure in acute pancreatitis was associated with mortality of 30% and infected pancreatic necrosis had mortality of 32%, when organ failure and infected pancreatic necrosis together increases mortality by two folds [9]. Step up approach with minimally invasive procedure is preferred line of management [10,11]. However, availability of expertise and patient general condition should be considered while deciding on treatment. In the present case, imaging studies showed both solid and liquid components in the collection hence percutaneous drainage was not attempted. However, CT image showing situs inversus totalis made us plan retroperitoneal access through right flank in this patient while left flank is routinely used.

Kavuturu S et al., from United States of America described a patient of acute pancreatitis with situs inversus/polysplenia found on radiological study. This patient was further evaluated for presence of anatomical anomalies as a cause of pancreatitis, however, they could not find any surgically correctable causes and concluded that ethanol and gall stones can be cause of pancreatitis even in these individuals [12].

Alkhilawy O et al., from Saudi Arabia described performing laparoscopic cholecystectomy in a patient with Situs inversus totalis presenting with pain abdomen in left hypochondrium and epigastric region. Radiological study confirmed the diagnosis and helped them to place trocars accordingly. They have concluded that identification of situs anomaly and altering the approach is necessary and sufficient to perform safe surgery in these patients [13].

Di Buono G et al., from Italy described a case of acute appendicitis in a patient with situs inversus totalis. Here authors confirmed the diagnosis on diagnostic laparoscopy followed by appendectomy with placement of trocars according to the position of appendix.

Authors concluded that recognising anatomical anomalies is of prime importance to avoid misdiagnosis [14].

The combination of ultrasonography and computed tomography study is essential to diagnose situs anomalies with varied presentation of common diseases. Identification of these anomalies is necessary to tailor the surgical approach.

CONCLUSION(S)

Situs inversus totalis is a rare congenital anomaly. They commonly present with gut rotation abnormalities in childhood. They may remain asymptomatic for long periods of time. Acute pancreatitis is a common problem encountered in young adults who often indulge in alcohol. Treatment of necrotic complications in pancreatitis is a challenging task due to associated morbidity and mortality. Identifying situs anomalies in a rare patient before any intervention is crucial.

Acknowledgement

Authors would like to acknowledge the help of all my colleagues of our institute in publication of this article.

REFERENCES

- [1] Applegate KE, Goske MJ, Pierce G, Murphy D. Situs Revisited: Imaging of the Heterotaxy Syndrome. *RadioGraphics*. 1999;19(4):837-52.
- [2] Ruben GD, Templeton JM, Ziegler MM. Situs inversus: The complex inducing neonatal intestinal obstruction. *J Pediatr Surg*. 1983;18(6):751-56.
- [3] Imbrie JD. Kartagener's syndrome: A genetic defect affecting the function of cilia. *Am J Otolaryngol*. 1981;2(3):215-22.
- [4] NICE. Pancreatitis: Diagnosis and Management Draft Scope for Consultation. National Institute for Clinical Excellence; London, UK: 2016. [Internet]. [cited 2021 Jul 3]. Available from: <https://www.nice.org.uk/guidance/ng104/documents/draft-scope>.
- [5] Ranson JH, Rifkind KM, Roses DF, Fink SD, Eng K, Localio SA. Objective early identification of severe acute pancreatitis. *Am J Gastroenterol*. 1974;61(6):443-51.
- [6] Blamey SL, Imrie CW, O'Neill J, Gilmour WH, Carter DC. Prognostic factors in acute pancreatitis. *Gut*. 1984;25(12):1340-46.
- [7] Wu BU, Johannes RS, Sun X, Tabak Y, Conwell DL, Banks PA. The early prediction of mortality in acute pancreatitis: A large population-based study. *Gut*. 2008;57(12):1698-703.
- [8] Banks PA, Bollen TL, Dervenis C, Gooszen HG, Johnson CD, Sarr MG, et al. Classification of acute pancreatitis-2012: Revision of the Atlanta classification and definitions by international consensus. *Gut*. 2013;62(1):102-11.
- [9] Petrov MS, Shanbhag S, Chakraborty M, Phillips ARJ, Windsor JA. Organ failure and infection of pancreatic necrosis as determinants of mortality in patients with acute pancreatitis. *Gastroenterology*. 2010;139(3):813-20.
- [10] Besselink MGH, van Santvoort HC, Nieuwenhuis VB, Boemeester MA, Bollen TL, Buskens E, et al. Minimally invasive "step-up approach" versus maximal necrosectomy in patients with acute necrotising pancreatitis (PANTER trial): Design and rationale of a randomised controlled multicenter trial [ISRCTN13975868]. *BMC Surg*. 2006;6:6.
- [11] Working Group IAP/APA Acute Pancreatitis Guidelines. IAP/APA evidence-based guidelines for the management of acute pancreatitis. *Pancreatol Off J Int Assoc Pancreatol IAP AI*. 2013;13(4 Suppl 2):e1-15.
- [12] Kavuturu S, Roper W, Stawicki SP. Acute pancreatitis in a patient with Situs inversus/polysplenia syndrome: A case report and review of literature. *International Journal of Academic Medicine*. 2017;3(3):154.
- [13] Alkhilawy O, AlMuhsin AM, Zakarneh E, Taha MY. Laparoscopic cholecystectomy in situs inversus totalis: Case report with review of techniques. *International Journal of Surgery Case Reports*. 2019;59:208-12.
- [14] Di Buono G, Maienza E, Buscemi S, Randisi B, Romano G, Agrusa A. Acute appendicitis in a patient with situs viscerum inversus totalis: Role of laparoscopic approach. A case report and brief literature review. *International Journal of Surgery Case Reports*. 2020;77:S29-33.

PARTICULARS OF CONTRIBUTORS:

1. Postgraduate, Institute of Surgical Gastroenterology, Madras Medical College, Chennai, Tamil Nadu, India.
2. Assistant Professor, Institute of Surgical Gastroenterology, Madras Medical College, Chennai, Tamil Nadu, India.
3. Associate Professor, Institute of Surgical Gastroenterology, Madras Medical College, Chennai, Tamil Nadu, India.
4. Professor, Institute of Surgical Gastroenterology, Madras Medical College, Chennai, Tamil Nadu, India.
5. Director and Professor, Institute of Surgical Gastroenterology, Madras Medical College, Chennai, Tamil Nadu, India.

NAME, ADDRESS, E-MAIL ID OF THE CORRESPONDING AUTHOR:

Naganathbabu Obla Lakshmanamoorthy,
Director and Professor, Institute of Surgical Gastroenterology, Madras Medical College,
Chennai, Tamil Nadu, India.
E-mail: naganathbabu@gmail.com

PLAGIARISM CHECKING METHODS: [Jain H et al.]

- Plagiarism X-checker: Jul 26, 2021
- Manual Googling: Nov 25, 2021
- iThenticate Software: Dec 31, 2021 (6%)

ETYMOLOGY: Author Origin

AUTHOR DECLARATION:

- Financial or Other Competing Interests: None
- Was informed consent obtained from the subjects involved in the study? Yes
- For any images presented appropriate consent has been obtained from the subjects. Yes

Date of Submission: **Jul 23, 2021**
Date of Peer Review: **Nov 27, 2021**
Date of Acceptance: **Jan 01, 2022**
Date of Publishing: **Apr 01, 2022**