

Radical Surgery for Successful Management of Axillary Hidradenitis Suppurativa Complicated by Mycobacterial Infections

SRINJOY SAHA



ABSTRACT

Hidradenitis Suppurativa (HS) causes chronic inflammation around the hair follicles, leading to localised immunosuppression. Sometimes, it causes superadded Non tuberculous mycobacterial infections that require radical surgeries. After an extensive literature search, no Indian case report on this rare topic could be found, and this case report aims to fill up the void. A 28-year-old female presented with recurrent ulcers over her left axilla, which were refractory to medical treatments and surgeries for the last five years. Earlier, she had received a six month course of antitubercular drugs after Acid-Fast Bacilli (AFB) were found on pus examination. When the ulcers recurred afterward, she was empirically diagnosed as Non tuberculous mycobacterial infection in Thailand and treated with appropriate antibiotics for three months. However, multiple ulcers in new areas recurred over her axilla about a month after her treatment schedule was completed. To achieve complete surgical cure, radical excision of all the tracts, fistulae, and sinuses over her axilla was performed under ultrasound guidance. Wide excision resulted in a significant axillary defect that was reconstructed with large advancement flaps aided by progressive tension sutures. Postoperatively, a seven year follow-up period of the patient was disease-free with the patient taking all necessary precautions. After seven years, the affected axilla appeared near-normal with some areas of stretched scars that did not bother the patient. To conclude, HS with Non tuberculous mycobacteria is rare, and a proper antimicrobial therapy with early en bloc excision under ultrasound guidance produced a complete cure.

Keywords: Cutaneous tuberculosis, Hidradenitis management, Non tuberculous mycobacteria, Radical excision

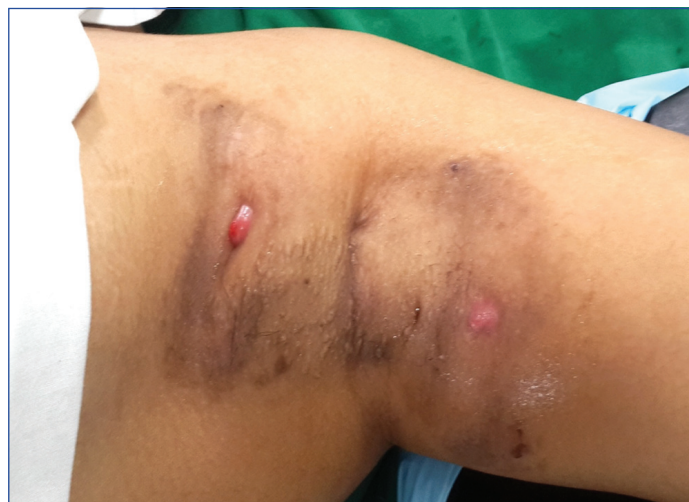CASE REPORT

A 28-year-old female living in Thailand presented to the plastic surgery clinic with painless recurrent ulcers over her left axilla for the last one month. Previously, for the past five years, several small abscesses, often resulting in ulcers, had waxed and waned over her left axilla. After every episode of successful medical treatment, they formed indurated plaques and puckered scars while healing. Surgeries were performed twice earlier at different hospitals in India and Thailand, but they failed to cure the problem. Medical history elicited excessive body sweating, polycystic ovarian disease, and ankylosing spondylitis, for which she was receiving medicines and other appropriate treatments.

While examining the pus from her axillary swelling at another hospital two years earlier, non granulomatous Acid Fast Bacilli (AFB) were found on Ziehl-Nielsen staining. Chest skiagram and Mantoux test were normal. Based on these findings, she was administered oral antitubercular drugs for six months. But, within a few months of completing therapy, she had recurrent abscess and ulcers in her axilla. Then, her treating physician in the tropics empirically diagnosed non tuberculous mycobacterial infection and administered clarithromycin and rifampicin for three months. The ulcers responded to these antibiotics and healed within weeks, while forming noticeable scars. However, about a month after ceasing treatment, two ulcers recurred in new areas of her left axilla.

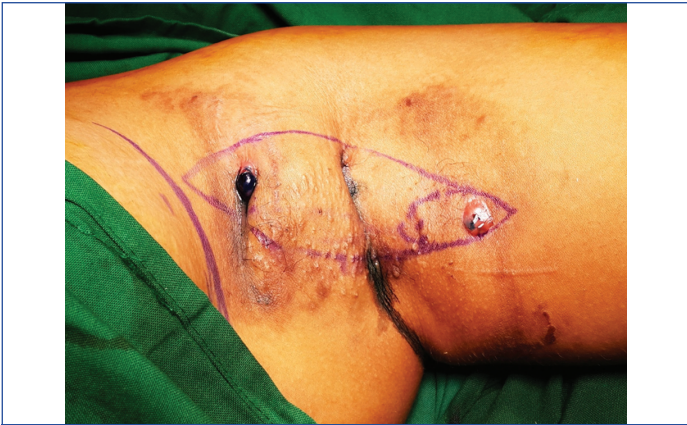Physical examination revealed two ulcers at opposite ends of her left axilla- one near her arm, and the other near her chest. Fleishy pinkish everted tissues sized 1x0.5 cm surrounded a tiny ulcer at both places, with subcutaneous indurations extending for variable lengths towards the centre of the axilla. Hyperpigmented scarred plaques punctuated by multiple puckered atrophic scars were visible [Table/Fig-1]. Other areas of the body, including her opposite axilla and inguinal regions, were disease-free. Her body mass index was normal. Wound swabs from the ulcers were culture negative. High-resolution ultrasonography revealed multiple superficial tracts, sinuses and fistulas without any deeper spread.

With a provisional diagnosis of recalcitrant HS, she was planned for radical surgical excision and reconstruction.

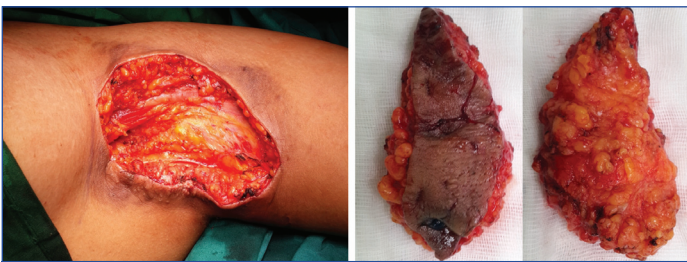


[Table/Fig-1]: Patient presented with two distinct ulcers at two opposing ends of her left axilla.

During the surgery, the extent of fistulae was determined first with methylene blue injection under anaesthesia. It revealed one fistulous tract from the ulcer near the arm to two barely-visible openings over her mid axilla, and one sinus tract extending laterally from the ulcer near her chest [Table/Fig-2]. Thereafter, radical surgical excision of all tracts, sinuses, fistulas and scarred skin/subcutis was performed under intraoperative ultrasound guidance [Table/Fig-3], resulting in a significant axillary defect sized 15x9 cm. It was then reconstructed primarily with large advancement flaps extending to her arm and chest, using progressive tension sutures for closure [Table/Fig-4,5]. Histopathology revealed mixed acute and chronic inflammatory cell infiltrate, congested blood vessels, and foreign-body type giant cells in the subcutaneous tissues, suggesting chronic inflammatory sinus tract characteristic of hidradenitis [Table/Fig-6]. Acid fast bacilli or

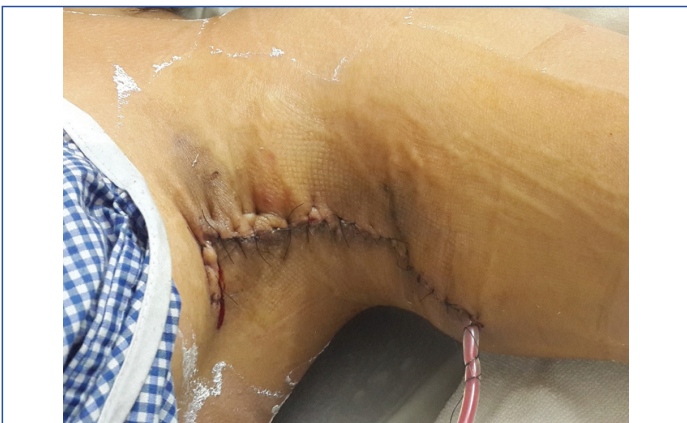

[Table/Fig-2]: Intraoperative methylene blue injection showed a sinus formation from the ulcer near the chest. Ulcer near the arm had fistulous tracts connecting it to tiny openings over mid axilla.

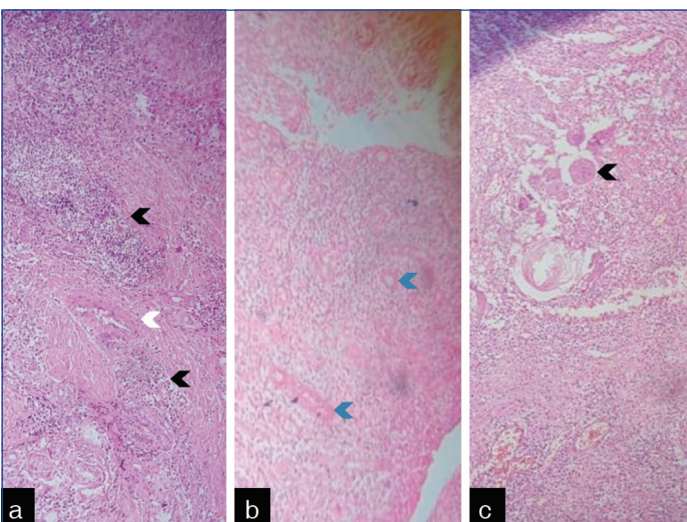


[Table/Fig-3]: Excised bulk of axillary skin and subcutaneous tissues contained all the fistulae, sinuses, tracts and ulcers with sufficient margins.

[Table/Fig-4]: A substantial axillary defect sized 15×9 cm resulted after the radical excisional surgery. (Images from left to right)



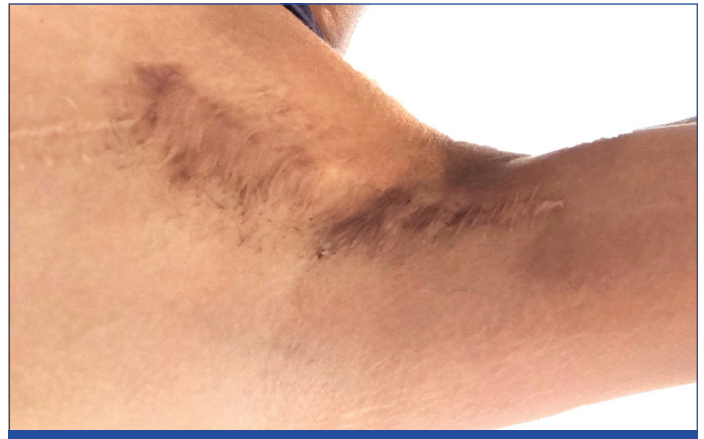[Table/Fig-5]: Large advancement flaps extending into chest and arm, closed with progressive tension sutures, sufficiently covered the wound over a drain.



[Table/Fig-6]: Histopathology established the diagnosis of hidradenitis suppurativa, showing; a) intense neutrophilic infiltration (black arrows) around adnexal structures of the skin (white arrow); b) Excessive vascularisation (blue arrows), and; c) foreign-body like giant cells (black arrow).

granulomas were not observed. Mycobacteria were not found in her excised wound tissues on stain, culture, or reverse hybridisation. Fungi were also absent on stain and culture. On bacterial culture, multidrug resistant *Escherichia coli* (ESBL strain) was found, and treated with appropriate antibiotics.

Postoperative recovery of the patient was uneventful. Her axillary wound healed satisfactorily. The patient underwent weight loss and maintained a healthy diet and lifestyle to prevent hidradenitis afterwards and has enjoyed a seven years disease-free postoperative period to date. Aesthetic appearance of the involved axilla is satisfying, albeit with some slightly-noticeable stretching of the scars. It has not bothered the patient or prevented her from wearing sleeveless garments on social occasions [Table/Fig-7]. The patient reported excellent satisfaction with the overall treatment process.



[Table/Fig-7]: A seven-year-old postoperative healing was disease-free. The wound appeared nearly normal with some areas of stretched scars.

DISCUSSION

Chronic inflammations can cause diagnostic dilemmas and delay proper diagnosis and treatment. Repeated flaring of inflammations produces localised immunosuppression, and may lead to superadded atypical infections and malignancies [1,2]. When they occur, treatment gets prolonged, increasing morbidity. Severe Hidradenitis Suppurativa (HS) is one such recalcitrant chronic inflammation around the hair follicles with dysregulated skin immunity, leading to hyperkeratosis and follicular occlusion [3]. Population-based studies in the United States of America estimate a prevalence of 0.1%, while European studies estimate 1% prevalence [4]. However, data from India is unavailable.

In the axillae, differential diagnoses for chronic inflammatory skin ulcerations include HS, diabetic ulcers, chronic herpes, skin cancers, vasculopathy, yaws, cutaneous tuberculosis, Non tuberculous mycobacteria like Buruli ulcer, ecthyma, phagedenic ulcers amongst others [5]. Cutaneous tuberculosis manifests in 1-2% of tuberculous patients, where painless, brownish, warty, indurated, plaque-like lesions are prone to ulcerations. Classically, epithelioid granulomas are observed around the ulcer edges. *Mycobacterium tuberculosis* can be cultured as well, establishing the diagnosis [6].

Hidradenitis suppurativa complicated by Non tuberculous mycobacterial infection are rarely reported. An author from India had described one such case with *Mycobacterium chelonae* that achieved remission with oral antibiotics, implying that medicines alone are sufficient [7]. However, this may not be true. This patient had recurrent ulcers and symptoms even after nine months of different combinations of oral antimicrobials, finally requiring wide excision and reconstruction for complete cure.

Non tuberculous mycobacteria cause painless recurrent nodules, plaques, and ulcers over the arms and legs. Mycobacterial strains present in the soil and water like *M.chelonae*, *M.avium-complex*, *M.ulcerans*, *M.marinum* and *M.kansasii* result in recalcitrant skin and soft-tissue infections [7]. Of particular interest is *Mycobacterium ulcerans*, which secretes mycolactone to inhibit

local immune response while causing 'Buruli Ulcer' by damaging skin, soft-tissues, and bones. Early diagnosis involves wound biopsy identifying AFB on Ziehl-Nielsen staining, and culture results are unreliable. Combinational antibiotics including clarithromycin, administered for at least 8 weeks, are usually successful [8]. Four weeks of antibiotics are recommended before surgical excision for severe recurrent diseases [9].

Hidradenitis suppurativa commonly affects the axillae, groins, perianal and inframammary regions of women in their second and third decades. Early diagnosis requires high clinical suspicion and may be missed. Generally, symptoms start with discomfort, itching, redness and excessive sweating; and progresses to multiple abscesses, sinuses, fistulas, and fibrotic plaque formation later. Histopathology helps establish the diagnosis. The HS cannot be cured, but controlled with medicines; and surgery is required for definitive treatment [3].

Radical excision with a wide margin of all soft-tissues affected by severe HS is effective for cure [10]. Adequate reconstruction of the defect with surgical flaps or skin grafts provides good results with low recurrence rates [3,10,11]. Widely dissected advancement flaps and closure with progressive tension sutures can avoid the need for major locoregional flaps. Earlier, this patient had consulted different plastic surgeons, who wanted to reconstruct the resulting defect with locoregional parascapular flaps or anterolateral thigh free flaps. However, it appeared that a simpler reconstruction with wide advancement flaps could avoid extensive surgeries and reduce morbidity, while still providing satisfying outcomes.

Non surgical treatments used for treating HS include antibiotics, retinoids, intralesional corticosteroids, hormonal therapy, immunosuppressants, radiotherapy, cryotherapy, laser therapy, and biologic therapy like infliximab [3,11,12]. Subsequent recurrences may be prevented by stopping tobacco usage, weight loss, healthy diet and lifestyle, stress reduction, reducing irritation, avoiding shaving and following regular skincare [12].

Based on this patient's experience, it appears that if Non tuberculous mycobacterial infection is diagnosed with HS, early radical excision after 4 weeks of antibiotic treatment may be a better approach [9]. Otherwise, prolonged antibiotic treatment for Non tuberculous mycobacteria results in increasing toxicity and side-effects without achieving permanent cure. A larger study on the treatment of this rare disease is necessary in future to accept or reject the validity of this approach.

CONCLUSION(S)

Hidradenitis suppurativa with superadded Non tuberculous mycobacterial infection is rare but can occur due to localised immunosuppression. They are prone to recurrent infections and is better excised en bloc under ultrasound guidance. Instead of extensive loco-regional flaps, large advancement flaps with progressive tension sutures may provide adequate closure. A 7-year follow-up of radical surgery and reconstruction are satisfactory.

Acknowledgement

Dr. Arpita Sutradhar, MBBS, MD (Path) for her immense help in documenting the histopathological findings.

REFERENCES

- [1] Kanterman J, Sade-Feldman M, Baniyash M. New insights into chronic inflammation-induced immunosuppression. *Semin Cancer Biol.* 2012;22(4):307-18. Doi: 10.1016/j.semcancer.2012.02.008.
- [2] Maclean GM, Coleman DJ. Three fatal cases of squamous cell carcinoma arising in chronic perineal hidradenitis suppurativa. *Ann R Coll Surg Engl.* 2007;89(7):709-12. Doi: 10.1308/003588407X209392.
- [3] Vinkel C, Thomsen SF. Hidradenitis suppurativa: Causes, features, and current treatments. *J Clin Aesthet Dermatol.* 2018;11(10):17-23.
- [4] Ingram JR. The epidemiology of hidradenitis suppurativa. *Br J Dermatol.* 2020;183(6):990-98. Doi: 10.1111/bjd.19435.
- [5] Haynes D, Hammer P, Malachowski SJ, Kaffenberger B, Yi JS, Vera N, et al. Characterisation and diagnosis of ulcers in inpatient dermatology consultation services: A multi-centre study. *Int Wound J.* 2019;16(6):1440-44. Doi: 10.1111/iwj.13211.
- [6] Franco-Paredes C, Marcos LA, Henao-Martínez AF, Rodríguez-Morales AJ, Villamil-Gomez WE, Gotuzzo E, et al. Cutaneous mycobacterial infections. *Clin Microbiol Rev.* 2018;32(1):e00069-18. Doi: 10.1128/CMR.00069-18.
- [7] Patnaik S, Mohanty I, Panda P, Sahu S, Dash M. Disseminated Mycobacterium chelonae infection: Complicating a case of hidradenitis suppurativa. *Indian Dermatol Online J.* 2013;4(4):336-39. Doi: 10.4103/2229-5178.120672.
- [8] Yotsu RR, Suzuki K, Simmonds RE, Bedimo R, Ablordey A, Yeboah-Manu D, et al. Buruli ulcer: A review of the current knowledge. *Curr Trop Med Rep.* 2018;5(4):247-56. Doi: 10.1007/s40475-018-0166-2.
- [9] Cowan R, Athan E, Friedman ND, Hughes AJ, McDonald A, Callan P, et al. Mycobacterium ulcerans treatment-can antibiotic duration be reduced in selected patients? *PLoS Negl Trop Dis.* 2015;9(2):e0003503. Doi: 10.1371/journal.pntd.0003503.
- [10] Mendes RRDS, Zatz RF, Modolin MLA, Busnardo FF, Gemperli R. Radical resection and local coverage of hidradenitis suppurativa- acne inversa: Analysis of results. *Rev Col Bras Cir.* 2018;45(3):e1719. Doi: 10.1590/0100-6991e-20181719.
- [11] DeFazio MV, Economides JM, King KS, Han KD, Shanmugam VK, Attinger CE, et al. Outcomes after combined radical resection and targeted biologic therapy for the management of recalcitrant hidradenitis suppurativa. *Ann Plast Surg.* 2016;77(2):217-22. Doi: 10.1097/SAP.0000000000000584.
- [12] Kurzen H, Kurzen M. Secondary prevention of hidradenitis suppurativa. *Dermatol Reports.* 2019;11(2):8243. Doi: 10.4081/dr.2019.8243.

PARTICULARS OF CONTRIBUTORS:

1. Distinguished Clinical Tutor, Department of Plastic Surgery, Apollo Multispecialty Hospital, Kolkata, West Bengal, India.

NAME, ADDRESS, E-MAIL ID OF THE CORRESPONDING AUTHOR:

Srinjoy Saha,
Distinguished Clinical Tutor, Department of Plastic Surgery, Apollo Multispecialty Hospital,
Kolkata, West Bengal, India.
E-mail: ss@medi.ac

AUTHOR DECLARATION:

- Financial or Other Competing Interests: None
- Was informed consent obtained from the subjects involved in the study? Yes
- For any images presented appropriate consent has been obtained from the subjects. Yes

PLAGIARISM CHECKING METHODS: [Jain H et al.]

- Plagiarism X-checker: Jan 08, 2022
- Manual Googling: Feb 28, 2022
- iThenticate Software: Mar 05, 2022 (9%)

ETYMOLOGY: Author Origin

Date of Submission: **Jan 06, 2022**
Date of Peer Review: **Feb 03, 2022**
Date of Acceptance: **Mar 01, 2022**
Date of Publishing: **Apr 01, 2022**