

# Predictive Role of Chest Radiograph in COVID-19 Hospitalised Patients: A Retrospective Analysis

JUDAH NIJAS ARUL<sup>1</sup>, MOHAN KUMAR<sup>2</sup>, SWATHY MOORTHY<sup>3</sup>, RAJKUMAR MANI<sup>4</sup>



## ABSTRACT

**Introduction:** The portable Chest Radiograph (CXR) has an indispensable role in large scale screening and diagnosis of Coronavirus Disease-2019 (COVID-19), especially in developing countries with limited resources. It can help in predicting the severity of lung involvement in the patients infected with Severe Acute Respiratory Syndrome Coronavirus-2 (SARS-CoV-2) infection, especially in areas where the Computed Tomography (CT) is unavailable.

**Aim:** To determine the prognostic value of CXR at clinical presentation in assessing the disease severity and its correlation with inflammatory markers in COVID-19 hospitalised patients.

**Materials and Methods:** This was a single-centre retrospective study, conducted at Sri Ramachandra Institute of Higher Education and Research, from October 2020 to December 2020, on hospitalised COVID-19 patients. Clinically, the patients were categorised as mild, moderate and severe, based on their peripheral oxygen saturation- more than or equal to 94%, between 90-93%, and less than or equal to 89%, respectively. Blood samples, drawn at presentation to the hospital tested for various inflammatory markers proven to be predictive of disease severity, were documented for the analysis purpose. The CXRs done at the presentation, were scored based on the number of zones involved and type of abnormality present (ground

glassing, consolidation and septal thickening). The CXRs were scored a minimum '0' to a maximum of '9'. Correlation between the radiograph score and inflammatory markers were further analysed.

**Results:** Among the 456 study patients, 71.9% had mild, 15.1% had moderate and 13% had severe COVID-19 infection. The mean CXR score in each category was 1, 3 and 4, respectively (p-value <0.001). The study groups were grouped as mild and non mild (included the moderate and severe categories). A criterion CXR score of 2 was able to differentiate mild and non mild cases (sensitivity was 78.29%, specificity was 77.98%, positive predictive values was 58.38%, negative predictive values was 90.11%), with an accuracy of 78.1%. The inflammatory markers like Neutrophil Lymphocyte Ratio (NLR), Absolute Lymphocyte Counts (ALC), eosinophil%, D-dimer, Lactate Dehydrogenase (LDH), Erythrocyte Sedimentation Rate (ESR), C-Reactive Protein (CRP), and ferritin showed statistically significant difference between the two groups (p-value <0.001).

**Conclusion:** The CXR can be used as a screening and predictive tool for disease severity in developing countries where access to Computed Tomography (CT) is limited. Given the possibility of subsequent waves of the COVID-19 pandemic and the risk of excessive radiation exposure from CT, CXR may be used as a reliable alternative.

**Keywords:** Coronavirus disease, Disease severity, Portable chest radiograph, Radiograph score

## INTRODUCTION

Chest imaging remains the primary modality that is used in the management of patients with infections causing lung involvement. A consensus statement was issued by the Fleischner Society exploring Computed Tomography (CT) of the chest as a prime imaging modality in the diagnosis, risk stratification and management of the Coronavirus Disease-2019 (COVID-19) patients [1], but many professional organisations in the developing world face issues such as non availability of CT. Also, owing to the rapid spread of infection, tests that are less time consuming and can be done quickly, should be adopted. To handle such situations, the Society of Thoracic Radiology and American College of Radiology have suggested the use of portable Chest Radiograph (CXR) to combat this crisis [2]. The CXR has been shown to have a low sensitivity of 69%, in diagnosing COVID-19 lung involvement [3].

Studies among the severe acute respiratory syndromes observed in 2003 and other pneumonia causing infections, reported a positive correlation between poorer clinical outcomes and two or more zones involvement on CXRs [4,5]. However, pre-existing heart or lung conditions of the individuals and observer expertise influence the CXR interpretation. The CXR characteristics of COVID-19 infection, have been focused in few studies from countries like Italy and China. Peripheral ground glass opacities or consolidation noted in the lower and mid zones were the most

predominant CXR findings observed [3,6]. The CXR in COVID-19 infected patients had variable sensitivity reported, with one study quoting sensitivity as high as 89% [7]. The CXR severity was worse with advancing age, non survivors [8-10], and more likely for intubation and mechanical ventilation [11,12].

CXR is the primary imaging modality adopted for the diagnosis and risk stratification of COVID-19 infection in the UK. The British society of Thoracic Imaging (BSTI) have recommended the use of severity grading in CXR as mild/moderate/severe in suspected COVID-19 infection, though no clear guidance exists on the constitutes of each severity grade [13]. Other CXR grading systems have been used are the Radiographic Assessment of Lung Oedema (RALE) score, where the lungs are split into quadrants, and the involvement and density are scored, the quadrant scores are multiplied and then summed and is a 0-48 score [14], a simplified version of the RALE score, where each lung is given a score of 0-4 proportional to the amount of lung affected has also been tried [3]. Brixia score, is yet another CXR score [9,10], which is scored 0-18, where the left and right upper, middle and lower zones are each given a 0-3 score proportional to the lung involvement.

Toussie D et al., utilised a scoring system based on the number of lung zones involved in CXR. Lung fields on CXR were divided into six zones, three on each lung. A score of 2 or more correlated with need for hospital admission and a score of 3 or more was an independent

predictor of need for mechanical ventilation [15]. The present study was aimed to determine the prognostic value of CXR at clinical presentation in determining the severity of illness and its correlation with inflammatory markers in COVID-19 hospitalised patients.

## MATERIALS AND METHODS

This was a single-centre retrospective study, conducted at Sri Ramachandra Institute of Higher Education and Research, during the period between October 2020 to December 2020. The approval from the Institutional Ethics Committee {IEC-NI/20/AUG/75/56 (COVID-19)} was obtained.

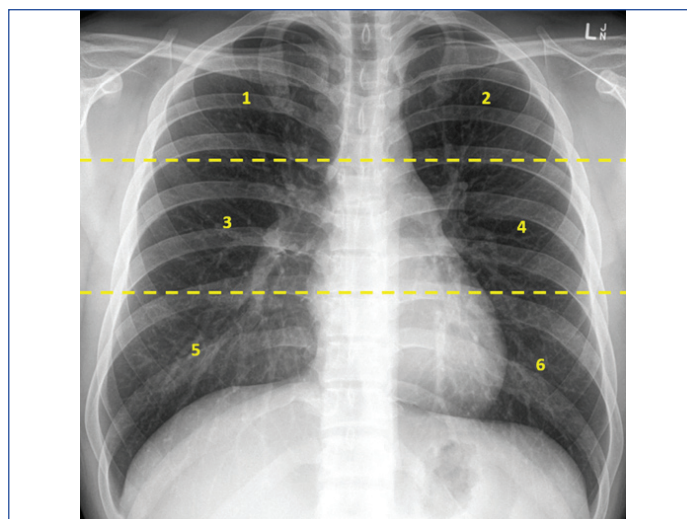
**Inclusion criteria:** Data of 456 adult patients admitted with COVID-19 illness, confirmed by Reverse Transcription-Polymerase Chain Reaction (RT-PCR) of the nasopharyngeal swab, over the age of 18 years were considered in the study.

**Exclusion criteria:** All COVID-19 positive patients, below the age of 18 years were excluded from the study.

### Procedure

The clinical and demographic variables of all the patients were recorded. All the patients had undergone a CXR at the time of admission. The radiographs were analysed prospectively by a single trained physician, blinded to the patient's history, other than the positive history of COVID-19 infection, to minimise observer bias. The radiographs were accessed from the preserved archived soft copies, and scored the involvement of lung abnormalities in the CXR.

To analyse the imaging each lung was divided into three zones; upper, middle and lower, based on the extension from apices to superior hilar markings, from superior to inferior hilar markings and from inferior hilar markings to costophrenic sulcus, respectively [Table/Fig-1]. Each zone was scored based on presence or absence of opacity as 1 or 0 and a total score out of 6 was derived for the six zones in the CXR [15]. Further scoring was done for the pattern of lung involvement- ground glass opacity, consolidation and septal thickening as 0, 1 and 2 respectively (with increasing severity of the opacity). These two scores were added together, to get total scores of minimum 0 to a maximum of 9. The final scores thus derived were correlated with the clinical severity and inflammatory markers like Neutrophil Lymphocyte Ratio (NLR), Absolute Lymphocyte Count (ALC), eosinophil%, D-dimer, Lactate Dehydrogenase (LDH), Erythrocyte Sedimentation Rate (ESR), C-Reactive Protein (CRP), and ferritin documented at the time of presentation to the hospital.



**[Table/Fig-1]:** Zones in a Chest Radiograph (CXR). Each zone was scored based on presence or absence of opacity as 1 or 0 and a total score out of 6 was derived for the six zones in the CXR

## STATISTICAL ANALYSIS

The data was analysed using Statistical Package for the Social Sciences (SPSS) software version 23.0. Continuous variables were expressed as mean and standard deviations. Percentage and frequency analysis was used for categorical variables. One-way Analysis of Variance (ANOVA) with Tukey's post-hoc test were used to determine statistical significance in intergroup analysis. Spearman's rank correlation coefficient was adopted to measure the degree of correlation between the CXR score and each of the variables. All the tests were two tailed and a p-value of <0.05 was considered statistically significant. Receiver Operating Characteristic (ROC) curve analysis was used to evaluate the efficacy of CXR score in determining the outcomes of interest.

## RESULTS

The study included 456 COVID-19 hospitalised patient's data, of which 328 patients were mild, 69 were moderate and 59 were severe. [Table/Fig-2] describes the baseline characteristics of study population and [Table/Fig-3] shows the CXR scoring among the mild, moderate and severe cases. Older age group was associated with moderate and severe infections, while gender did not show any difference with the disease severity. NLR, D-Dimer, Ferritin, CRP, ESR correlated positively with clinical severity while ALC, eosinophil percentage negatively correlated with the disease severity [Table/Fig-4]. Overall,

Variable	Total (N=456)	Clinical severity			p-value
		Mild (n=328)	Moderate (n=69)	Severe (n=59)	
Age (years) (Mean±SD)	52±14	49±14	56±12	61±14	<0.001
<b>Gender</b>					
Male	278	191 (68.7%)	46 (16.5%)	41 (14.8%)	0.151
Female	178	137 (77%)	23 (12.9%)	18 (10.1%)	
<b>Blood test parameters (Mean±SD)</b>					
Hemoglobin (g/dL)	12.7±1.9	12.9±1.9	12.4±1.8	12.3±2.1	0.019
Total leucocyte count (cells/mm <sup>3</sup> )	6803±3159	6283±2178	7430±3422	8961±5578	<0.001
Eosinophil (%)	1.3±2.6	1.6±2.9	0.6±1.1	0.4±0.9	0.001
Platelet count (lakh cells/mm <sup>3</sup> )	2.4±0.8	2.4±0.7	2.3±0.9	2.4±1	0.767
Neutrophil Lymphocyte Ratio (NLR)	4.2±5.9	2.7±2.4	7.2±9	9.1±10	<0.001
Absolute Lymphocyte Count (ALC) (cells/mm <sup>3</sup> )	1602±783	1771±779	1215±660	1115±551	<0.001
Ferritin (ng/mL)	248.9±372.3	179.5±330.6	358.9±352.1	477.4±471.5	<0.001
D-dimer (mcg/mL)	1.3±4.62	0.62±1.28	1.39±1.83	4.89±11.73	<0.001
CRP (mg/dL)	4.1±6.8	2.7±5.7	7.6±7	9±9.1	<0.001
ESR (mm/hr)	23±22	20±19	43±25	29±19	<0.001

**[Table/Fig-2]:** Baseline characteristics of study patients.

p-value <0.05 was considered statistically significant (One-way ANOVA with Tukey's Post-Hoc test); ESR: Erythrocyte sedimentation rate; CRP: C-reactive protein

61.9% of patients affected with mild illness had normal CXR, while 71.2% of moderate cases had 3 zones or lesser involved, and 47.5% of severe cases had more than 3 zones involved. The most frequently involved lobes in the CXR were- right lower lobe (72%), followed by the left lower lobe (55%).

Number of zones involved in chest X-ray	Clinical severity						p-value
	Mild		Moderate		Severe		
	Number (n=328)	%	Number (n=69)	%	Number (n=59)	%	
0	162	49.3	11	15.5	6	10.2	<0.001
1	34	10.5	6	9.2	7	11.9	
2	121	37	16	23	5	8	
3	7	2.1	20	28.5	11	17.9	
4	4	1.1	10	15	18	29.6	
5	0	0	4	6.3	7	14.6	
6	0	0	2	2.5	5	7.8	
Chest X-ray scoring (0-9)	1±1		3±2		4±3		<0.001

**[Table/Fig-3]:** Chest radiograph (CXR) score calculated as the sum of the number of zones involved and the number assigned to the lesion (0- ground glassing, 1- consolidation, 2- septal thickening). p-value <0.05 was considered statistically significant (calculated by One-way ANOVA with Tukey's Post-Hoc test)

CXR scores showed a statistically significant correlation with the inflammatory markers [Table/Fig-4]. ROC analysis showed a CXR score of 2 to differentiate between mild and non mild cases with a sensitivity of 78.29%, 77.98% specificity, 58.38% positive predictive and 90.11% negative predictive value. This value had an accuracy of 78.1%, with 0.848 Area Under The Curve (AUC) as shown in [Table/Fig-5]. [Table/Fig-6] shows the comparison of inflammatory markers between mild and non mild cases based on the criterion value 2 for CXR. [Table/Fig-7] describes the proposed CXR scoring system.

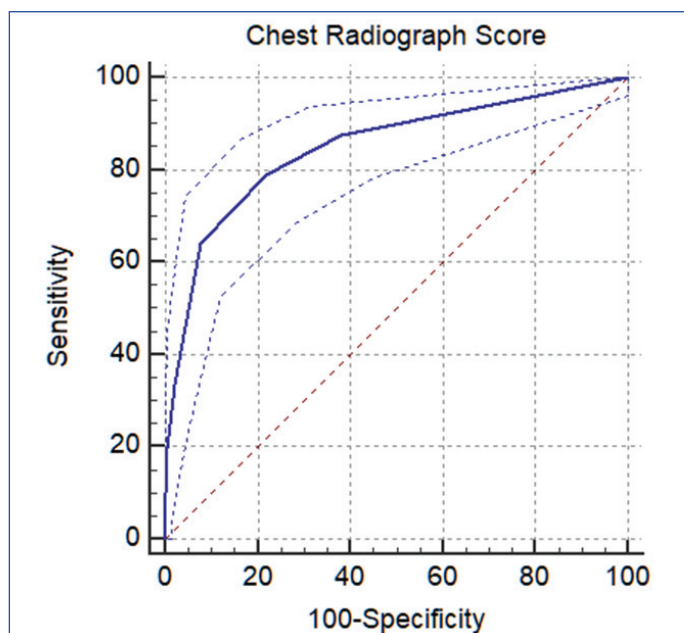
Parameters	Correlation coefficient*	p-value
NLR	0.546	<0.001
ALC	-0.444	<0.001
Eosinophil %	-0.363	<0.001
LDH	0.503	<0.001
D-dimer	0.47	<0.001
CRP	0.521	<0.001
ESR	0.346	<0.001
Ferritin	0.325	<0.001

**[Table/Fig-4]:** Correlation coefficients for chest radiograph score. p-value <0.05 was considered statistically significant; \*Spearman's rank correlation coefficient

## DISCUSSION

COVID-19 pandemic has placed an unprecedented burden on healthcare demanding a robust and simple-to-use screening algorithm which can help in prioritising management and predicting outcomes. In this study, the value of CXR at admission was explored in evaluating COVID-19 patients. The severity of the CXR opacity at admission was associated with severe form of disease clinically as well as the inflammatory markers.

Nearly, 63% of COVID-19 pneumonia patients have normal CXR particularly in early stages of infection and develop radiological findings as the disease progresses [3] with bilateral lung involvement being a common finding [15]. The index study also had similar findings- as the severity of the infection progressed, the number of zones involved in the CXR increased. The most common findings are ground glassing haze, consolidatory changes with patchy opacities which can progress to septal thickening [15,16], followed by presence of nodules, pneumothorax and pleural effusion (1-3%)



**[Table/Fig-5]:** Receiver Operating Characteristics (ROC) Curve for a CXR criterion of '2' to differentiate between mild and non mild COVID-19 infection. Area under the curve (AUC): 0.848.

Inflammatory markers	Chest X-ray score		p-value
	<2	≥2	
NLR	2.44±1.98	7±8.60	<0.001
ALC	1825±788	1237±624	<0.001
Eosinophil %	1.52±2.14	0.9±3.17	0.014
LDH	248±98	347±142	<0.001
D-dimer	0.63±1.59	2.32±6.97	0.002
CRP	2.1±3.7	7.2±9	<0.001
ESR	18.6±18.3	32±24.7	<0.001
Ferritin	173.2±206.5	362.9±512.5	<0.001

**[Table/Fig-6]:** Correlation of inflammatory markers with a Chest X-Ray (CXR) score criterion of '2'. p-value <0.05 was considered statistically significant (2-tailed t-test for equality of means)

Scoring system		
A	Number of lung zones involved (any abnormality)	Minimum: 0 Maximum: 6
B	Check the type of abnormality. Ground Glassing Opacities (GGO) in any zone: add '0' Consolidation in any zone: add '1' Septal Thickening present: add '2'	Minimum (normal or only GGO present): 0 Maximum (if both consolidation and septal thickening present): 1+2=3
	Total score (Add A+B)	Minimum: 0 Maximum: 9

**[Table/Fig-7]:** Proposed Chest X-Ray (CXR) scoring system.

[16]. In the present study, consolidation, and septal thickening was noted, and the frequency of involvement of various lobes was- right lower lobe (72%), followed by the left lower lobe (55%). Prior studies in COVID-19 and other pneumonias have shown a predilection to right lower lobe involvement, which could be related to the anatomical positioning of the right lower lobe bronchus [15, 17]. Age of the patients correlated with increased risk of higher CXR scores but gender did not demonstrate such correlation in the present study, which was in discordance with the observations of previous studies [11]. Since most of the patients in the study were males, the correlation between CXR and sex was not significant.

In the index study, the severity score of CXR was determined by the sum of number of zones involved, similar to the study by Toussie D et al., along with the pattern of opacity [11]. A score of more than 2 was able to effectively differentiate mild cases from moderate and severe ones with an accuracy of 78.1% and negative predictive value of 90.11%. In other words, the score could determine whether

the patient would require oxygen therapy and hospitalisation for COVID-19 infection.

Many scoring systems have been in place like the the British Society of Thoracic Imaging (BSTI) which recommends the use of severity grading in CXR as mild/moderate/severe in suspected COVID-19 infection. In the RALE score, the lungs are divided into quadrants, and the involvement and density are scored 0-48, where the quadrant scores are multiplied and then summed [14], a simplified version, where each lung is given a score of 0-4 based on the proportion of lung affected has also been tried [3]. Yet another CXR score, is the Brixia score [8,10], which is scored 0-18, where the left and right upper, middle and lower zones are each given a 0-3 score proportional to the lung involvement. All these scoring have been tried but when employed at the community becomes cumbersome calculating such high scores, so a simpler scoring that can be easily adopted which does not require more time and can be easily analysed was tried.

The index study tried a simpler scoring system similar to the method adopted by Toussie D et al., by dividing the CXR into 6 zones and further score based on the type of the opacity observed in the CXR [11]. This method serves to be a user friendly approach for the community level doctors also who need no special training for identifying the number of zones involved and the pattern of opacity in the CXR. Though, newer approach was attempted, the method served an easy approach to assess the CXR at bedside even at the community level. Given the possibility of multiple waves of infection and risk of radiation exposure from CT, CXR could serve as an effective screening tool for predicting the need for hospitalisation among COVID-19 patients, effectively reducing the economic burden on healthcare system, especially in resource limited settings.

### Limitation(s)

Correlation between the CXR and chest tomography and the amount of oxygen needed was not done. The score was not able to distinguish between severe disease and moderate infections, it was best suited to distinguish mild from non mild infections which included both moderate and severe forms.

### CONCLUSION(S)

In conclusion, this study demonstrated that CXR can be utilised as an effective tool to determine the clinical severity of COVID-19 infection. A CXR score of greater than 2 was able to distinguish moderate and severe infections from mild ones with an accuracy of 78.1%. Thus CXR may be used as a screening tool in determining the need for hospitalisation given that patients without mild infections require oxygen support thus reducing the burden on the healthcare system. However, the scoring method requires external validation for assessing the generalisability of the method.

### REFERENCES

- [1] Rubin GD, Ryerson CJ, Haramati LB, Sverzellati N, Kanne JP, Raouf S, et al. The role of chest imaging in patient management during the COVID-19 pandemic: A multinational consensus statement from the Fleischner Society. *Radiology*. 2020;296(1):172-80.
- [2] American College of Radiology. ACR recommendations for the use of CXR and computed tomography (CT) for suspected COVID-19 infection. <https://www.acr.org/Advocacy-and-Economics/ACR-Position-Statements/Recommendations-for-Chest-Radiography-and-CT-for-Suspected-COVID19-Infection>. Published March 11, 2020. Updated March 22, 2020. Accessed April 30, 2020.
- [3] Wong HYF, Lam HYS, Fong AH, Leung ST, Chin TW, Lo CSY, et al. Frequency and distribution of chest radiographic findings in patients positive for COVID-19. *Radiology*. 2020;296(2):E72-78.
- [4] Hui DSC, Wong KT, Antonio GE, Lee N, Wu A, Wong V, et al. Severe acute respiratory syndrome: Correlation between clinical outcome and radiologic features. *Radiology*. 2004;233(2):579-85.
- [5] Antonio GE, Wong KT, Tsui ELH, Chan DPN, Hui DSC, Ng AWH, et al. CXR scores as potential prognostic indicators in severe acute respiratory syndrome (SARS). *AJR Am J Roentgenol*. 2005;184(3):734-41.
- [6] Durrani M, Haq IU, Kalsoom U, Yousaf A. Chest x-rays findings in covid 19 patients at a university teaching hospital-a descriptive study. *Pakistan J Med Sci*. 2020;36:S22-26. Doi: 10.12669/pjms.36.COVID19-S4.2778.
- [7] Schiaffino S, Ritella S, Cozzi A, Carriero S, Blandi L, Ferraris L, et al. Diagnostic performance of chest X-Ray for COVID-19 pneumonia during the SARS-CoV-2 pandemic in Lombardy, Italy. *J Thorac Imaging*. 2020;35:W105-06. Doi: 10.1097/RTI.0000000000000533.
- [8] Borghesi A, Maroldi R. COVID-19 outbreak in Italy: Experimental chest X-ray scoring system for quantifying and monitoring disease progression. *Radiol Medica*. 2020;125:509-13. Doi: 10.1007/s11547-020-01200-3.
- [9] Borghesi A, Zigliani A, Masciullo R, Golemi S, Maculotti P, Farina D, et al. Radiographic severity index in COVID-19 pneumonia: Relationship to age and sex in 783 Italian patients. *Radiol. Medica*. 2020;125:461-64. Doi: 10.1007/s11547-020-01202-1.
- [10] Borghesi A, Zigliani A, Golemi S, Carapella N, Maculotti P, Farina D, et al. Chest X-ray severity index as a predictor of in-hospital mortality in coronavirus disease 2019: A study of 302 patients from Italy. *Int J Infect Dis*. 2020;96:291-93. Doi: 10.1016/j.ijid.2020.05.021.
- [11] Toussie D, Voutsinas N, Finkelstein M, Cedillo MA, Manna S, Maron SZ, et al. Clinical and CXR features determine patient outcomes in young and middle-aged adults with COVID-19. *Radiology*. 2020;297:E197-206. Doi: 10.1148/radiol.2020201754.
- [12] Balbi M, Caroli A, Corsi A, Milanese G, Surace A, Di Marco F, et al. Chest X-ray for predicting mortality and the need for ventilatory support in COVID-19 patients presenting to the emergency department. *Eur Radiol*. 2020. Doi: 10.1007/s00330-020-07270-1.
- [13] Thoracic Imaging in COVID-19 Infection|The British Society of Thoracic Imaging [https://www.bsti.org.uk/media/resources/files/BSTI\\_COVID-19\\_Radiology\\_Guidance\\_version\\_2\\_16.03.20.pdf](https://www.bsti.org.uk/media/resources/files/BSTI_COVID-19_Radiology_Guidance_version_2_16.03.20.pdf).
- [14] Homayounieh F, Zhang EW, Babaei R, Mobin HK, Sharifian M. Clinical and imaging features predict mortality in COVID-19 infection in Iran. *PLoS One*. 2020;15(9):e0239519. Doi: 10.1371/journal.pone.0239519.
- [15] Rodríguez-Morales AJ, Cardona-Ospina JA, Gutiérrez-Ocampo E, Pena RV, Rivera YH, Escalera-Antezana JP, et al., Latin American Network of Coronavirus Disease 2019-COVID-19 Research (LANCOVID-19). Electronic address: <https://www.lancovid.org>. Clinical, laboratory and imaging features of COVID-19: A systematic review and meta-analysis. *Travel Med Infect Dis*. 2020;34:101623. Doi: 10.1016/j.tmaid.2020.101623 pmid:32179124.
- [16] Jacobi A, Chung M, Bernheim A, Eber C. Portable chest X-ray in coronavirus disease-19 (COVID-19): A pictorial review. *Clin Imaging*. 2020;64:35-42. Doi: 10.1016/j.clinimag.2020.04.001 pmid:32302927
- [17] Wang Q, Zhang Z, Shi Y, Jiang Y. Emerging H7N9 influenza A (novel reassortant avian-origin) pneumonia: Radiologic findings. *Radiology*. 2013;268(3):882-89.

#### PARTICULARS OF CONTRIBUTORS:

1. Senior Resident, Department of General Medicine, Sri Ramachandra Institute of Higher Education and Research, Chennai, Tamil Nadu, India.
2. Senior Resident, Department of General Medicine, Sri Ramachandra Institute of Higher Education and Research, Chennai, Tamil Nadu, India.
3. Associate Professor, Department of General Medicine, Sri Ramachandra Institute of Higher Education and Research, Chennai, Tamil Nadu, India.
4. Professor, Department of General Medicine, Sri Ramachandra Institute of Higher Education and Research, Chennai, Tamil Nadu, India.

#### NAME, ADDRESS, E-MAIL ID OF THE CORRESPONDING AUTHOR:

Dr. Swathy Moorthy,  
Associate Professor, Department of General Medicine, Sri Ramachandra Institute of Higher Education and Research, Porur, Chennai, Tamil Nadu, India.  
E-mail: drswathy.moorthy@sriramachandra.edu.in

#### AUTHOR DECLARATION:

- Financial or Other Competing Interests: None
- Was Ethics Committee Approval obtained for this study? Yes
- Was informed consent obtained from the subjects involved in the study? Yes
- For any images presented appropriate consent has been obtained from the subjects. NA

#### PLAGIARISM CHECKING METHODS: [Jain H et al.]

- Plagiarism X-checker: Nov 23, 2021
- Manual Googling: Jan 27, 2022
- iThenticate Software: Feb 17, 2022 (10%)

#### ETYMOLOGY: Author Origin

Date of Submission: **Nov 20, 2021**  
Date of Peer Review: **Dec 29, 2021**  
Date of Acceptance: **Jan 28, 2022**  
Date of Publishing: **Apr 01, 2022**