

Lipomatous Hemangiopericytoma [Fat Forming Variant of Solitary Fibrous Tumour] – A Rare Variant of Hemangiopericytoma That Can Be Confused With Liposarcoma

PAILLOOR KIRANA, NAIK RAMESH, SWETHADRI GK, FERNANDES HILDA, JAYAPRAKASH CS

ABSTRACT

Lipomatous hemangiopericytoma is a very rare variant of hemangiopericytoma, which behaves in a benign fashion. It occurs in the lower extremity, the sinonasal area, the orbit, the neck, the mediastinum, the soft tissue of the shoulder, the retroperitoneum

and the pelvic fossa. Histologically, it is characterized by an admixture of benign hemangiopericytomatous areas with mature adipose tissue. To date, only very few of such cases have been reported in the literature. We report here, a case of this unusual, rare tumour which occurred in a 45 year old woman.

Key Words: Lipomatous hemangiopericytoma, Liposarcoma, Solitary fibrous tumour.

INTRODUCTION

Lipomatous Hemangiopericytoma is an uncommon, slow-growing, almost non-recurring, non-metastasizing mesenchymal neoplasm which is composed of mature adipocytes and hemangiopericytoma-like areas. Until now, fewer than 40 cases have been reported in the English literature.[1] It is a rare soft tissue tumour which was first reported in the German literature by Theunissen et al in 1990. Later, in 1995, Nielsen et al reported three cases of this tumour and described it in detail in the English literature. Here, we report a case of this tumour which occurred in the retroperitoneal region in a 45 year old woman.

CASE HISTORY

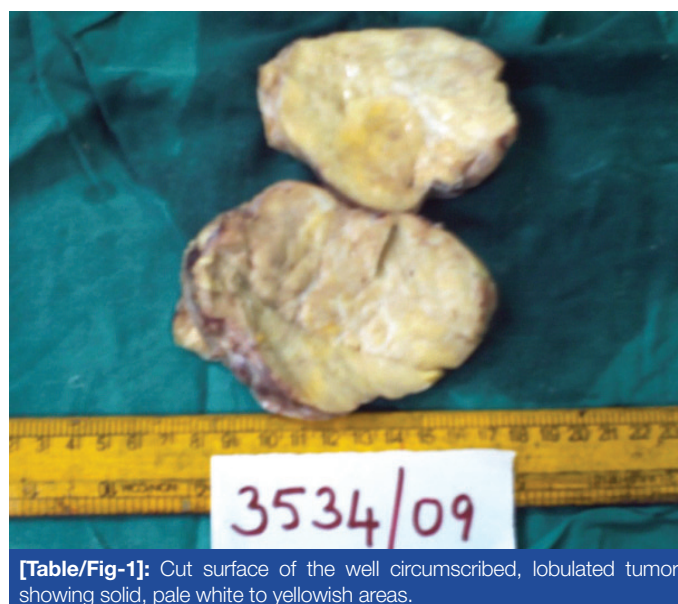
Clinical findings

A 45 year old lady presented with one year's history of pain in the lower abdomen. Her past medical history and family history were unremarkable. The lesion was discovered during her medical examination. Computed tomography [CT] demonstrated a large mass in the retroperitoneum which measured approximately 9.5x9x5cm, which was considered as a soft tissue tumour. The laboratory data were within normal limits. The patient underwent exploratory laparotomy with resection of the retroperitoneal mass. At the most recent follow-up, that is, 24 months after the surgery, there was no evidence of recurrence or metastasis.

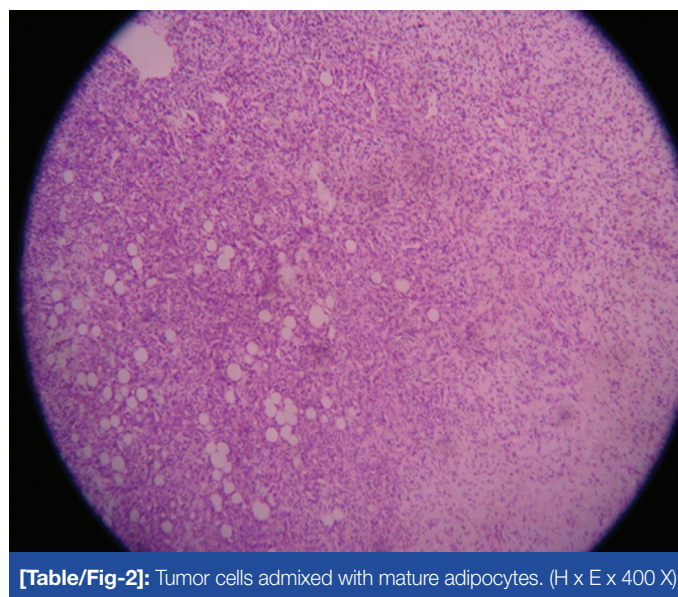
Pathologic findings

Gross : The retroperitoneal mass measured 9x9x4cm. The outer surface appeared nodular. The cut surface showed a well circumscribed, lobulated tumour with solid, pale white to yellowish areas [Table/Fig 1].

Light microscopy : The tumour was well-circumscribed and was surrounded by a thin fibrous tissue. It showed a lobular growth pattern and it consisted of cellular nodules with the classic appearance of hemangiopericytoma which was admixed with lobules of mature adipocytes [Table/Fig 2]. The hemangiopericytomatous



[Table/Fig-1]: Cut surface of the well circumscribed, lobulated tumor showing solid, pale white to yellowish areas.



[Table/Fig-2]: Tumor cells admixed with mature adipocytes. (H x E x 400 X)

regions were characterized by branching thin-walled capillary and sinusoidal vessels that had a staghorn configuration. Oval to spindle cells with bland nuclei, which were arranged in a random fashion, surrounded the vessels. These cells had a moderate amount of eosinophilic cytoplasm. The lipomatous regions were identified throughout the lesion and they varied from the lobules to the foci of the mature adipocytes; however no lipoblasts were identified. The neoplastic spindle cells [nonadipocytic cells] showed CD34 positivity. Based on all these findings, we diagnosed the tumour as lipomatous hemangiopericytoma.

DISCUSSION

Lipomatous hemangiopericytomas [fat - forming solitary fibrous tumours] are a rare variant of hemangiopericytoma, which is composed of mature adipocytes and hemangiopericytoma-like areas. These tumours have a wide anatomical distribution, including the pleura, mediastinum, thyroid and the head and neck, but the retroperitoneum and the deep soft tissues of the lower extremity, especially the thigh, are predominantly affected. Lipomatous hemangiopericytomas usually occur in middle-aged adults. Clinically, most of the lesions present as long-standing indolent tumours and do not metastasise or recur after resection. Until now, fewer than 40 cases of lipomatous hemangiopericytomas have been reported in the literature. [1 - 4].

The fat- forming variant of solitary fibrous tumours has been classified by the WHO as a rare variant of the solitary fibrous tumours. [5] In 1995, Nielsen et al initially reported three cases of a distinctive tumour which was composed of an admixture of hemangiopericytoma and mature adipose tissue. This rare entity was first reported in the German literature by Theunissen et al in 1990. The size of this tumour varies from 1.7cm to 21cm. [5, 6]

Grossly, it presents as a single, well-delineated lesion. On the cut surface, the tumour varies from tan-white to yellowish- white in appearance. Microscopically, it shows a varying combination of a cellular area which is composed of spindle cells and collagenous or myxoid stroma; a hemangiopericytoma-like vasculature which constitutes medium-sized to small branched vessels and lipomatous areas which are made up of mature adipocytes. [1, 5, 6] According to the recent WHO classification of soft tissue tumours, hemangiopericytomas were reported to be closely related to solitary fibrous tumours and lipomatous hemangiopericytoma was separately designated as a variant of hemangiopericytoma. [5,7] Recently, Gengler and Guillou proposed that lipomatous hemangiopericytoma might be regarded as a fat-forming variant of solitary fibrous tumours, because lipomatous hemangiopericytomas share the clinical, pathological, immunohistochemical and ultrastructural features of solitary fibrous tumours, except for the added presence of a fat component. Most of the lipomatous hemangiopericytomas exhibit reactivity for CD34 and CD99, as do the solitary fibrous tumours. [7]

Lipomatous hemangiopericytoma can be confused with other soft tissue tumours such as liposarcoma, spindle cell lipoma, dermatofibrosarcoma protuberans and conventional hemangiopericytoma with a normal fat trapping. [1 - 4, 8] The gross pathology is suggestive of a fat- containing tumour, giving the clinical impression of a lipomatous tumour. In fact, in our study, the initial clinical diagnosis was liposarcoma. Liposarcoma, especially the myxoid variant, can have a prominent vasculature. The vessels in myxoid liposarcoma demonstrate a delicate plexiform capillary vascular network, unlike the staghorn pattern of lipomatous

hemangiopericytoma. Furthermore, all of the fat-forming variants of solitary fibrous tumours are devoid of lipoblasts. They may show the presence of lipoblast-like cells. Well-differentiated liposarcoma has a broad fibrous septa containing atypical cells with hyperchromatic nuclei and a varying number of lipoblasts. Dedifferentiated liposarcoma usually shows some areas of high grade non-lipogenic malignancy. Dermatofibrosarcoma protuberans can also show CD34 positivity, but it also shows the presence of the classic storiform growth which is absent in lipomatous hemangiopericytoma. Hemangiopericytoma with normal fat trapping also should be considered in the differential diagnosis. But the tumour had a pseudocapsule and the distribution of the fat was relatively present throughout the tumour, which suggested that the fat was an integral component of the neoplasm. [1, 2, 9]

Nielsen et al hypothesized that immature adipocytes within the tumour may undergo adipocytic differentiation, following a pathway that occurs in normal embryological development and that has been observed in the primitive cells in liposarcoma. They suggested that the presence of the adipocyte cells exhibited a spectrum from the immature- appearing multivacuolated forms to the mature univacuolar cells, as was in our case. Our findings thus supported their theory. Weiss' criteria helps to differentiate a multivacuolated [lipoblast-like] fat containing cell from a typical lipoblast. She emphasized that in the context of liposarcoma, a lipoblast must demonstrate "a hyperchromatic indented or scalloped nucleus, lipid-rich[neutral fat] droplets in the cytoplasm and an appropriate histologic background." [2,3] Our case had multivacuolated lipoblast-like cells and lipoblasts were absent.

In conclusion, Lipomatous hemangiopericytoma is an extremely rare tumour which is pathologically characterized by an admixture of benign hemangiopericytomatous and lipomatous components. To date, all the lesions with follow up information have behaved in a benign fashion, including our case, although occasional ones have recurred. The principal significance of this variant is that it is easily mistaken for a well-differentiated liposarcoma, particularly when only a small biopsy specimen is available. Hence, this case highlights that it is indeed important for the clinicians, radiologists and pathologists to have a thorough knowledge of this tumour, for the purpose of an appropriate diagnosis and management.

REFERENCES

- [1] Kim MY, Rha SE, Oh SN et al. Lipomatous hemangiopericytoma [fat-forming solitary fibrous tumour] involving the perineum: CT and MRI findings and pathological correlation. *British Journal of Radiology* 2009; 82: e23-e6.
- [2] Nielsen GP, Dickersin GR, Provenzal JM, Rosenberg AE. Lipomatous hemangiopericytoma; a histologic, ultrastructural and immunohistochemical study of a unique variant of hemangiopericytoma. *Am J Surg Pathol* 1995;19/7:748-6.
- [3] Ceballos KM, Munk PL, Masri BA, O'Connell JX. Lipomatous hemangiopericytoma- a morphologically distinct soft tissue tumour. *Arch Pathol Lab Med.* 1999; 123: 941-5.
- [4] Folpe AL, Devaney K, Weiss SW. Lipomatous hemangiopericytoma. A rare variant of hemangiopericytoma that may be confused with liposarcoma. *Am J Surg Pathol* 1999; 23/10: 1201-07.
- [5] Guillou L, Fletcher JA, Fletcher CDM, Mandahl N. Extraleural solitary fibrous tumour and hemangiopericytoma. In: *Pathology and Genetics of tumours of soft tissue and bone.* Fletcher CDM, Unni KK, Mertens F. IARC Press, Lyon 2002. p.86-90.
- [6] Weiss SW, Goldblum JR. Soft tissue tumors of intermediate malignancy of uncertain type. In: *Enzinger and Weiss's soft tissue tumours.* 5th edn. Mosby 2008. p.1093-160.
- [7] Amonkar GP, Deshpande JR, Kandalkar BM. An unusual lipomatous hemangiopericytoma. *J Postgrad Med* 2006; 52/1:71-72.
- [8] Guillou L, Gebhard S, Coindre JM. Lipomatous hemangiopericytoma: a

fat- containing variant of a solitary fibrous tumour? Clinicopathological, immunohistochemical and ultrastructural analysis of a series in favour of a unifying concept. Hum Pathol 2000; 31/9: 1108-15.

[9] Xi L, Hong-ying Z, Hong BU, Guo-zhao M, Zhang Z, Qi K. Fat- forming variant of solitary fibrous tumour of the mediastinum. Chinese Medical Journal 2007;120/11: 1029-32.

AUTHOR(S):

1. Dr. Pailoor Kirana
2. Dr. Naik Ramesh
3. Dr. Swethadri GK
4. Dr. Fernandes Hilda
5. Dr. Jayaprakash CS

PARTICULARS OF CONTRIBUTORS:

1. Corresponding Author
2. CN, MD,DCP, epartment of Pathology, Father Muller Medical College, Mangalore
3. MD,DCP, Department of Pathology, Father Muller Medical College, Mangalore
4. MD, Department of Pathology, Father Muller Medical College, Mangalore
5. MD, Department of Pathology, Father Muller Medical College, Mangalore

NAME, ADDRESS, TELEPHONE, E-MAIL ID OF THE CORRESPONDING AUTHOR:

Dr. Kirana Pailoor
Assistant Professor, Department of Pathology,
Father Muller Medical College, Mangalore,
Karnataka state, India. 575002.
Phone : 919448953716, 08242222569.
E-mail : dockirana@yahoo.co.uk

DECLARATION ON COMPETING INTERESTS:

No conflicting Interests.

Date of Submission: **Apr 13, 2011**
Date of per review: **Aug 19, 2011**
Date of acceptance: **Aug 29, 2011**
Date of Publishing: **Nov 11, 2011**