


Masturbation Injury Following Intravaginal Introduction of a Candlestick: A Case Report

GBOLAHAN OLADELE OBAJIMI¹, OLATUNJI OKIKIOLA LAWAL², RASHEEDAT OMOLOLA BALOGUN³, ANJOLA-OLUWA ABISOLA AJAYI⁴, GBOYEGA BOSUN AJIBOLA⁵



ABSTRACT

Masturbation, a common sexual behaviour, may result in life-threatening injuries. Here, the authors present a case of 40-year-old female patient, P2L2 who presented to the Gynaecological Emergency unit, on account of a three-hour history of bleeding per vagina following candlestick masturbation which resulted in a 4 cm right lateral vaginal fornix laceration and accompanying Hypovolaemic shock. She was separated from her husband for a period of two years. She underwent examination under anaesthesia and repair of vaginal laceration. Postoperatively, she had one unit of blood transfused and was discharged home on haematinics, broad spectrum antibiotics and analgesics. Counselling on marital stress and sexual distress was provided, while encouraging the use of adult sex toys in favour of improvised ones when necessary.

Keywords: Hypovolaemic shock, Sexual behaviour, Vaginal laceration

CASE REPORT

A 40-year-old P2L2 female patient, presented to the Gynaecological Emergency unit at University College Hospital, Ibadan, Oyo, Nigeria, on account of a three-hour history of bleeding per vagina due to masturbation with the use of a candlestick. There was associated passage of blood clots with an estimated blood loss of about 500 mL. She also complained of generalised body weakness and dizziness, but no fainting spells, loss of consciousness or abdominal pain. She was separated from her husband for about two years. On examination, she was a moderately pale and dehydrated lady who was speaking irrationally. She had a pulse rate of 114 beats per minute and blood pressure of 80/40 mmHg. There was no abdominal tenderness. On vaginal examination, the perineal pad was soaked with blood. About 300 mL of blood clot was evacuated from the vagina. Speculum examination revealed a 4 cm defect in the right lateral vaginal fornix and a diagnosis of life-threatening vaginal laceration following masturbation was made.

Resuscitation was commenced with intravenous crystalloids. She was informed about the findings and her consent was obtained for examination under anaesthesia and repair of vaginal laceration. During surgery, an actively bleeding 4 cm curvilinear defect with a depth of 0.5 cm was noted in the right lateral vaginal fornix [Table/Fig-1]. This was repaired with an absorbable vicryl (polyglactin) 0 suture. Estimated blood loss at surgery was about 50 mL. She recovered

smoothly from anaesthesia and had one unit of whole blood transfused postoperatively. Her post transfusion packed cell volume was 29% and she was discharged home after 24 hours of observation on haematinics, broad spectrum antibiotics and analgesics.

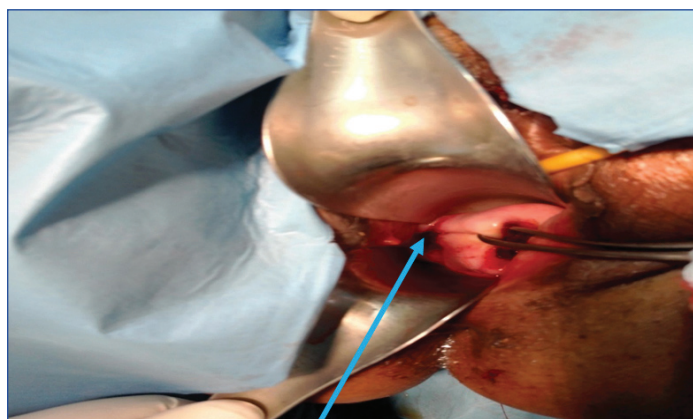
A follow-up review after two weeks revealed a healthy lady with a packed cell volume of 31%. She was counselled on the importance of lubrication before coitus and encouraged for using improvised adult sex toys. She was admonished on the need to procure a proper adult sex toy such as a vibrator and or dildo which were designed for maximum pleasure and comfort, while minimising coital injury. She was discharged from the gynaecological clinic and referred for counselling on marital and sexual distress.

DISCUSSION

Masturbation is a very common sexual behaviour occurring in about 90% of men and 60% of women at certain times in their life [1]. It is defined as sexual gratification involving self-stimulation to achieve an orgasm. Masturbation derives from the Latin words 'manus' and 'stupratio' referring to 'hand' and 'defilement', respectively [2]. It has been documented to be practiced at all ages and even observed in utero [2,3]. There is clearly no evidence to support any negative health effect of masturbation [4], however abstinence from masturbation is very often recommended to improve an individual's sexual self-regulation [4].

The patient was separated from her spouse for about two years, and she found masturbation an alternative to fulfilling her sexual desires while eliminating the risk of contracting Sexually Transmitted Diseases (STD). Marital disharmony is a risk factor for conjugal mobility and may predispose either party to resort to masturbation. Masturbation if practiced must be done appropriately using available sex toys designed for maximum pleasure whilst minimising genital injuries [5].

Coital injuries at masturbation range from vaginal lacerations in women to penile fractures in men [6]. The most common site for injury in women is the posterior fornix [7] and injury often results from poor lubrication and vigorous sexual intercourse. The use of a candlestick for masturbation is quite bizarre and predisposes to coital injury especially when a large thrusting force is applied against the background of poor lubrication. Accidental autoerotic asphyxia has been reported in literature following failure of devices used



[Table/Fig-1]: Right lateral vaginal fornix laceration (arrowed) following candlestick masturbation.

to enhance sexual response during masturbation. These devices include gasmasks and plastic bags used to cover the head and induce hypoxia during masturbation [8,9].

Providing counselling through cognitive behavioural therapy is important in ameliorating marital stress and sexual distress [10]. This was offered to the patient in addition to providing information on the acquisition and proper use of adult sex toys.

CONCLUSION(S)

Masturbation injuries may follow the use of an improvised adult sex toy. Patient in this case report, presented with hypovolaemic shock following a life-threatening vaginal laceration sustained during candlestick masturbation. The choice of this household item may be due its perceived suitability evidenced by its shape, rigidity, lowcost and ability to conceal its intended use. Providing counselling on sexual distress especially against a background of marital instability along with information about adult sex toys where necessary is not only imperative but logical in reducing the occurrence of masturbation injuries.

REFERENCES

- [1] Nechay A, Ross LM, Stephenson JB, O'Regan M. Gratification disorder ("infantile masturbation"): A review. *Arch Dis Child*. 2004;89(3):225-26. Doi: 10.1136/adc.2003.032102. PMID: 14977696; PMCID: PMC1719833.

- [2] Shamo'on H. Early childhood masturbation: A clinical study. *J Med J*. 2021;39(1):23-26.
- [3] Meizner I. Sonographic observation of in utero fetal "masturbation". *J Ultrasound Med*. 1987;6(2):111. Doi: 10.7863/jum.1987.6.2.111. PMID: 3550126.
- [4] Zimmer F, Imhoff R. Abstinence from masturbation and hypersexuality. *Arch Sex Behav*. 2020;49(4):1333-43. Doi: 10.1007/s10508-019-01623-8. Epub 2020 Mar 4. PMID: 32130561; PMCID: PMC7145784.
- [5] Klein V, Rettenberger M, Briken P. Self-reported indicators of hypersexuality and its correlates in a female online sample. *J Sex Med*. 2014;11(8):1974-81. Doi: 10.1111/jsm.12602. Epub 2014 Jun 9. PMID: 24909396.
- [6] Bhardwaj R, Gaurav G, Alam S. Penile Fracture during masturbation- A case report. *J Family Med Prim Care*. 2020;9(11):5790-92. Doi: 10.4103/jfmpc.jfmpc_1160_20. PMID: 33532436; PMCID: PMC7842420.
- [7] Savaş A, Efesooy O, Cayan F, Cayan S. Sexual injuries during consensual sexual activity. *Ulus Travma Acil Cerrahi Derg*. 2012;18(6):519-23. Turkish. Doi: 10.5505/tjtes.2012.47347. PMID: 23588912.
- [8] Idota N, Nakamura M, Tsuboi H, Ichioka H, Shintani-Ishida K, Ikegaya H. Autoerotic asphyxia using a plastic bag loosely covering the head over a gas mask. *Leg Med (Tokyo)*. 2019;38:69-72. Doi: 10.1016/j.legalmed.2019.04.006. Epub 2019 Apr 15. PMID: 31009906.
- [9] Jung SK. An autoerotic death in Korea. *Med Sci Law*. 2013;53(1):48-50. Doi: 10.1258/msl.2012.012033. Epub 2012 Aug 31. PMID: 22941517.
- [10] Rashedi S, Maasoumi R, Vosoughi N, Haghani S. The effect of mindfulness-based cognitive-behavioral sex therapy on improving sexual desire disorder, sexual distress, sexual self-disclosure and sexual function in women: A randomized controlled clinical trial. *J Sex Marital Ther*. 2021;1-14. Doi: 10.1080/0092623X.2021.2008075. Epub ahead of print. PMID: 34895064.

PARTICULARS OF CONTRIBUTORS:

1. Consultant, Department of Obstetrics and Gynaecology, University College Hospital, Ibadan, Oyo, Nigeria.
2. Consultant, Department of Obstetrics and Gynaecology, University College Hospital, Ibadan, Oyo, Nigeria.
3. Senior Registrar, Department of Obstetrics and Gynaecology, University College Hospital, Ibadan, Oyo, Nigeria.
4. Registrar, Department of Obstetrics and Gynaecology, University College Hospital, Ibadan, Oyo, Nigeria.
5. Registrar, Department of Obstetrics and Gynaecology, University College Hospital, Ibadan, Oyo, Nigeria.

NAME, ADDRESS, E-MAIL ID OF THE CORRESPONDING AUTHOR:

Gbolahan Oladele Obajimi,
PO BOX 29245, Secretariat Ibadan., Ibadan, Oyo, Nigeria.
E-mail: gbolahanobajimi@gmail.com

PLAGIARISM CHECKING METHODS: [Jain H et al.]

- Plagiarism X-checker: Feb 05, 2022
- Manual Googling: Mar 17, 2022
- iThenticate Software: Mar 19, 2022 (1%)

ETYMOLOGY: Author Origin

AUTHOR DECLARATION:

- Financial or Other Competing Interests: None
- Was informed consent obtained from the subjects involved in the study? Yes
- For any images presented appropriate consent has been obtained from the subjects. Yes

Date of Submission: **Jan 31, 2022**

Date of Peer Review: **Feb 24, 2022**

Date of Acceptance: **Mar 21, 2022**

Date of Publishing: **May 01, 2022**