

Non-Sliding Appendiceal Hernia (Amyand's Hernia): A Case Report

SUNIL TELKAR, B V GOUDAR, Y P LAMANI, UDAY AMBI

ABSTRACT

Inguinal hernias are sometimes difficult to reduce; one reason for this is that there may be a sliding component. The presence of an appendix in a hernial sac (Amyand's hernia) is a rare entity and the incidence of having an appendix in the hernial sac is less than 1%. Usually, the appendix has been shown to be a

part of a sliding hernia and it may be adherent to the sac, most commonly to the mesoappendix rather than the appendix itself and it makes up all or some part of the postero-medial wall of a hernial sac. We report here, an unusual case in which the appendix passed through a hernia sac and was not part of a sliding hernia.

Key Words: Non-Sliding appendiceal hernia, Amyand's Hernia, Hernial sac

INTRODUCTION

In 1735, Claudius Amyand described the removal of a perforated appendix in a right inguinal hernial sac, in what is now regarded as the first ever appendectomy [1]. It remains a rare and infrequently reported entity till date, with an estimated incidence of 0.13% among all the reported patients of appendicitis. With the advent of laparoscopic surgery, Amyand's hernia has been reported in a port-site incisional hernia [2]. We report here, an unusual case in which the appendix passed through the hernia sac with fecolith in the terminal part.

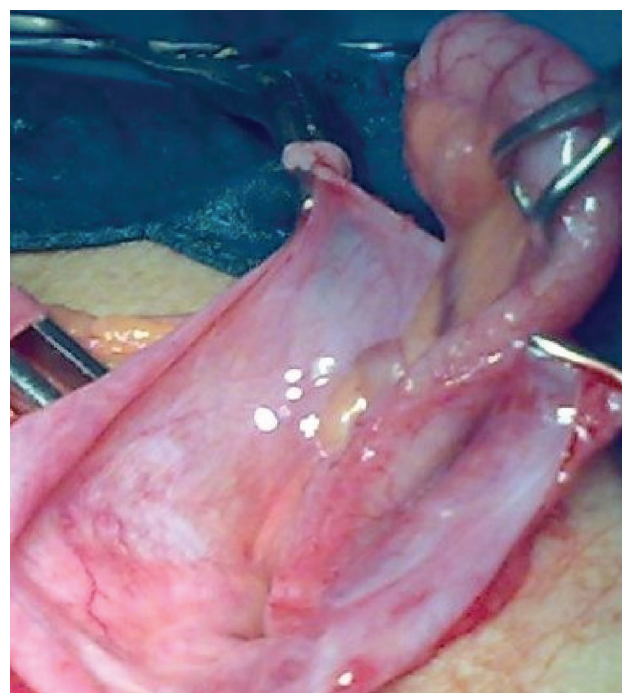
CASE REPORT

A 72 year old male patient presented with pain and distension of the abdomen. On examination, he was found to have obstructed, right sided, indirect, inguinal hernia. The lobular swelling extended up to the right scrotum with peristalsis and was irreducible. The patient was a known case of Ischemic Heart Disease with Benign Prostrate Hypertrophy. A high risk informed written consent was taken from him. The patient was operated through a right inguino-scrotal incision and the sac was dissected from the cord structures. The intestinal coils were found to be normal and they were pushed into the abdomen. The appendix was found posteriorly and it was normal, free, without adhesions and with a fecolith at its tip, without inflammation. It was pushed inside the abdomen and the sac was closed after transfixation. Hernioplasty was done by keeping a Prolene mesh and the wound was closed in layers. Post-operatively, the wound healed, with primary intention.

DISCUSSION

The presence of an appendix in a hernial sac is a rare entity and an incarcerated hernia with an inflamed appendix is still rare [3], though this abnormal location makes the appendix more vulnerable to repeated trauma and subsequent inflammation [4]. Acute appendicitis in a hernial sac is rarely diagnosed pre-operatively and is often misdiagnosed as either testicular torsion or epididymo-orchitis, although CT scan of the abdomen may be help in reaching the correct diagnosis. Most of the cases have been diagnosed intra-operatively after opening the hernial sac. Only a

single report of a pre-operative diagnosis exists [5]. The treatment is appendectomy with primary hernia repair. Controversy exists regarding appendectomy in an Amyand's hernia which involves a non-inflamed appendix. Various guidelines have been proposed [6], but the risk of wound infection and subsequent recurrence of the hernia remains a cause of concern if the appendix is removed. However, the development of acute appendicitis after the repair of a hernia which contained the appendix has also been reported. A definite solution to the problem is unlikely, as clinical trials are not feasible, owing to the rarity of the condition. The use of mesh for hernia repair in a contaminated wound is open for debate. Losanoff described the management of Amyand's hernia. Losanoff's type I hernia (normal appendix within sac) should be managed by hernioplasty without appendectomy and Losanoff's types II-IV hernia (acute appendicitis within the sac) requires appendectomy, followed by hernia repair without prosthesis [7]. In our case, due



[Table/Fig-1]: Amyand's Hernia, Showing appendix within the hernial sac

to the controversy in the way of the management and as the appendix did not show any signs of inflammation except for the fecolith, we placed it into the peritoneal cavity and did hernioplasty (mesh repair).

REFERENCES

- [1] Creese PG. The first appendectomy. Surgery.Gynecol Obstet 1953 ;97: 643-52.
- [2] Bamberger PK. Revisiting Amyand's hernia in the laparoscopic era. Surg Endosc 2001 ;15:1051.
- [3] Abu-Dalu,J. Urea. Incarcerated inguinal hernia with a perforated appendix and periappendicular abscess. Dis Colon Rectum. 1972 ; 15:464-5.
- [4] Weber RU, Hunt ZC, Kraal JG. Amyand's hernia; etiologic and therapeutic implications of two complications. Surg Rounds 1999 ; 22:552-6.
- [5] Logan MT, Nottingham JM. Amyand's hernia: a case report of an incarcerated and perforated appendix within an inguinal hernia and review of literature. Am Surg 2001;67:628-9.
- [6] Fisher KS, Ross DS. Guidelines for the therapeutic decision in incidental appendectomy. Surg Gynecol Obstet 1990 ;171:95-8.
- [7] Losanoff JE, Basson MD. Amyand's hernia : what lies beneath-a proposed classification scheme to determine its management. Am Surg 2007; 73 :1288-90.

AUTHOR(S):

1. Dr. Sunil Telkar
2. B V Goudar, MS
3. Y P Lamani
4. Uday Ambi

PARTICULARS OF CONTRIBUTORS:

1. Corresponding Author
2. MS, Associate Professor, Dept. of Surgery, SN Medical College and HSK Hospital, Bagalkot, Karnataka, India
3. MS, Assistant Professor, Dept. of Surgery, SN Medical College and HSK Hospital, Bagalkot, Karnataka, India
4. Assistant Professor, Dept. of Anaesthesiology, SN Medical College and HSK Hospital, Bagalkot, Karnataka, India

NAME, ADDRESS, TELEPHONE, E-MAIL ID OF THE CORRESPONDING AUTHOR:

Dr. Sunil Telkar
 Assistant Professor, Dept. of Surgery, SN Medical College and HSK Hospital, Bagalkot, Karnataka, India-587101,
 Phone : +918354-235400
 Email : telkar@gmail.com

DECLARATION ON COMPETING INTERESTS:

No conflicting Interests.

Date of Submission: **Jun 24, 2011**
 Date of per review: **Aug 01, 2011**
 Date of acceptance: **Sep 03, 2011**
 Date of Publishing: **Nov 11, 2011**