

# Little Old Lady's Hernia with Hiatus Hernia- A Case Report

N NASIDA FATHIMA<sup>1</sup>, SUSHANTO NEOGI<sup>2</sup>, MANU VATS<sup>3</sup>, SURYA ELANGOVAN<sup>4</sup>

CC BY-NC-ND

## ABSTRACT

With the outbreak of the Coronavirus Disease-2019 (COVID-19) pandemic, it is not uncommon to see patients who present with respiratory symptoms secondary to an abdominal pathology, being suspected of having COVID-19. Here, authors report a case of an 80-year-old female who presented with recent-onset dyspnoea, shortness of breath, pain abdomen and non passage of flatus and stools. Examination revealed that the patient had tachycardia, tachypnoea, and dyspnoea with an oxygen saturation (SpO<sub>2</sub>) of 92%. Her abdomen was distended, non tender with no free fluid detected. All the hernial orifices were free. Computed Tomography (CT) scan revealed a left diaphragmatic hernia and a left-sided obturator hernia with obstructed ileal segment. However, intraoperatively a Type IV hiatus hernia was discovered, where the Gastrooesophageal (GE) junction, stomach, colon, and omentum were the contents. This case highlights an unusual clinical presentation of a rare cause of intestinal obstruction and its management during the COVID-19 pandemic. Obstructed obturator hernia is associated with high morbidity and mortality.

**Keywords:** Digestive system surgical procedures, Intestinal, Obstruction, Obturator

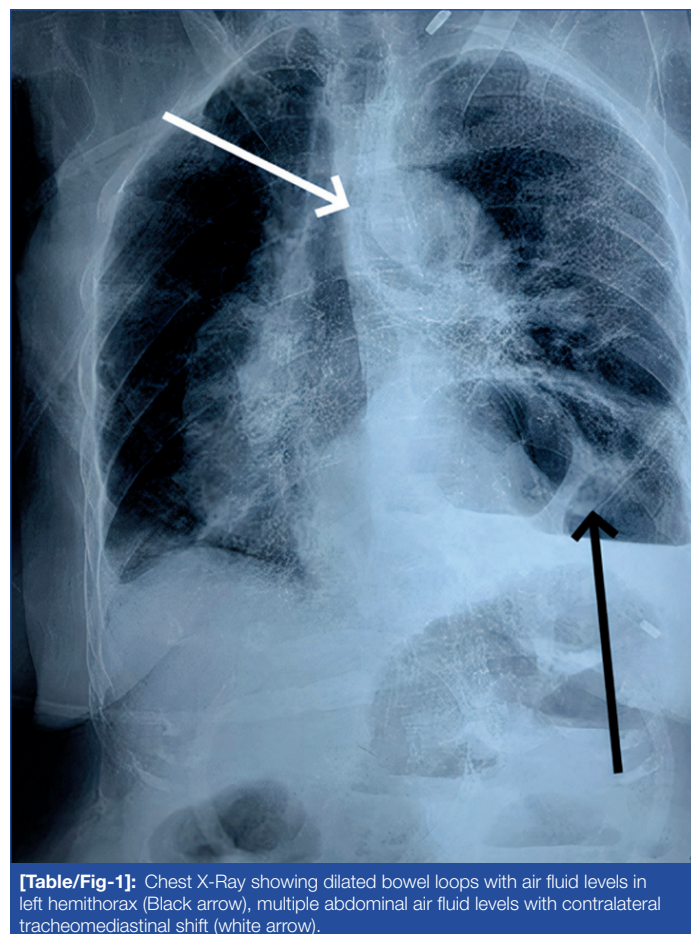
## CASE REPORT

An 80-year-old lady presented to the emergency department during the COVID-19 pandemic, with dyspnoea, shortness of breath, abdominal pain, vomiting and non passage of flatus and stools. In view of the respiratory complaints, she was admitted to a COVID-19 suspect ward, and a general surgery consult was sought. The patient gave a history of fall from one flight of stairs, five years ago, for which medical consultation was not taken. She had no previous complaints of retrosternal discomfort, heartburn, regurgitation or haematemesis.

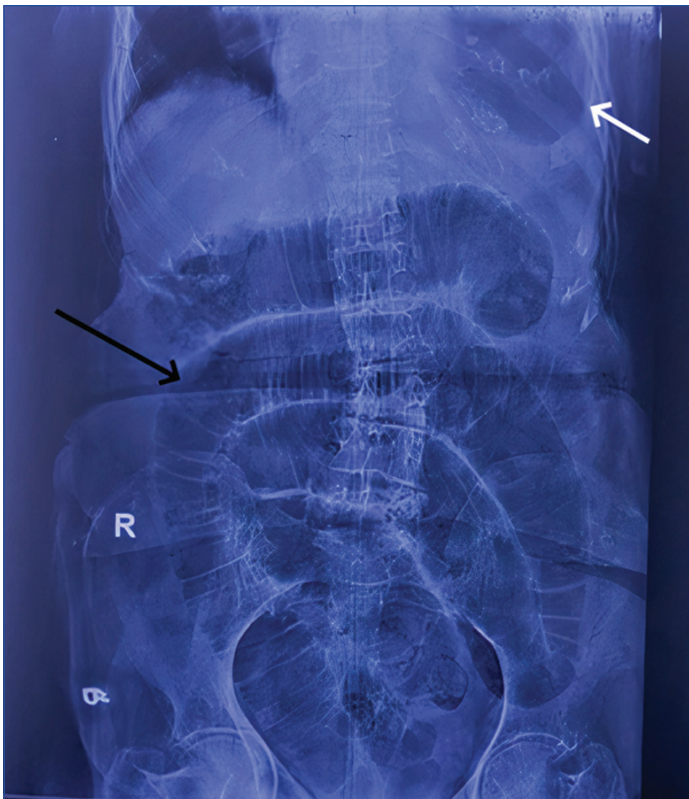
On examination, the patient was tachycardic, tachypnoeic and dyspnoeic with SpO<sub>2</sub> of 92%. Her abdomen was distended, non tender with no evidence of free fluid; bilateral inguinal and umbilical areas did not reveal any hernia. No mass was palpable on digital rectal examination. The patient underwent all routine investigations including a chest X-ray, Non Contrast Computed Tomography (NCCT)-abdomen and Reverse Transcriptase Polymerase Chain Reaction (RT-PCR) for COVID-19. The patient was administered oxygen by face mask and a nasogastric tube was inserted to decompress the stomach. Her chest X-ray revealed dilated bowel loops with air-fluid levels within the left hemithorax, with contralateral mediastinal shift [Table/Fig-1]. Abdominal X-ray showed dilated small bowel loops suggestive of small intestinal obstruction [Table/Fig-2].

The NCCT scan demonstrated a left-sided diaphragmatic hernia along with a left-sided obstructed obturator hernia [Table/Fig-3,4]. The diaphragmatic defect measured 5.3×7.4 cm through which the GE junction, stomach, along with proximal small bowel loops and splenic flexure of colon had herniated into the thoracic cavity. The dilated stomach was positioned against the posterior ribs and the posterior costophrenic recess was obliterated on dependent position- the dependent viscera sign. Contralateral tracheal mediastinal shift and atelectasis of basal segments of the left lower lobe was also noted. The CT scan also reported herniation of an ileal segment and omental fat between obturator and pectineus muscles on the left-side suggestive of an obturator hernia. It also revealed dilatation of proximal ileal loops measuring approximately 3.7cm in calibre suggestive of obstruction. There was no evidence of any intraperitoneal free air foci. The RT-PCR for COVID-19 was reported negative.

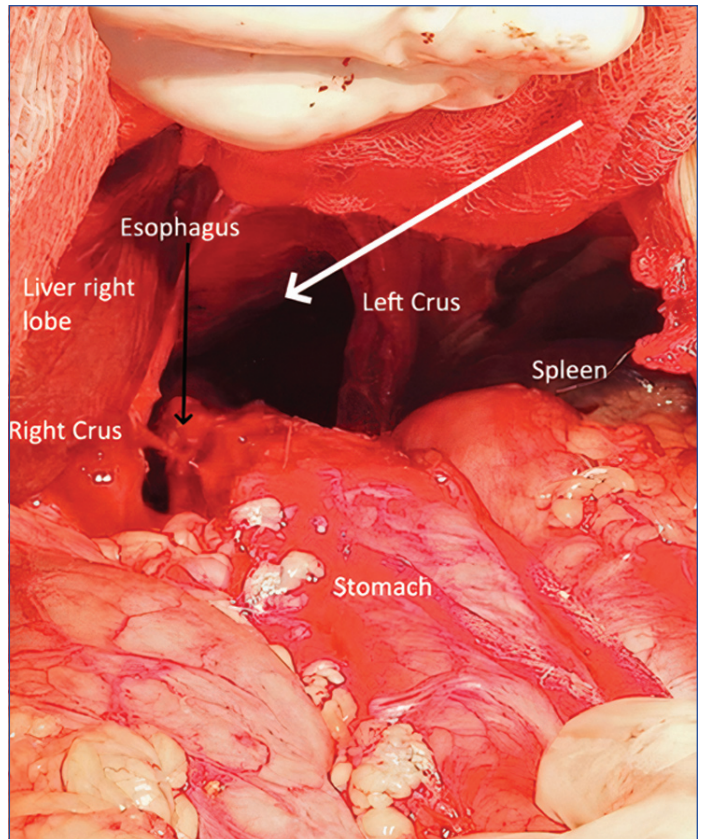
With a provisional diagnosis of an obstructed left obturator hernia and left-sided diaphragmatic hernia, the patient was taken up for an emergency exploratory laparotomy. To our surprise, abdominal exploration revealed a large defect measuring approximately 7×9 cm in the left paraesophageal membrane [Table/Fig-5] with GE junction, stomach, small bowel, and omentum herniating through it into the chest suggestive of a type IV hiatal hernia [Table/Fig-6] [1]. In the left lower abdomen, an ileal loop (150 cm from ileocaecal junction) was found herniating through a defect in the left obturator membrane (3×2 cm). Multiple jejunal diverticulosis was also found [Table/Fig-7].



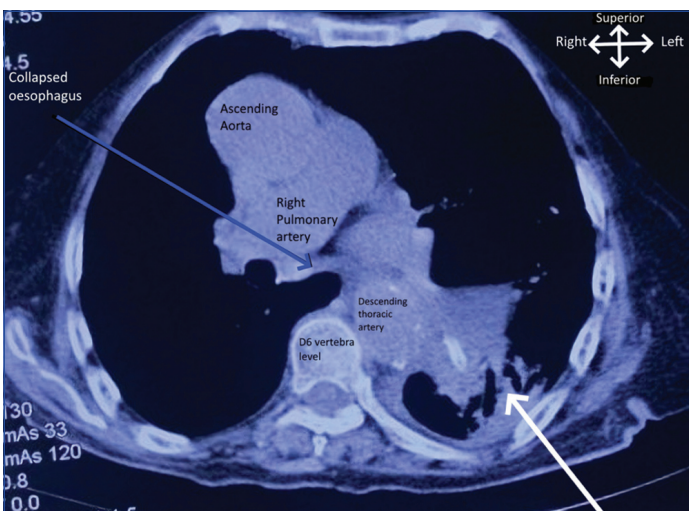
**[Table/Fig-1]:** Chest X-Ray showing dilated bowel loops with air fluid levels in left hemithorax (Black arrow), multiple abdominal air fluid levels with contralateral tracheo mediastinal shift (white arrow).



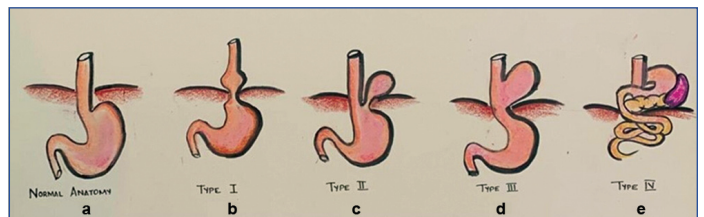
**[Table/Fig-2]:** Abdominal X-ray (supine) showing dilated small bowel (jejunal) loops in the abdomen (Black arrow) and gastric shadow in the left hemithorax (white arrow).



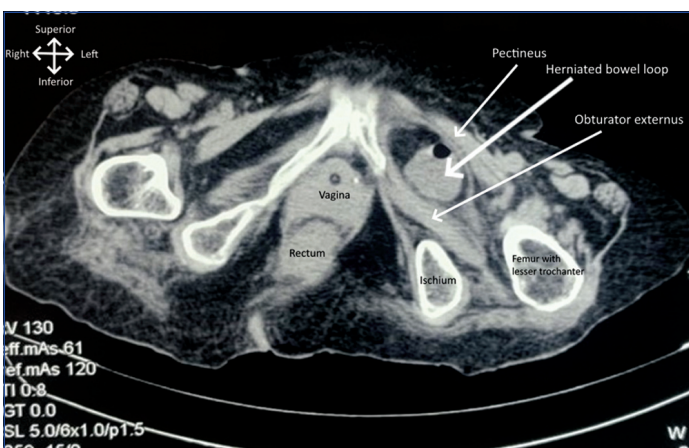**[Table/Fig-5]:** Intraoperative findings. Large defect in the left paraoesophageal membrane (Solid White arrow) after reduction of herniated contents.



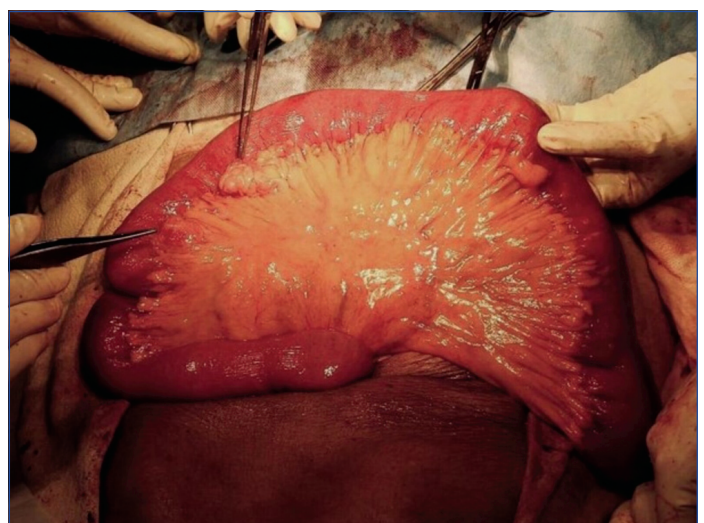
**[Table/Fig-3]:** CT scan Chest and Abdomen (Axial section D6 vertebral level) Herniation of intra-abdominal viscera into the left posterior mediastinum with contralateral tracheo-oesophageal shift (Solid white arrow).



**[Table/Fig-6]:** Types of hiatal hernia; a) Normal anatomy; b) Type I or sliding hiatal hernia; c) Type II or "True" paraoesophageal hernia; d) Type III or "mixed" paraoesophageal hernia; e) Type IV Paraoesophageal hernia, containing other intra-abdominal organs [1].



**[Table/Fig-4]:** NCCT scan Abdomen (Axial section at pelvis) showing herniated ileal loop between obturator externus and pectineus muscle (Solid white arrow).

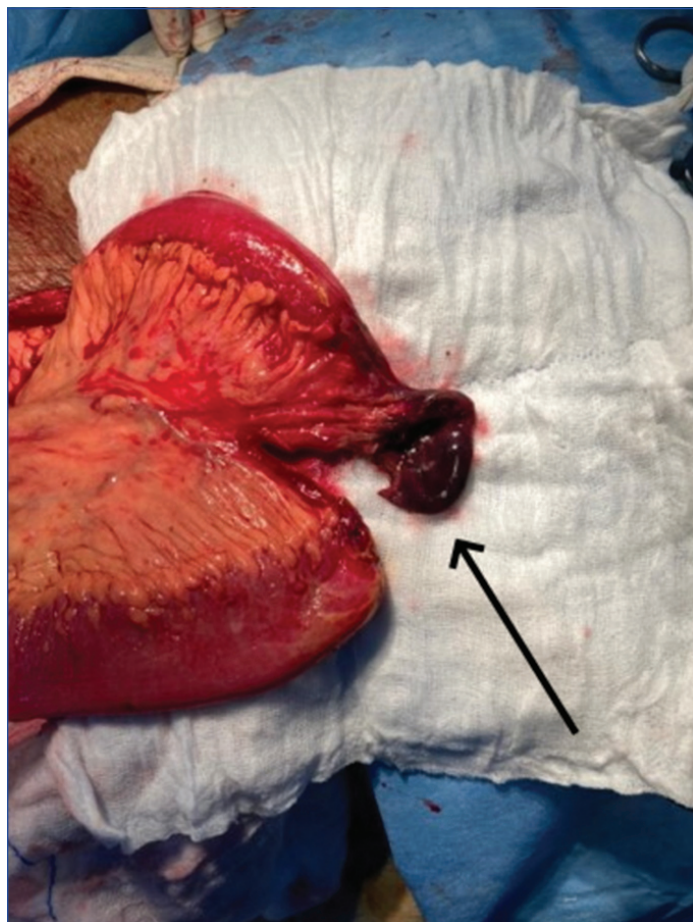


**[Table/Fig-7]:** Intraoperative findings. Multiple jejunal diverticulosis (pointers).

The herniated contents (GE junction, stomach, small bowel, and omentum) were reduced through the diaphragmatic defect after

ensuring an adequate length of intra-abdominal oesophagus. Primary repair of the hiatal defect was done using non absorbable (polypropylene) interrupted sutures and a left-side tube thoracostomy was done. After closure of the defect, a gastropexy (fundus hitched to lateral abdominal wall) was done to maintain the position of the stomach and prevent recurrence. The herniated ileal segment was reduced after the obturator membrane aperture was widened. The

herniated ileal segment was gangrenous and already perforated [Table/Fig-8]. Resection of the gangrenous segment and an end-to-end anastomosis of ileum were done, along with primary closure of obturator defect using interrupted polypropylene suture.



**[Table/Fig-8]:** Perioperative findings. Gangrenous herniated ileal segment after reduction of obturator hernia (black arrow).

The patient could not be extubated postoperatively due to poor respiratory effort. She was shifted to the Intensive Care Unit (ICU) after the procedure and remained on mechanical ventilation for the next two days. The patient was administered antibiotics and a prophylactic dose of low molecular weight heparin subcutaneously in view of prolonged duration of surgery. The patient was extubated and shifted back to the surgical ward on Post Operative Day (POD) 3. During the early postoperative period, she complained only of mild surgical site pain. The output from the abdominal drain and thoracostomy tube was serous in nature and was progressively decreasing. On postoperative day 6, she developed sudden onset respiratory distress, and tachycardia. An Arterial Blood Gas (ABG) analysis showed refractory respiratory alkalosis. She was intubated again and shifted to ICU and put on mechanical ventilation.

However, in spite of our best efforts, she succumbed to death within a few hours, the cause may have been pulmonary thromboembolism.

## DISCUSSION

Obturator hernia is defined as the protrusion of intraperitoneal or extraperitoneal contents through the obturator canal [2]. Obturator hernias make up only 0.05-2.2% of all hernias [3]. Although rare, it has the highest mortality rate amongst all hernias [4]. Establishing a preoperative diagnosis is a challenge, and it is often missed due to paucity of clinical features that are commonly observed in other inguinal and ventral wall hernias [5]. With ageing, there is thinning of fat in the obturator canal, increasing the likelihood of herniation in women of the age group 70-90 years. Obturator hernia is thus also known as 'little old lady's hernia' [6]. The clinical features are often vague and include vomiting, lower abdominal pain, and obstipation.

The Howship-Romberg sign (lancinating pain accentuated by extending, abducting, and internally rotating the hip due to obturator nerve impingement) is considered pathognomonic but is only found in approximately 15-50% of patients [7]. A mass felt per vaginam or per rectal examination, in addition to the above findings strongly favours this diagnosis. In some patients, there occur frequent episodes of intestinal obstruction without any lump in the groin. The diagnosis is either confirmed with the help of a CT scan or during exploratory surgery.

In an extensive review of 43 patients of obturator hernia encountered over a time span of 31 years, Kammori M et al., observed that a majority of patients had presented with signs and symptoms of acute intestinal obstruction and a positive Howship-Romberg sign. Lower midline laparotomy was done in all cases and the herniated small bowel segment was reduced after widening the obturator aperture. Resection and anastomosis of the small bowel was done in cases where the small bowel was found gangrenous. The authors used interrupted or purse string sutures to close the defect in 20 patients, the ovary or the uterus in 20 patients and the prosthetic mesh in three patients. Complications during the postoperative period were seen in 37 patients. The authors proposed that early diagnosis using CT scan improved patient prognosis and reduced the incidence of gut resection [8].

Preoperative CT scan accurately picked up obturator hernia in all 10 patients in one such study. All 10 patients underwent surgery and recovered [9]. In fact, establishing an early diagnosis with the help of a CT scan and following it up with an immediate laparotomy/laparoscopy has a favourable prognosis [10]. However, on a rare occasion, an obstructed obturator hernia may be masked by an overlying inguinal hernia and be missed on a CT scan. Diagnostic laparoscopy can be useful in such cases [11]. Laparoscopic repair (transabdominal preperitoneal) is also a viable option where expertise is available [12]. It was observed that non survivors had elevated levels of blood urea, constipation greater than two days, low urine output, significantly longer operative time, and increased postoperative complications [12,13]. Although majority of obturator hernias are repaired using a mesh, it is not advocated in cases where the bowel is strangulated or perforated. In such cases, the hernial sac is ligated using continuous non absorbable sutures and the foramen is closed using biological or synthetic material [14]. In index case, patient had gangrene of the small bowel segment and therefore, the use of mesh was avoided due to a higher risk of infection and rejection.

Four types of hiatus hernia have been described in literature [Table/Fig-6] [1]. A patient with a Type IV hiatus hernia may clinically present with heartburn, regurgitation, progressive dysphagia, chest pain and nausea/vomiting [15]. Atypical signs and symptoms include fatigue, severe anasarca due to mass effect, orthopnoea, postprandial GE reflux, hypoxemia, and aspiration pneumonia [16]. Rarely, a patient may present to the Emergency Department (ED) with complaint of a sharp retrosternal pain. Cardiac cause of pain must be ruled out with utmost urgency in such a case [17]. In index case, patient presented with dyspnoea, shortness of breath, and abdominal pain.

Management of a patient with type IV hiatus hernia depends on the severity of the disease, and condition of the herniated viscera. This may vary from a conservative approach at one end of the spectrum [17], to a procedure involving extensive resection of the necrosed herniated contents at the other end [15]. There are several important considerations while performing the surgical repair. Laparoscopic approach, in experienced hands, helps in better visualisation of the hiatus, allowing the dissection of the oesophagus and the hernial sac in the mediastinum under endoscopic vision, and an earlier postoperative recovery [18]. However, laparoscopic repairs have been found to be associated with remarkably higher recurrence rates compared to the open approach [19]. Irrespective of the approach, the first step is dissection of the hernial sac from the

mediastinal structures. This allows successful reduction of the hernia whilst avoiding an iatrogenic oesophageal injury. This step also reduces the risk of early recurrence. Full sac excision, though technically demanding, is recommended as it has been shown to reduce early recurrence. However, excision of sac and repair of large hernial defects increase the probability of injury to the vagus nerve, leading to gastroparesis [20]. In index case, the sac in the patient was fully excised.

It is also important to ensure tension free closure of the diaphragm. This reduces the risk of recurrence due to reopening of the defect and is accomplished with the help of a mesh in large defects. The mesh is used to cover the defect itself or to reinforce the crura. Mesh reinforcement of a large hiatal hernia is associated with decreased short-term recurrence. However, available literature lacks a consensus on recommendations for uniform usage of mesh. Complications associated with mesh repair, such as local erosion into the oesophagus and oesophageal stenosis, lead to higher dysphagia rates [20]. In index patient, the oesophageal hiatus was 7 cm in diameter and was relatively firm. Therefore, only suture cruroraphy was performed to avoid mesh-related complications. In case excess tension is anticipated across the diaphragm after repair, a relaxing incision may be given on the diaphragmatic crura. Typically, a fundoplication is done with a hiatus hernia repair, which helps not only in restricting any visceral transposition through the repaired defect, but also in strengthening the Lower Oesophageal Sphincter (LES) to prevent reflux disease [20]. However, a fundoplication was not deemed necessary in index patient as the length of the oesophagus was adequate.

No report in existing medical literature was found describing the presence of both obturator and type IV hiatus hernia in one patient. As evident from present report, both hernias can be managed by surgical repair during exploratory laparotomy. Exploration and reduction of contents followed by resection anastomosis or stoma creation (depending on the bowel condition), and surgical closure of the defect are the recommended steps for the repair of an obstructed obturator hernia. Reduction of contents, excision of redundant sac, tension free repair of the hiatal defect with or without mesh (as indicated) and vagal preservation constitute the key components of a type IV hiatal hernia repair.

## CONCLUSION(S)

When an elderly female presents with obstipation and no significant signs in abdomen, one should not hesitate in obtaining a CT scan immediately. Early and prompt diagnosis followed by timely surgical intervention is likely to ensure a favourable prognosis. However,

morbidity and mortality in cases presenting with strangulated obturator hernias alongside a type IV hiatal hernia remains high.

## Acknowledgement

The authors would like to thank Dr. Nitin Sood, Consultant Radiology for assistance with the radiological images.

**Consent:** Taken from the next of kin (husband).

## REFERENCES

- [1] Yeo CJ. Shackelford's Surgery of the Alimentary Tract. 8<sup>th</sup> ed. Philadelphia: Elsevier; c2019. Chapter 74, Internal Hernias: Congenital and Acquired; p. 280.
- [2] Igari K, Ochiai T, Aihara A, Kumagai Y, Iida M, Yamazaki S. Clinical presentation of obturator hernia and review of the literature. *Hernia*. 2010;14:409-13.
- [3] Thanapaisan C, Thanapaisal C. Sixty-one cases of obturator hernia in Chiangrai Regional Hospital: Retrospective study. *J Med Assoc Thai*. 2006;89:2081.
- [4] De Clercq L, Coenegrachts K, Feryn T, Van Couter A, Vandevoorde P, Verstraete K, et al. An elderly woman with obstructed obturator hernia: A less common variety of external abdominal hernia. *Journal Belge de Radiologie*. 2010;93(6):302.
- [5] Peter R, Indiran V, Kannan K, Maduraimuthu P, Varadarajan C. Rare case of obturator hernia in a patient with Marfan's syndrome. *Hernia*. 2014;18:439-42.
- [6] Sá NC, Silva VC, Carreiro PR, Matos Filho AS, Lombardi IA. Rare case of incarcerated obturator hernia: Case report and review of literature. *Int J Surg Case Rep*. 2017;37:157-60.
- [7] Yale SH, Tekiner H, Yale ES. Role of the signs of obturator hernia in clinical practice. *Hernia*. 2020;25(1):235-36.
- [8] Kammori M, Mafune KI, Hirashima T, Kawahara M, Hashimoto M, Ogawa T, et al. Forty-three cases of obturator hernia. *Am J Surg*. 2004;187:549-52.
- [9] Igari K, Ochiai T, Aihara A, Kumagai Y, Iida M, Yamazaki S. Clinical presentation of obturator hernia and review of the literature. *Hernia*. 2010;14(4):409-13.
- [10] Nishina M, Fujii C, Ogino R, Kobayashi R, Kohama A. Preoperative diagnosis of obturator hernia by computed tomography in six patients. *J Emerg Med*. 2001;20:277-80.
- [11] Chitrabalam TG, Christopher PJ, Sundaraj J, Selvamuthukumar S. Diagnostic difficulties in obturator hernia: A rare case presentation and review of literature. *BMJ Case Rep*. 2020;13:e235644.
- [12] Diab J, Badiani S, Berney CR. A decade review of emergency obturator hernia repairs. *ANZ J Surg*. 2021;91(7-8):1596-603.
- [13] Chan KV, Chan KO, Yau KW, Cheung MT. Surgical morbidity and mortality in obturator hernia: A 10-year retrospective risk factor evaluation. *Hernia*. 2014;18:387-92.
- [14] Shipkov CD, Uchikov AP, Grigoriadis E. The obturator hernia: Difficult to diagnose, easy to repair. *Hernia*. 2004;8:155-57.
- [15] Krause W, Roberts J, Garcia-Montilla RJ. Bowel in chest: Type IV hiatal hernia. *Clin Med Res*. 2016;14:93-96.
- [16] Patel S, Yarra S, Owji S, Benavidez JE, Nguyen QD. Minding the gap: Clinical manifestations of a rare type IV hiatal hernia. *Cureus*. 2020;12:e9275.
- [17] Khan MZ, Yousaf H, Dahiya DS, Wani F, Kichloo A. Chest pain: A relatively benign symptom of Type IV hiatal hernia. *Cureus*. 2020;12:e11459.
- [18] Oelschlager BK, Pellegrini CA, Hunter J, Soper N, Brunt M, Sheppard B, et al. Biologic prosthesis reduces recurrence after laparoscopic paraesophageal hernia repair: A multicenter, prospective, randomized trial. *Ann Surg*. 2006;244:481-90.
- [19] Hashemi M, Peters JH, DeMeester TR, Huprich JE, Quek M, Hagen JA, et al. Laparoscopic repair of large type III hiatal hernia: Objective follow up reveals high recurrence rate. *J Am Coll Surg*. 2000;190(5):553-60.
- [20] Kohn GP, Price RR, DeMeester DR, Zehetner J, Muensterer OJ, Awad Z, et al. Guidelines for the management of hernia. *Surg Endosc*. 2013;27:4409-28.

### PARTICULARS OF CONTRIBUTORS:

1. Junior Resident, Department of General Surgery, Maulana Azad Medical College and Lok Nayak Hospital, New Delhi, India.
2. Professor, Department of General Surgery, Maulana Azad Medical College and Lok Nayak Hospital, New Delhi, India.
3. Assistant Professor, Department of General Surgery, Maulana Azad Medical College and Lok Nayak Hospital, New Delhi, India.
4. Junior Resident, Department of General Surgery, Maulana Azad Medical College and Lok Nayak Hospital, New Delhi, India.

### NAME, ADDRESS, E-MAIL ID OF THE CORRESPONDING AUTHOR:

Dr. Manu Vats,  
Assistant Professor, Department of General Surgery, 2<sup>nd</sup> Floor, BL Taneja Block,  
Maulana Azad Medical College, 2, Bahadur Shah Zafar Marg, New Delhi-110002, India.  
E-mail: vatsmanu@gmail.com

### AUTHOR DECLARATION:

- Financial or Other Competing Interests: None
- Was informed consent obtained from the subjects involved in the study? Yes
- For any images presented appropriate consent has been obtained from the subjects. Yes

### PLAGIARISM CHECKING METHODS: [Jain H et al.]

- Plagiarism X-checker: Jan 28, 2022
- Manual Googling: Mar 20, 2022
- iThenticate Software: Mar 26, 2022 (5%)

### ETYMOLOGY: Author Origin

Date of Submission: **Jan 25, 2022**  
Date of Peer Review: **Mar 03, 2022**  
Date of Acceptance: **Mar 28, 2022**  
Date of Publishing: **May 01, 2022**