

# Paediatric Autoimmune Neuropsychiatric Disorders Associated with Streptococcal Infections (PANDAS): A Case Report

MONA SRIVASTAVA, GANESH SHANKAR, M.N.TRIPATHI

## ABSTRACT

Paediatric Autoimmune Neuropsychiatric Disorders Associated with Streptococcal Infections (PANDAS) is a unique syndrome which is associated with a recent infection which is caused by the

group A streptococcal haemolytic bacteria. A seeming dearth of cases being report from India, despite the high incidence of the infection in the country, is being highlighted in this case report.

**Key Words:** Paediatric Autoimmune Neuropsychiatric Disorders Associated with Streptococcal Infections (PANDAS), group A beta-haemolytic streptococci (GABHS), Anti streptolysin O titer (ASO).

## KEY MESSAGE

- Awareness regarding the sequel of the streptococcal infection has to be increased and a timely and adequate treatment of the infection needs to be emphasized.

## INTRODUCTION

Several studies have shown the role of immunological factors in the causation of Obsessive compulsive disorder (OCD)[1]. The most important support to the immunological hypothesis for OCD comes from the studies on Paediatric Autoimmune Neuropsychiatric Disorders Associated with Streptococcal Infections (PANDAS)[2]. Streptococcal infections, specifically the ones which are caused by the b-haemolytic Group A Streptococci, are a unique constellation of disorders which have been clubbed under a syndrome which has been named as PANDAS, and the various diagnostic criteriae are as per NIMH (National Institute of Mental Health) [2], which are shown in [Table/Fig 1]. Although b-haemolytic streptococcal infection is prevalent in India [3], not a single case has been reported from here [1], which classically fulfills the NIMH guidelines [2]. Since the constellation of the symptoms can be severely debilitating at times, it is important to be aware of the disorder in order to prevent it [4]. The few reports and the poor understanding of this condition need to be overcome. We report a case here, which fulfills all the criteriae of this unique disorder, with an aim to substantiate the existing database.

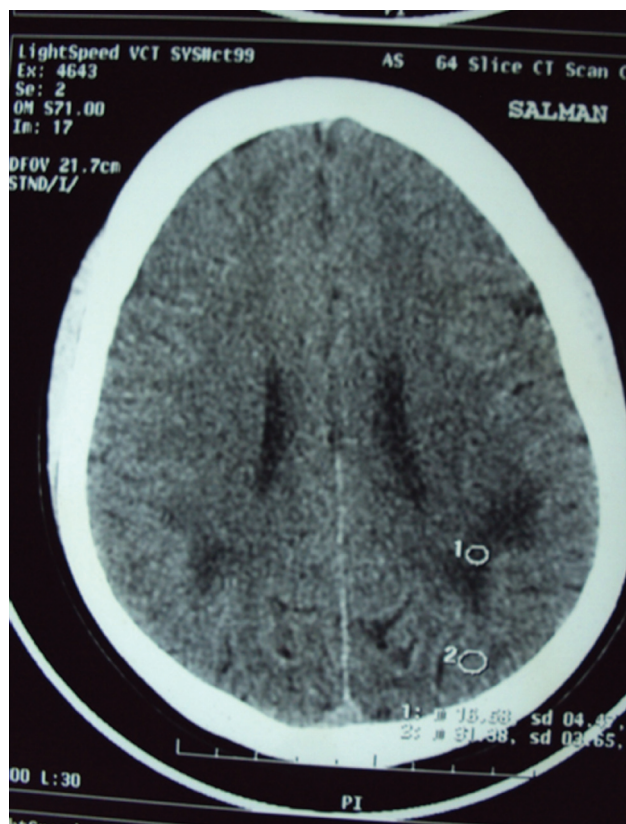
## CASE REPORT

The patient S, a 10 year-old muslim male, studying in the 4th standard, hailing from an urban area, presented to the outpatient psychiatric clinic of the university hospital with a sudden onset of motor and vocal tics along with obsessions regarding contamination and washing compulsions. At around 6 years of age, S had developed fever, cough, pain in the abdomen and breathlessness and the diagnosis of pneumonitis was made by the treating paediatrician. After the treatment, his general condition had improved, but it was noticed that the otherwise quite child had become very restless. Within two weeks following his discharge from the paediatric unit, S started having some complex movements. There was repeated

forceful closure of the eyes, followed by blinking, facial grimacing, head jerking, shoulder shrugging, coughing, hand rubbing and nose-rubbing which ended with a loud throat clearing and a clucking sound. The entire sequence of the movements which have been described above were monotonously repeated several times during the day ;however the movements ceased during sleep. His condition worsened with time, he started washing his hands excessively, took a lot of time and water for taking bath, his sleep and appetite decreased markedly and he became irregular in school. Over time, the sounds from his neck became very loud and started causing embarrassment to the patient. The patient has been taken for multiple consultations, without any improvement. The patient is unable to control his movements and on trying to do so, his tics returned with greater complexity, intensity, and frequency. He dropped school because of his illness. After about six months, there was a sudden decrease in all his symptoms and this prompted him to join school. Three months later, following a bout of cough and sore throat, the symptoms returned, with greater intensity. Several days later, the patient had an equally abrupt onset of obsessions and compulsions, involving ordering and arranging, contamination, and counting. He used to count the number of steps that he moved forward and then backwards and this made it tiring for him to move a couple of steps. A family member observed that the patient stood in one place for a long time and that he had to be pushed at times to move forward. For the past four years, his symptoms had been persisting, although there had been remissions in the severity of the symptoms. His family members sought various consultants and even took the help of several faith healers and visited sacred places for the recovery of the patient. The patient was referred for a psychiatric consultation about six months back and since then, he is under the care of the psychiatric team. Before beginning the treatment, the patient was investigated by a CT scan and an anti streptolysin

1. Presence of a tic disorder, obsessive-compulsive disorder, or both, as per criteria established in the DSM-IV
2. Pre pubertal onset of neuropsychiatric symptoms
3. History of sudden onset of symptoms, episodic course with abrupt symptom exacerbation interspersed with periods of partial or complete remission, or both
4. Evidence of a temporal association between onsets of the neuropsychiatric symptoms and infection with group A beta-haemolytic streptococci (GABHS)
5. Adventitious movements (e.g. motor hyperactivity and choreiform movements) may be present during symptom exacerbation

**[Table/Fig-1]:** Criteria for the diagnosis of pediatric autoimmune neuropsychiatric disorders (PANDAS)



**[Table/Fig-2]:** CT scan picture showing areas of demyelination labeled as 1 and 2

O (ASO) titer. The CT scan revealed areas of demyelination in the basal ganglia region and the ASO titers were found to be markedly raised to 300 units. A diagnosis of PANDAS was made and the management was started. He is receiving tab haloperidol in the dose of 5mg/day and tab fluoxetine in the dose of 40mg/day on an outpatient basis. He turned up for follow up at 3 week intervals and reported an improvement in his symptoms including the vocal tics, the motor tics and the obsessive features. These improvements were reflected in his enhanced social functioning, a better quality of life and good compliance to medication at six months of follow up. On follow up, he complained of fever with sore throat and an exacerbation in his symptoms. At that time, he was also given a course of azithromycin for one week, which gave him subsequent relief from the condition. The psychiatric medication was continued; the improvement in the condition was maintained.

## DISCUSSION

The case which is being described by us, is probably the first case of PANDAS, as the literature search reveals that only few cases have been reported [4,5] and that none of the cases could classically fit

into the stipulated diagnostic criteria [2]. In their review, Reddy et al., [1] reported that no case of PANDAS was documented from India. Andrade and Pfizer [5] reported a case that did not have a pre pubescent onset of symptoms and the tics were not well defined. The case which was described by Shankarnarayan and John [4] also had an adult onset of symptoms and clumsiness instead of the clear tics. On the contrary, our case fits the classical description which is laid down by the NIMH [2]. It has been suggested that in OCD, following an infection, the antibodies to the bacteria may make their way into the healthy brain and attack the basal ganglia, which could disrupt the normal brain [6]. A subgroup of children with OCD seemed to have their symptoms triggered or exacerbated by the group A beta haemolytic streptococcal infection (GABHS). The symptoms seemed to have been caused from the caudate swelling that occurred in these subjects because of an autoimmune reaction between the caudate tissue and the anti neuronal antibodies which were formed against GABHS [6]. This subtype of OCD which is called Paediatric Auto-immune Neuropsychiatric Disorders Associated with Streptococcal infection (PANDAS), is characterized by a sudden and dramatic onset or exacerbation of OCD or the tic symptoms and is associated with neurological findings, and a recent streptococcal infection [2]. There is no evidence of any specific time limit from the occurrence of the infection to the onset of the symptoms; at the most, a 'temporal' correlation has to be established [2]. The case which has been presented by us probably had a similar progress of events, as was evidenced by the demyelination which was found in the basal ganglia region in the CT scan, the association of the onset of the symptoms being preceded by a chest and throat infection. The infection which was caused by the group A streptococci, being the commonest infection in India, it may be the probable causative organism [3]. This was also validated by an increased ASO titer which was found on investigation. As was described in the diagnostic criteria, our case also had an abrupt onset and exacerbations which were associated with a relapse of the streptococcal infection. The PANDAS clinical course was characterized by a relapsing-remitting symptom pattern, with a significant psychiatric co morbidity accompanying the exacerbations. Emotional lability, separation anxiety, night time fears and bed time rituals, cognitive deficits, oppositional behaviours, and motoric hyperactivity are the particularly common symptoms which have been observed [7]. Our case also had significant co morbidity in the form of obsessions, compulsions, rituals and complex motor and vocal tics, along with significant features of anxiety and disturbances in sleep. The symptom onset in PANDAS is usually triggered by the GABHS infection; however, it has been well accepted that not all exacerbations are preceded by the group A beta-haemolytic streptococci (GABHS) infections, and that a prospective follow up is required to establish this association [2]. Our case had exacerbations during the course of the illness, but they were not always associated with the GABHS infection. It should however be mentioned here, that the symptoms cannot be a mere coincidence, as the CT scan changes along with the raised ASO titers and the drug responses, are corroborative of the occurrence of the syndrome. The aetiology of PANDAS is unknown; the possible causes include an autoimmune antibody or a streptococcal toxin [7]. PANDAS is by no means a confirmed diagnostic entity. However, Murphy et al. [8] recently helped in validating it as a disorder which was characterized by high streptococcal antibody titers. Episodic or saw tooth course symptom exacerbations were associated with elevations in the antibody titers. Our case had all the above features, though the temporal association of the symptom exacerbation with the raised

antibody titers was demonstrated only once.

We reported this case since it is important to keep this disorder in mind when treating children. The presence of the significant co morbidity can lead to a marked disability in terms of the academic performance and the social adjustments in these children and hence a timely intervention can be helpful [8]. Our case also lost important school years because of this illness. The lack of cases of PANDAS in the Indian context can be attributed to an inadequate awareness regarding this disorder and an infrequent liaison among the various specialties. A good cross referral between the paediatricians and the psychiatrists can serve in decreasing and eliminating the morbidity and the disability which are associated with this disease. It should also be emphasized here, that a seemingly innocuous infection of GABHS needs an optimal longitudinal management plan and follow-up.

## REFERENCES

[1] Reddy YCJ, Rao NP, Khanna S. An overview of Indian research in

- obsessive compulsive disorder. *Indian J Psychiatry* 2010;52:S200-9.
- [2] Swedo SE, Leonard HL, Garvey M, Pediatric autoimmune neuropsychiatric disorders associated with streptococcal infections: Clinical description of the first 50 cases. *Am J Psychiatry* 1998;155:264-71.
- [3] Nandi S, Kumar R, Ray P, Vohra H, Ganguly NK. Group A streptococcal sore throat in a periurban population of northern India: A one-year prospective study. *Bull World Health Organ* 2001;79:528-33.
- [4] Shankarnarayan A, John JK. Paediatric Autoimmune Neuropsychiatric Disorder Syndrome (PANDAS): A case report. *Natl Med J India* 2003;16(1):22-3.
- [5] Andrade C, Pfizer N. Sore throat and obsessions: A causal link?. *Indian J Psychiatry* 2006;48:130-1
- [6] Husby G, van de Rijn I, Zabriskie JB, Abidin ZH, Williams RC Jr. Antibodies reacting with the cytoplasm of the subthalamic and the caudate nuclei neurons in chorea and acute rheumatic fever. *J Exp Med* 1976;144:1094-110.
- [7] Bodner SM, Morshed SA, Peterson BS. The question of PANDAS in adults. *Biol Psychiatry* 2001;49:807-10.
- [8] Murphy ML, Pichichero ME. Prospective identification and treatment of children with paediatric autoimmune neuro-psychiatric disorder associated with Group A streptococcal infection (PANDAS). *Arch Pediatr Adolesc Med* 2002;156:356-61

### AUTHOR(S):

1. Dr. Mona Srivastava
2. Dr. Ganesh Shankar
3. Dr. M.N. Tripathi

### PARTICULARS OF CONTRIBUTORS:

1. M.D., Assistant Professor, Department of Psychiatry, Institute of Medical Sciences, Banaras Hindu University, Varanasi, India. 221005
2. MBBS, Second year Junior Resident, Department of Psychiatry, Institute of Medical Sciences Banaras Hindu University, Varanasi, India. 221005
3. M.D, Senior Resident, Department of Psychiatry, Institute of Medical Sciences, Banaras Hindu University, Varanasi, India. 221005

### NAME, ADDRESS, TELEPHONE, E-MAIL ID OF THE CORRESPONDING AUTHOR:

Dr. Mona Srivastava  
36/2HIG Kabir Nagar Colony,  
Durgakund, Varanasi. (UP) 221005, India  
Phone : 09336910619  
E mail : drmonasrivastava@gmail.com

### DECLARATION ON COMPETING INTERESTS:

No conflicting Interests.

Date of Submission: Jul 14, 2011  
Date of per review: Aug 29, 2011  
Date of acceptance: Sep 11, 2011  
Date of Publishing: Nov 11, 2011