

Acute Kidney Injury as an Initial Presentation in Mantle Cell Lymphoma- A Rare Case Report

ARNAV KR ROYCHOUDHURY¹, MEENAKSHI SWAIN², SWARNALATA GOWRISHANKAR³,
RAJASEKARA CHAKRAVARTHY⁴, NIDHI BANSAL⁵



ABSTRACT

Mantle Cell Lymphoma (MCL) is a rare aggressive lymphoid neoplasm accounting for 3-7% of all Non Hodgkin Lymphomas (NHL). Kidney involvement in MCL is rarely reported in biopsies from living patients, being caused by direct lymphoid infiltration. Only 19 cases have been documented of Acute Kidney Injury (AKI) with lymphomatous infiltration. This case report is of a 50-year-old male who presented with AKI and was found to have a MCL infiltrating the kidneys.

Keywords: Kidney infiltration, Lymphoid neoplasm, Non Hodgkin lymphomas

CASE REPORT

A 50-year-old male, presented with chief complaints of weight loss and splenomegaly and on clinical examination and investigations, it was diagnosed as chronic lymphocytic leukaemia with rapidly worsening renal function and AKI. There was an increase in creatinine from 1.9 mg/dL to 5.8 mg/dL with proteinuria (0.5 g/L). Urine investigations revealed haematuria with red blood cell count of 40-50/high power field (hpf) and white blood cell count of 0-5/hpf. Blood for t (11;14) by Fluorescence In-situ Hybridisation (FISH) was negative initially but turned out to be positive later in another laboratory and Immunoglobulin Variable Heavy (IgVH) chain gene was found to be hypermutated.

Chest radiograph indicated a widened shadow of the right side of the mediastinum. No previous history of any medical disease or any surgical intervention was recorded. Positron Emission Tomography (PET)/Computed Tomography (CT) showed moderately active B axillary/retroperitoneal/B iliac/mesenteric and inguinal lymph nodes.

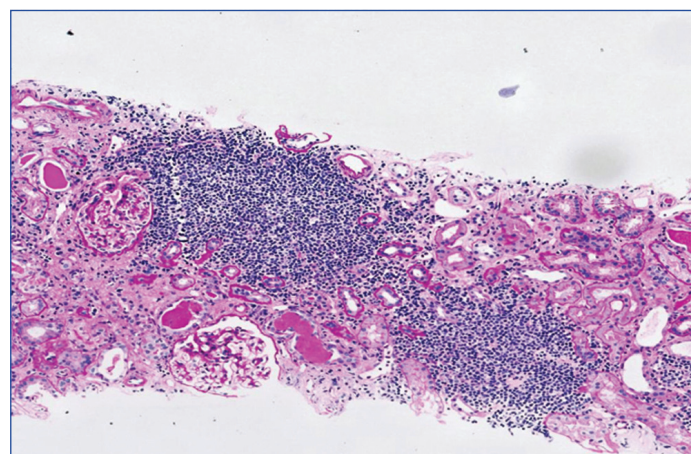
The option of aggressive chemoimmunotherapy with Rituximab, Cyclophosphamide, Hydroxidaunorubicin hydrochloride, vincristine (Oncovin) and Prednisolone/Rituximab, Dexamethasone, cytarabine and cisplatin (R-CHOP/R-DHAP) followed by autologous Peripheral Blood Stem Cell Transplantation (PBSCT) and then rituximab maintenance was advised. Rituximab was given in dose of 375 mg/m² on day prior to initiation of 1st cycle of chemotherapy followed by 500 mg/m² on day 1 of cycle 2-6 (every 28 days). During treatment, progressive deterioration of renal function was found. At admission, the patient did not report any other ailments. Additional diagnostics revealed signs of progressive multiorgan failure. There was no evidence of Antinuclear Antibody (ANA), Perinuclear Antineutrophil Cytoplasmic Antibodies (p-ANCA) and Cytoplasmic Antineutrophil Cytoplasmic Antibodies (c-ANCA) antibodies. Ultrasound abdomen examination showed enlargement of the kidneys (left kidney length 141 mm, right kidney 134 mm) with signs of parenchymal swelling.

Bone marrow aspiration biopsy was done that revealed hypercellular marrow with suppressed trilineage haematopoiesis, lymphocytosis and mild plasmacytosis. Advised to rule out chronic lymphoproliferative disorder. A biopsy of the kidney was done for histopathological evaluation. Renal core biopsies measuring 0.5 cm and 0.3 cm were submitted for Light Microscopic (LM) and Immunofluorescence (IF) studies, respectively. The LM samples were embedded in paraffin, sectioned and stained with Haematoxylin and Eosin (H&E), Periodic Acid-Schiff (PAS), Masson Trichrome (MT) and Periodic

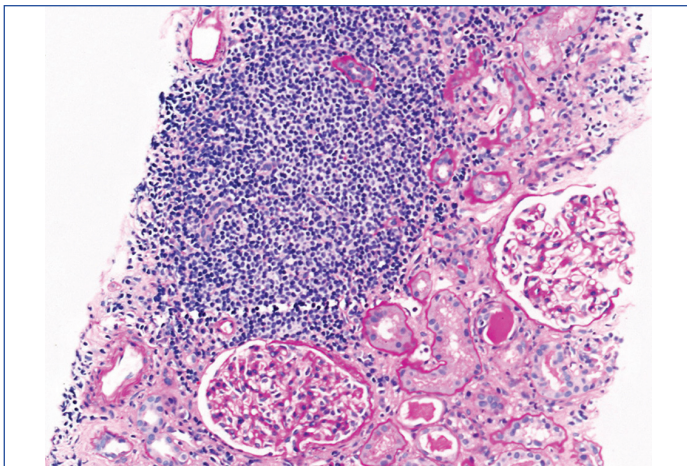
Silver Methenamine (PASM) staining. For immunofluorescence, the samples were sectioned at 3 microns using a cryostat and stained with a panel of Fluorescein Isothiocyanate (FITC)-conjugated rabbit antihuman antibodies to Immunoglobulin G (IgG), IgM, IgA, C3C, C1q, Kappa and Lambda light chains. The intensity of immunofluorescence staining was semi-quantitatively scored on a scale of 0 to 4+. Immunophenotyping was performed using immunoperoxidase and avidin-biotin techniques. The follow-up of the patient was done recently with a serum creatinine of 2 mg/dL and normal renal functions.

Microscopic examination: The kidney biopsy showed a core of renal cortical tissue with 11 glomeruli and 2 arteries. The glomeruli were normal in cellularity with no mesangial widening, basement membrane thickening, segmental lesions or crescents. The tubules showed evidence of tubular injury with many being dilated and contained hyaline, granular, red cell and pigment casts. Tubular atrophy was present in 20-25% of the cortical tissue sampled. The interstitium showed moderately dense nodular aggregates of lymphoid cells having a monotonous appearance as shown in [Table/Fig-1-4]. Occasional plasma cells were also present. These features were suspicious of a lymphoma especially in view of the clinical findings.

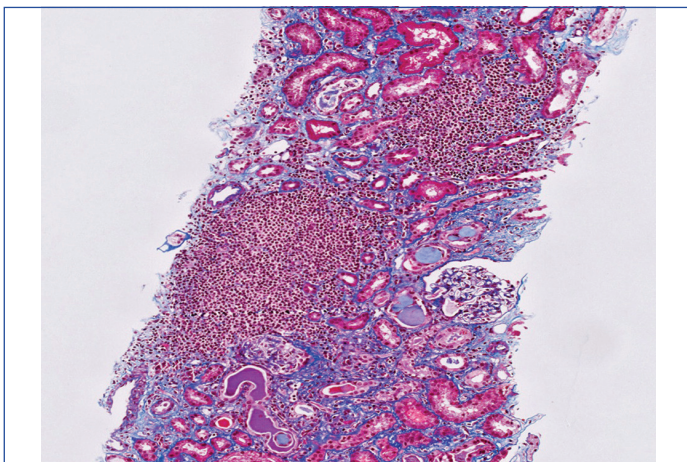
Immunofluorescence study revealed six glomeruli with minimal, mesangial coarse granular deposits of C1q and C3c along with insignificant deposits of IgG [Table/Fig-5,6].



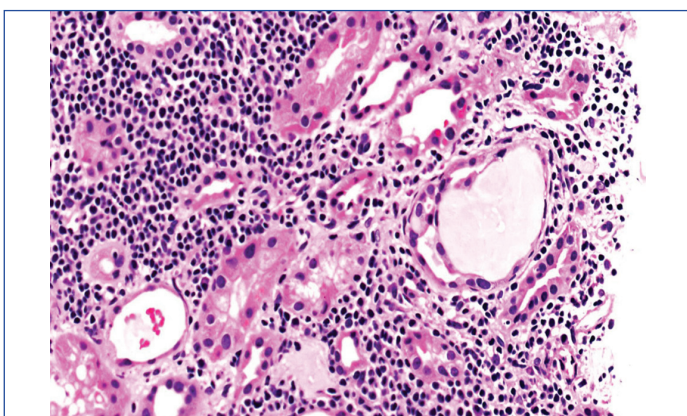
[Table/Fig-1]: PAS (10x) magnification showing normal glomeruli with nodular aggregates of monotonous lymphoid cell population.



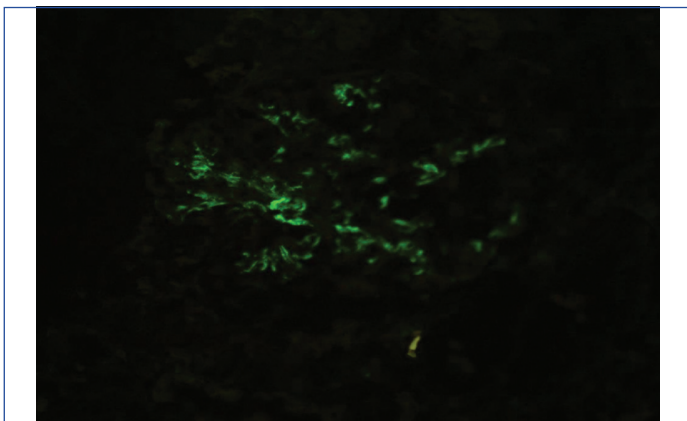
[Table/Fig-2]: H&E (20x) magnification showing normal glomeruli with nodular aggregates of monotonous lymphoid cell population.



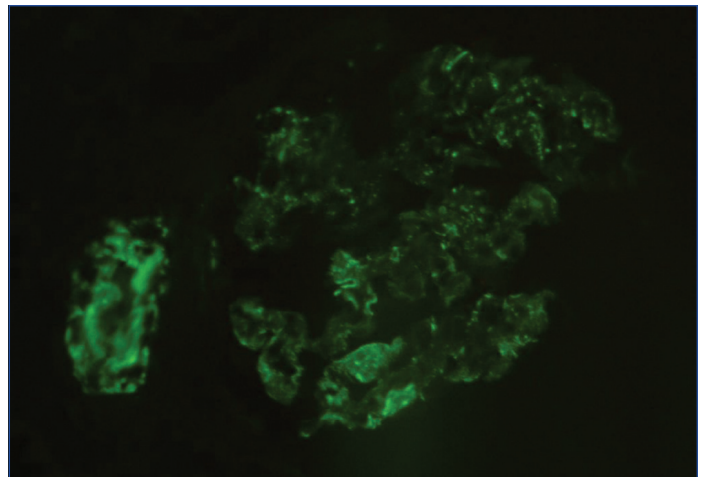
[Table/Fig-3]: MT (10x) magnification showing normal glomeruli with nodular aggregates of monotonous lymphoid cell population.



[Table/Fig-4]: PAS (40x) magnification showing tubular injury and interstitial inflammation.



[Table/Fig-5]: Immunofluorescence with C1q showing minimal, mesangial coarse granular deposits.



[Table/Fig-6]: Immunofluorescence with c3c showing minimal, mesangial coarse granular deposits.

Immunohistochemistry revealed strong cytoplasmic membrane positivity with Cluster of Differentiation 20 (CD20), CD5 and nuclear positivity for cyclin D1 in the infiltrating lymphoid cells. MIB-1 index averaged 30%. Few of the small reactive lymphocytes showed positivity for CD3. CD23 was negative. The morphology and immunoprofile was that of a MCL invading renal parenchyma associated with significant acute tubular injury.

Immediately afterwards chemotherapy was started with R-CHOP regimen. Rituximab infusion was started in the 1st cycle which caused infusion reaction but was well-tolerated in the rest of the cycles. The patient was followed for every 28 days for next cycles.

DISCUSSION

The Acute Kidney Injury (AKI) is one of the complications of malignancies with very few published cases in literature and is limited to single case reports [1,2]. Various studies have shown a wide range in the incidence of AKI in various cancers ranging from 12-49% [3]. AKI with lymphomatous infiltration is extremely rare with only 19 cases being documented in world literature [4]. Cancer patients can be immunocompromised due to a plethora of underlying factors, commonest being chemo-radiotherapy leading to impairment of normal leucocyte function. MCL is a rare aggressive lymphoid neoplasm accounting for 3-7% of all NHL [5]. Lymphomatous infiltration of the kidney can also cause AKI and a renal biopsy is often adequate for making a diagnosis with the use of appropriate immunohistochemical stains. This immunologic dysregulation leads to sepsis which causes unregulated production of proinflammatory cytokines ultimately causing dysfunctional renal perfusion and irreversibly causing AKI [4,6].

Da'as N et al., studied in detail the renal involvement and renal manifestations in NHL and chronic lymphocytic leukaemia in 700 patients and showed that only upto 10% of patients with NHL and lymphocytic leukaemia have kidney injury. Since the patterns of glomerular injury are so diverse and heterogenous in patients with lymphomas, it poses a diagnostic challenge to the clinicians. Chronic Lymphocytic Leukaemia (CLL) infiltrates the kidney interstitium in approximately 90% of patients seen at autopsy but clinical kidney disease is very uncommon [7].

MCL is a rare aggressive lymphoid neoplasm occurring in about 3-7% of NHL in United States and Europe and affects males more than females [5,8]. They have a characteristic morphology and distinctive cytogenetic abnormality, t(11;14)(q13;q32) [9,10]. Cell cycle regulator protein cyclin D1 has been found to be overexpressed in around 70% of cases which ultimately leads to dysregulation of the G1-S phase of the normal cell cycle [10,11]. Most commonly diagnosed in their late 60s, the most common sites of extranodal manifestations of MCL are gastrointestinal tract followed by bone marrow, liver, spleen and Waldeyers ring. Most frequent NHL

infiltrating kidneys are extranodal marginal zone lymphoma that is MALToma (Mucosa Associated Lymphoid Tissue lymphoma), Diffuse Large B-Cell Lymphoma (DLBCL) and Burkitt's lymphomas [12]. Involvement of the genitourinary tract by lymphoma occurs rarely, its incidence being estimated to be about 5% with renal involvement being most common and occurring in approximately 37% of cases.

MCL typically expresses B-cell antigens such as CD19, CD20, Paired Box Protein 5 (PAX5), CD5, Cyclin D1 B-cell Lymphoma 1 (BCL1), BCL2, CD43 and is negative for CD10 and CD23. Ki-67 is one of the important prognostic indicators and increases in aggressive variants of MCL. Most cases of MCL are moderately to strongly positive for cyclin D1 with rare cases of cyclin D1 negativity. In these cases, SOX11 could be used and is highly specific for MCL [13].

WHO classification has divided MCL into two aggressive variants [12,14,15].

- Blastoid variant which is primarily composed of cells closely resembling lymphocytes with dispersed chromatin and high mitotic rate.
- Pleomorphic variant which is composed of pleomorphic cells with oval to irregular nuclei with prominent nucleoli and pale cytoplasm.

Da'as N et al., in his pioneering work found that NHL is a rare cause of acute renal failure (9.5%) [7]. Also, infiltration of renal parenchyma by lymphoma cells is very rare and is observed in only about 1% of cases. Most often, renal lymphoid infiltration is asymptomatic, but sometimes it may also cause acute tubulointerstitial nephritis. So far, eight cases of kidney impairment due to MCL have been described; four of them presenting with proliferative Glomerulonephritis (GN), one Focal Segmental Glomerulosclerosis (FSGS), two renal MCL infiltration with AKI, and the last, AKI due to acute tubulointerstitial nephritis [7,16-19]. Also, it has been found that untreated renal infiltration with MCL may be the reason for tubulointerstitial inflammation and AKI [18].

CONCLUSION(S)

Sepsis has been associated with the development of AKI in malignancies. Lymphomatous infiltration of the kidney can also cause AKI and this case report shows the importance of the renal biopsy as a useful diagnostic tool in case of kidney impairment in such patients. It is felt that identification of these multifactorial predictors and early intervention can help prevent and reduce the severity of AKI. This case is being reported for its rarity and to emphasise the importance of the renal biopsy as an extremely useful diagnostic tool in case of kidney impairment due to a lymphomatous infiltrate.

REFERENCES

- Darmon M, Ciroidi M, Thiery G, Schlemmer B, Azoulay E. Clinical review: Specific aspects of acute renal failure in cancer patients. *Critical Care*. 2006;10(2):211.
- Evison JM, Rickenbacher P, Ritz R, Gratwohl A, Haberthur C, Elsasser S, et al. Intensive care unit admission in patients with haematological disease: Incidence, outcome and prognostic factors. *Swiss Medical Weekly*. 2001;131(47-48):681-86.
- Lanore JJ, Brunet F, Pochard F, Bellivier F, Dhainaut JF, Vaxelaire JF, et al. Hemodialysis for acute renal failure in patients with hematologic malignancies. *Critical Care Medicine*. 1991;19(3):346-51.
- Al-Salam S, Shaaban A, Alketbi M, Haq NU, Abouchacra S. Acute kidney injury secondary to renal large B-cell lymphoma: Role of early renal biopsy. *International Urology and Nephrology*. 2011;43(1):237-40.
- Sant M, Allemanni C, Tereanu C, De Angelis R, Capocaccia R, Visser O, et al. Incidence of hematologic malignancies in Europe by morphologic subtype: Results of the HAEMACARE project. *Blood*. 2010;116:3724-34.
- Alkhunaizi AM, Daabil RA, Dawamneh MF. Acute kidney injury secondary to lymphomatous infiltration and the role of kidney biopsy. *Saudi Medical Journal*. 2008;29(12):1808-10.
- Da'as N, Polliack A, Cohen Y, Amir G, Darmon D, Kleinman Y, et al. Kidney involvement and renal manifestations in non-Hodgkin's lymphoma and lymphocytic leukaemia: A retrospective study in 700 patients. *Eur J Haematol*. 2001;67:158-64.
- Zhou Y, Wang H, Fang W, Romaguer JE, Zhang Y, Delasalle KB, et al. Incidence trends of mantle cell lymphoma in the United States between 1992 and 2004. *Cancer*. 2008;113:791-98.
- Li JY, Gaillard F, Moreau A, Harousseau JL, Laboisie C, Milpied N, et al. Detection of translocation t(11;14)(q13;q32) in mantle cell lymphoma by fluorescence in situ hybridisation. *Am J Pathol*. 1999;154:1449-52.
- de Boer CJ, Schuurin E, Dreef E, Peters G, Bartek J, Kluin PM, et al. Cyclin D1 protein analysis in the diagnosis of mantle cell lymphoma. *Blood*. 1995;86:2715-23.
- Etta PK, Rao MV, Reddy S, Gowrishankar S, Agarwal N. Lymphomatous interstitial nephritis coexistent with paraneoplastic crescentic membranoproliferative glomerulonephritis in a case of mantle cell lymphoma. *Ind J Nephrol*. 2020;30(3):192-95.
- Schniederjan SD, Osunkoya AO. Lymphoid neoplasms of the urinary tract and male genital organs: A clinicopathological study of 40 cases. *Mod Pathol*. 2009;22:1057-65.
- Mozos A, Royo C, Hartmann E, Jong DD, Baró C, Valera A, et al. SOX11 expression is highly specific for mantle cell lymphoma and identifies the cyclin D1-negative subtype. *Haematologica*. 2009;94:1555-62.
- Swerdlow SH, Campo E, Pileri SA, Harris NL, Stein H, Siebert R, et al. The 2016 revision of the World Health Organization (WHO) classification of lymphoid neoplasms. *Blood*. 2016;1:569-643.
- Kazeminezhad B, Gharib A, Asadi Z. Primary pleomorphic mantle cell lymphoma of kidney: A case report. *Int J Cancer Manag*. 2018;11(1):e10203. Doi:10.5812/ijcm.10203.
- Sellin L, Friedl C, Klein, Waldherr R, Christian RL, Weiner SM. Acute renal failure due to a malignant lymphoma infiltration uncovered by renal biopsy. *Nephrol Dial Transplant*. 2004;19:2657-60.
- Davies J, Healey DA, Wood KM, Jones K, Kanagasundaram NS. Acute renal failure due to mantle cell lymphoma- A case report and discussion of the literature. *Clin Nephrol*. 2007;67:394-96.
- Colak N, Dede F, Canbakan B, Odabas AR, Akyurek N. Acute tubulointerstitial nephritis associated with mantle cell lymphoma presented as acute renal failure. *Nephrology*. 2007;12:107-08.
- Khalil MA, Latif H, Rehman A, Kashif WU, Awan S, Khalil Z, et al. Acute kidney injury in lymphoma: A single centre experience. *Int J Nephrol*. 2014;2014:272961.

PARTICULARS OF CONTRIBUTORS:

- Associate Professor, Department of Pathology, AIMSR, Bathinda, Punjab, India.
- Senior Consultant, Department of Histopathology, Apollo Hospitals, Hyderabad, Telangana, India.
- Senior Consultant, Department of Histopathology, Apollo Hospitals, Hyderabad, Telangana, India.
- Consultant, Department of Nephrology, Star Hospitals, Hyderabad, Telangana, India.
- Assistant Professor, Department of Immunohematology and Blood Transfusion, AIMSR, Bathinda, Punjab, India.

NAME, ADDRESS, E-MAIL ID OF THE CORRESPONDING AUTHOR:

Dr. Arnav KR Roychoudhury,
Associate Professor, Department of Pathology, Adesh Institute of Medical Sciences and Research, Bathinda-151101, Punjab, India.
E-mail: drarnav2007@gmail.com

PLAGIARISM CHECKING METHODS: [Jain H et al.]

- Plagiarism X-checker: Oct 04, 2021
- Manual Googling: Feb 22, 2022
- iThenticate Software: Apr 02, 2022 (18%)

ETYMOLOGY: Author Origin

AUTHOR DECLARATION:

- Financial or Other Competing Interests: None
- Was informed consent obtained from the subjects involved in the study? Yes
- For any images presented appropriate consent has been obtained from the subjects. Yes

Date of Submission: **Oct 02, 2021**
Date of Peer Review: **Nov 23, 2021**
Date of Acceptance: **Mar 19, 2022**
Date of Publishing: **May 01, 2022**