

Ochrobactrum intermedium Bacteraemia in COVID-19 Positive Patients: Case Report of Rare Co-infection from Northern India

TASNEEM SIDDIQUI¹, RAFAT SHAMIM², SANGRAM SINGH PATEL³, CHINMOY SAHU⁴, MITRA KAR⁵

ABSTRACT

Ochrobactrum intermedium (*O. intermedium*) is a novel emerging gram negative bacillus infecting immunocompromised hosts. It is known for its multidrug resistance and to distinguish it from other species of *Ochrobactrum* genus by conventional methods, is often difficult. Here, authors report two unusual and interesting cases of bacterial infection due to *O. intermedium* in a 28-year-old female and 46-year-old male having Coronavirus Disease-2019 (COVID-19) infection. Rapid identification by Matrix Assisted Laser Desorption/Ionisation-Time Of Flight (MALDI-TOF) mass spectrometry and patient's treatment guided by antibiotic sensitivity yielded in favourable outcome. Present report describes clinical and microbiological characteristics of this rare pathogen and also highlights the need of automated methods for proper identification of such opportunistic pathogens and their unique antibiotic susceptibility profiles.

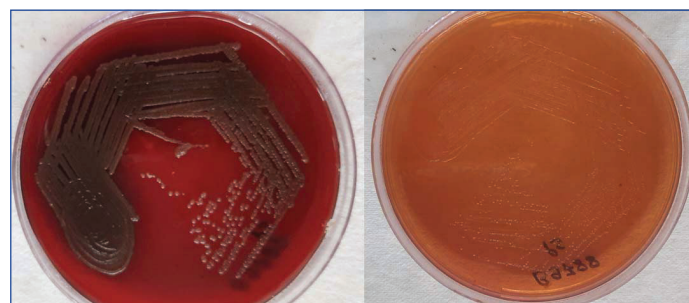
Keywords: Antibiotic sensitivity, Bacillus, Coronavirus disease 2019

CASE REPORT

Case 1

A 28-year-old female with type 2 diabetes presented with low grade fever, cough with productive and exertional breathlessness for four days and a positive Reverse Transcription Polymerase Chain Reaction (RT-PCR) for Severe Acute Respiratory Syndrome Coronavirus 2 (SARS-CoV-2) and was admitted in the isolation ward of the centre. X-ray chest and High-Resolution Computed Tomography (HRCT) [Table/Fig-1] (patient-1) thorax was done which showed evidence of COVID-19 pneumonia with severity scoring of 11/25, so the patient was started on oxygen supplementation (16 L/Min) by non rebreathing mask along with antibiotics, remdesivir and injectable dexamethasone. Due to worsening of sugar control (fasting >250 mg/dL) with deterioration of sensorium and breathlessness, the patient had to be intubated subsequently. She was found having Diabetic Ketoacidosis (DKA) when history revealed and insulin infusion and fluids were started. The patient developed signs of sepsis on the 10th day, hence, paired blood culture were sent for microbiological study in BACTEC bottles (aerobic and anaerobic). The blood culture bottles flagged positive after 24 hours of incubation and gram negative bacilli was seen with direct gram stain which was then subcultured on blood and MacConkey agar plates [Table/Fig-2]. Non lactose fermenting colonies grew on culture which were catalase and oxidase positive and were identified as *Ochrobactrum intermedium* by MALDI-TOF mass spectrometry. Antibiotic Susceptibility Testing (AST) of the

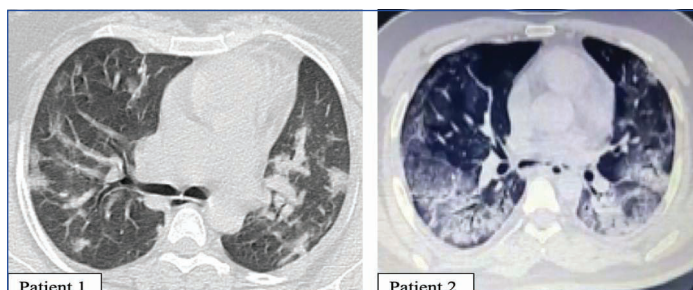
isolate performed by VITEK 2 system (Biomerieux, France) showed it to be susceptible to ciprofloxacin, levofloxacin, cotrimoxazole, aminoglycosides, minocycline and carbapenems but was resistant to penicillin, cephalosporins and colistin [Table/Fig-3]. Repeat blood cultures also isolated *O. intermedium* with similar antibiogram. She was treated with amikacin and meropenem for next 14 days following and her repeat blood cultures became sterile and patient was then discharged in stable condition. On 7th day of follow-up in outpatient department, patient was healthy with controlled blood sugar levels.



[Table/Fig-2]: Blood agar and MacConkey agar plates showing growth of *O. intermedium*.

Case 2

A 46-year-old male presented with the complaints of low grade fever, cough with productive sputum and exertional breathlessness for 15 days with a positive RT-PCR for SARS-CoV-2. He was admitted in the isolation ward of the centre. His SpO₂ (oxygen saturation) was around 95% so he was started on medications like azithromycin, paracetamol and antihistaminic. In spite of the ongoing treatment, his symptoms worsened over the next two days. Routine blood investigations revealed: Haemoglobin (11 g/dL), blood sugar (HbA1c=6.2%, prediabetic), lymphopenia (600 cells/ μ L), and raised C-reactive protein (CRP=10 mg/dL) and procalcitonin levels (>2 mg/dL). Radiological workup was planned on the same day and a HRCT revealed ground-glass opacities on both the lung fields [Table/Fig-1], patient-2). The patient was diagnosed as a case of COVID-19 pneumonia. Steroids and low molecular weight heparin was added to the treatment regimen with regular sugar monitoring. Over the next four days, the patient clinically deteriorated and the SpO₂



[Table/Fig-1]: High-resolution CT (HRCT) lung showing ground glass opacities in both the coronavirus disease (COVID-19) positive patients.

| Antibiotics | Case 1 MIC (µg/mL) | Case 2 MIC (µg/mL) |
|-------------------------------|--------------------|--------------------|
| Amikacin | ≤4 (S) | ≤4 (S) |
| Aztreonam | ≥64 (R) | ≥64 (R) |
| Cefepime | ≥64 (R) | ≥64 (R) |
| Ceftazidime | ≥64 (R) | ≥64 (R) |
| Ciprofloxacin | 0.5 (S) | 1 (S) |
| Colistin | ≥16 (R) | ≥16 (R) |
| Gentamicin | 8 (S) | 4 (S) |
| Imipenem | 1 (S) | ≤1 (S) |
| Levofloxacin | 0.5 (S) | 0.5 (S) |
| Meropenem | ≤1 (S) | ≤1 (S) |
| Minocycline | ≤1 (S) | ≤1 (S) |
| Cefoperazone/Salbutactam | ≥64 (R) | ≥16 (R) |
| Piperacillin/Tazobactam | ≥128 (R) | ≥128 (R) |
| Ticarcillin/Clavulanic acid | ≥128 (R) | ≥128 (R) |
| Trimethoprim/sulfamethoxazole | ≤20 (S) | ≤2 (S) |

[Table/Fig-3]: Antimicrobial susceptibilities of isolates.
MIC: Minimum inhibitory concentration; S: Sensitive; R: Resistant

(oxygen saturation) dropped to 85% with room air, so, the patient was subsequently started on oxygen with nasal cannula. Various biomarkers including CRP (96 mg/dL), lactate dehydrogenase (LDH=360 U/L), D-dimers (>1), and ferritin levels (1224 ng/mL) were increased significantly. On the 12th day, the patient started to show signs of sepsis and hence, blood culture was sent to the microbiology laboratory in a pair of BACTEC bottles. Microbiological identification and AST were done similar to case 1 [Table/Fig.-3]. Final identification was *O. intermedium* with similar AST as case 1. Repeat blood cultures showed growth of *O. intermedium* with similar antibiogram. After treatment with amikacin and imipenem for 10 days, repeat blood cultures became sterile. The patient was discharged in stable condition. On 8th day of follow-up visit in outpatient department, the patient was healthy and maintaining SpO₂ (oxygen saturation) of around 98%.

DISCUSSION

Ochrobactrum spp. is a gram negative, non lactose fermenting, aerobic bacilli belonging to the Brucellaceae family [1]. Other than genus *Ochrobactrum*, mainly three species, have been isolated and identified from the respiratory and blood samples (*O. anthropi*, *O. intermedium*, and *O. pseudointermedium*). *O. intermedium* is a novel emerging opportunistic nosocomial pathogen which is often difficult to differentiate from other *Ochrobactrum* spp. by conventional methods and has been rarely reported in the literature [2]. Its treatment is challenging as it is notorious for its multidrug resistance [3].

The COVID-19 pandemic has led to the emergence of bacterial co-infections in these hospitalised patients as these patients were on immunosuppressive agents like steroids. As per report from Washington DC, United States this bacterial co-infection rate was 4.8% [4]. Lansbury L et al., in their meta-analysis, reported a bacterial co-infection rate of around 6.8% in hospitalised COVID-19 cases [5]. Gram-negative bacilli found in the majority in these co-infection groups [4,5]. However, there are very few case reports of *O. intermedium* bacteraemia in literature [3]. First case of *O. intermedium* liver abscess associated with bacteraemia was reported by Möller LV et al., in 1999 in patient with post liver transplantation who was successfully treated with imipenem and aminoglycosides [6]. Later nine more cases have been reported worldwide till date [3]. Infections by *O. intermedium* in immunocompromised cases give rise to

liver abscess, infective endocarditis and prostatic abscess [3]. However, there were two cases reporting that *O. intermedium* caused endophthalmitis and pelvic abscess in immunocompetent hosts [3]. Of the nine cases, eight patients were male and five patients had bacteraemia, two of whom were related with catheters [3]. This was the first case report of bacteraemia by *O. intermedium* in COVID-19 pneumonia patient. The isolation of these isolates could be because both patients had COVID-19 pneumonia for which they were receiving steroids and first patient had uncontrolled diabetes and second patient was in a prediabetic stage so chance of bacterial co-infection was high in index patients. Biochemicals that are commonly used, are not able to differentiate *O. intermedium* from other *Ochrobactrum* species but it can be accurately identified by molecular methods such as 16S Recombinant Deoxyribose Nucleic Acid (rDNA) gene sequencing, MALDI-TOF mass spectrometry and recA-PCR Restriction Fragment Length Polymorphism (RFLP). Although 16S rDNA gene sequencing is considered as the gold standard method for speciation but have high cost and lack of availability. MALDI-TOF is used alternatively to gene sequencing exhibiting reliable tool in identification of isolates [7-9]. In present study, isolates were promptly identified with the MALDI-TOF MS. It is resistant to multiple families of antibiotics such as β-lactam including penicillins, cephalosporins, and sometimes carbapenems, hence treatment is challenging but maximum isolates of *O. intermedium* are susceptible to carbapenems, aminoglycosides, trimethoprim-sulfamethoxazole and fluoroquinolones [6,8,10-12]. In present study, both isolates were susceptible to fluoroquinolones, cotrimoxazole, aminoglycosides, minocycline and carbapenems but was resistant to penicillin, cephalosporins and colistin. As per AST, both the patients were treated successfully with carbapenem and aminoglycosides.

Informed consent was obtained from both the patient regarding the publication of images and clinical information in the journal.

CONCLUSION(S)

Here, the first case of bacteraemia by *O. intermedium* in COVID-19 pneumonia patients were reported. MALDI-TOF mass spectrometry could be helpful in rapid identification of *O. intermedium*. Rapid diagnosis with timely management is a necessary to clear infection caused by this multidrug resistant pathogen.

REFERENCES

- [1] Mudshingkar SS, Chore AC, Palewar MS, Doha VB, Kigali AS. *Ochrobactrum anthropi*: An unusual pathogen: Are we missing them. Indian J Med Microbiol 2013;31:306-08.
- [2] Wu W, Jiang Y, Zhou W, Liu X, Kuang L. The first case of *Ochrobactrum intermedium* bacteremia in a pediatric patient with malignant tumor. BMC Infect Dis. 2021;21(1):1252.
- [3] Aujoulat F, Romano-Bertrand S, Masnou A, Marchandin H, Jumas-Bilak E. Niches, population structure and genome reduction in *Ochrobactrum intermedium*: Clues to technology-driven emergence of pathogens. PLoS ONE. 2014;9(1):e83376.
- [4] Arentz M, Yim E, Klaff L, Lokhandwala S, Riedo FX, Chong M, et al. Characteristics and outcomes of 21 critically ill patients with COVID-19 in Washington State. JAMA. 2020;323(16):1612-14.
- [5] Lansbury L, Lim B, Baskaran V, Lim WS. Co-infections in people with COVID-19: A systematic review and meta-analysis. J Infect. 2020;81(2):266-75.
- [6] Möller LV, Arends JP, Harmsen HJ, Talens A, Terpstra P, Slooff MJ. *Ochrobactrum intermedium* infection after liver transplantation. J Clin Microbiol. 1999;37:241-44.
- [7] Rodríguez-Villodres Á, Cuevas Palomino Á, Gómez Gómez MJ. Usefulness of MALDI-TOF mass spectrometry in infections by infrequent microorganisms such as *Ochrobactrum intermedium*. Med Clin (Barc). 2016;147:277-78.
- [8] Ryan MP, Pembroke JT. The genus *Ochrobactrum* as major opportunistic pathogens. Microorganisms. 2020;8:1797.
- [9] Kämpfer P, Citron DM, Goldstein EJC, Scholz HC. Difficulty in the identification and differentiation of clinically relevant *Ochrobactrum* species. J Med Microbiol. 2007;56:1571-73.
- [10] Appelbaum PC, Campbell DB. Pancreatic abscess associated with *Achromobacter* group Vd biovar 1. J Clin Microbiol. 1980;12:282-83.

- [11] Cieslak TJ, Drabick CJ, Robb ML. Pyogenic infections due to *Ochrobactrum anthropi*. Clin Infect Dis. 1996;22:845-47.
- [12] Kern WV, Oethinger M, Kaufhold A, Rozdzinski E, Marre R. *Ochrobactrum anthropi* bacteremia: Report of four cases and short review. Infection. 1993;21:306-10.

PARTICULARS OF CONTRIBUTORS:

1. Senior Resident, Department of Microbiology, SGPGIMS, Lucknow, Uttar Pradesh, India.
2. Assistant Professor, Department of Anaesthesiology, SGPGIMS, Lucknow, Uttar Pradesh, India.
3. Assistant Professor, Department of Microbiology, SGPGIMS, Lucknow, Uttar Pradesh, India.
4. Associate Professor, Department of Microbiology, SGPGIMS, Lucknow, Uttar Pradesh, India.
5. Senior Resident, Department of Microbiology, SGPGIMS, Lucknow, Uttar Pradesh, India.

NAME, ADDRESS, E-MAIL ID OF THE CORRESPONDING AUTHOR:

Dr. Chinmoy Sahu,
Associate Professor, Department of Microbiology, SGPGIMS,
Lucknow, Uttar Pradesh, India.
E-mail: sahu.chinmoy@gmail.com

PLAGIARISM CHECKING METHODS: [\[Jain H et al.\]](#)

- Plagiarism X-checker: Feb 05, 2022
- Manual Googling: Mar 29, 2022
- iThenticate Software: Apr 29, 2022 (18%)

ETYMOLOGY: Author Origin**AUTHOR DECLARATION:**

- Financial or Other Competing Interests: None
- Was informed consent obtained from the subjects involved in the study? Yes
- For any images presented appropriate consent has been obtained from the subjects. Yes

Date of Submission: **Jan 31, 2022**Date of Peer Review: **Feb 22, 2022**Date of Acceptance: **Mar 30, 2022**Date of Publishing: **May 01, 2022**