

# Tropical Pulmonary Eosinophilia Masquerading as Interstitial Lung Disease: An Interesting Case Report with Review of Literature

PRADIP KUMAR BEHERA<sup>1</sup>, KRISHNA PADARABINDA TRIPATHY<sup>2</sup>, ANKIT VATS<sup>3</sup>, PIYALI SENGUPTA<sup>4</sup>, YELISETTI CHAITANYA<sup>5</sup>



## ABSTRACT

Tropical Pulmonary Eosinophilia (TPE) is a form of occult filariasis characterised clinically by paroxysms of nocturnal cough, wheezing and dyspnoea. It is due to hyper-responsive pulmonary reaction to trapped microfilaria inside the lung tissue. Though, it is common in endemic areas, it is frequently misdiagnosed mostly as bronchial asthma or tuberculosis and the patient continues to suffer without being treated appropriately. A 36-year-old male, who presented with fever, cough and shortness of breath for a period of six months was misdiagnosed as Interstitial Lung Disease (ILD) and was put on antifibrotic agents without any relief of symptoms. He was thoroughly investigated with routine haematological tests, Absolute Eosinophil Count (AEC), X-ray of chest, High Resolution Computed Tomography (HRCT) thorax including bronchoalveolar lavage and was diagnosed as Tropical Pulmonary Eosinophilia (TPE). Diethyl Carbamazine citrate (DEC) was initiated and patient had satisfactory recovery. So, in endemic areas the possibility of TPE should always be kept in mind while evaluating cases presenting with chronic cough, dyspnoea and wheezing, even if the radiological imaging may mimic ILD.

**Keywords:** Eosinophilic pneumonia, Lymphatic filariasis, Pulmonary infiltrates with eosinophilia

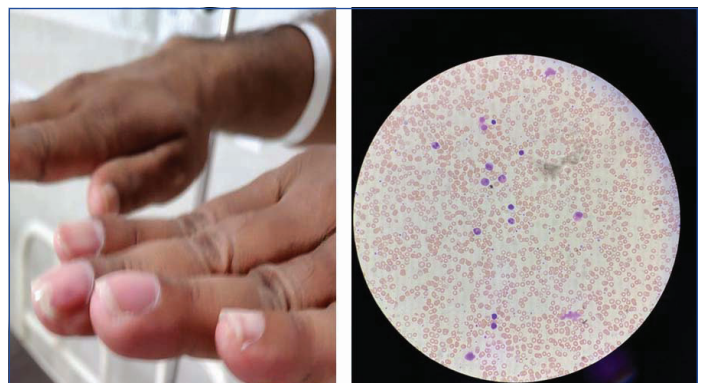## CASE REPORT

A 36-year-old male presented to the Department of Medicine, with history of fever, cough and breathlessness for a period of six months. Fever was low grade, intermittent without chills and rigor or night sweats. Cough was non productive, most often during night time and there was no history of haemoptysis or significant chest pain. He experienced progressively increasing breathlessness without orthopnea, paroxysmal nocturnal dyspnoea, palpitation or lower limb swelling during this period of six months. There was no history of weight loss, joint pain or skin rash. He was non diabetic and non hypertensive and there was no history of bronchial asthma, thyroid disease or tuberculosis. Patient was non smoker, non alcoholic and there was no significant family history. He was working in a grocery shop and there was no significant industrial, agricultural or chemical exposure.

Past medical history showed that he was diagnosed as a case of Interstitial Lung Disease (ILD) and was on nintedanib 500 mg twice daily for last two months along with inhalational bronchodilators and steroid without any significant improvement in symptoms. General examination revealed Body Mass Index (BMI) of 21.5 kg/m<sup>2</sup>, oral temperature of 100.4°C, pulse rate of 120 beats per minute, respiratory rate of 25 cycles/minute with SpO<sub>2</sub> 96% at room air. There was grade III clubbing of fingers without any other significant general examination finding [Table/Fig-1] [1]. On respiratory system examination trachea was observed to be central with bilateral reduced chest expansion. There was hyper-resonant percussion note bilaterally and auscultation revealed coarse crepitations diffusely over bilateral lung fields along with scattered ronchi. There was no clinical evidence of fibrosis, consolidation, collapse or cavity. Examination of other systems revealed no abnormality.

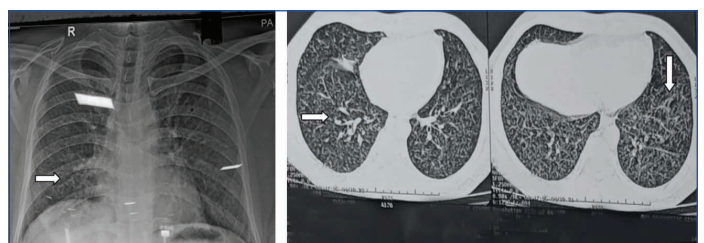
Routine investigation showed eosinophilic leukocytosis (total leucocyte count was 26,000/cmm, eosinophils was 26%), absolute eosinophilic count 6700/mm<sup>3</sup> (normal range was 20 to 500/mm<sup>3</sup>), erythrocyte sedimental range was 60 mm in 1<sup>st</sup> hour, C-Reactive Protein was 52.4 mg/dL and peripheral smear showed eosinophilia without any premature cells [Table/Fig-2]. Bilateral uniformly distributed

reticular shadows in both lung fields predominately over mid and lower zones was observed in X-ray of the chest [Table/Fig-3]. High Resolution Computed Tomography (HRCT) of thorax revealed bilateral numerous tiny centrilobular nodules with interlobar septal thickening and traction bronchiectasis with few ground glass opacities [Table/Fig-4,5]. Restrictive pattern without reversibility was noted in pulmonary function test.



**[Table/Fig-1]:** Photograph showing clubbing of fingers.

**[Table/Fig-2]:** Showing peripheral blood smear with eosinophilia, (Geimsa stain; at 100X magnification). (Images from left to right)

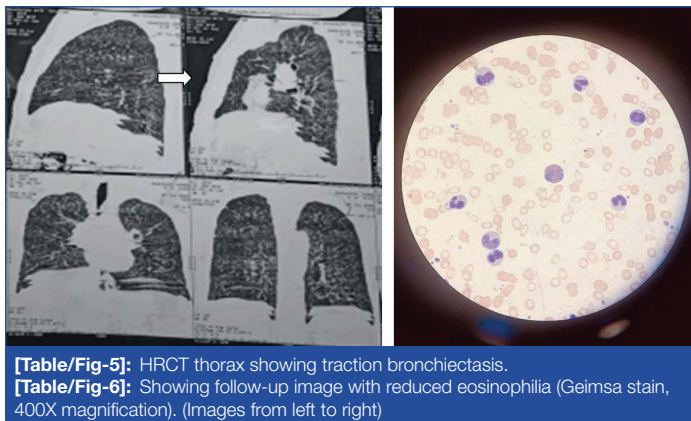


**[Table/Fig-3]:** X-ray chest showing bilateral uniformly distributed reticular shadows in both lung fields - middle and lower zones.

**[Table/Fig-4]:** High Resolution Computed Tomography (HRCT) of thorax showing bilateral numerous tiny centrilobular nodules with interlobar septal thickening, traction bronchiectasis, few ground glass opacity. (Images from left to right)

Bronchoscopy showed erythematous mucosa bilaterally in main and segmental bronchi. Bronchoalveolar Lavage (BAL) fluid cytological examination showed inflammatory cells with 80% eosinophils.

Transbronchial lung biopsy revealed interstitial inflammation with eosinophilic predominance. The IgE was elevated (3100 UI/mL). Filarial antibody was positive. Autoimmune markers like serum Antinuclear Antibody (ANA) by indirect immunofluorescence was negative. Antinuclear Cytoplasmic Antibodies (ANCA) like P-ANCA and C-ANCA were also negative. Serum Complement level (C3 and C4) were normal. Other relevant investigations for evaluation of Pyrexia of Unknown Origin (PUO) like 2D Echocardiogram was also normal. In view of high peripheral blood eosinophilia, elevated IgE level, positive antifilarial Ab and the patient being from filarial endemic area, diagnosis of tropical pulmonary eosinophilia was considered. Diethyl Carbamazine citrate (DEC) was started at a dose of 6 mg/kg body weight in three divided doses for 21 days. Patient had significant improvement of symptoms. Follow-up investigations after one month, showed decreased but still high level of peripheral eosinophilia. So a second course of DEC was given and patient had a complete clinical improvement with peripheral eosinophilia reducing to normal after two and half month since the patient presented to the department [Table/Fig-6].



[Table/Fig-5]: HRCT thorax showing traction bronchiectasis.

[Table/Fig-6]: Showing follow-up image with reduced eosinophilia (Geimsa stain, 400X magnification). (Images from left to right)

## DISCUSSION

Tropical pulmonary eosinophilia is a hyper-responsive pulmonary syndrome resulting from host immune response to microfilarial antigen of *Wuchereria bancrofti* and *Brugia malayi* [2]. Fridmott-Moller in 1940 first described it as a syndrome of wheezing, fever, eosinophilia and radiologically bilateral mottling of lungs and the condition was labelled as Pseudotuberculosis with eosinophilia. Later, in 1943 Weingarten RJ, first described the term "Tropical pulmonary eosinophilia" for this clinical entity [3].

In the year 2000, around 120 million people world wide were infected with lymphatic filariasis out of which more than 90% were due to *W. bancrofti* and the remainder largely due to *B. malayi* [4]. Due to enormous burden of Lymphatic filariasis World Health Organisation (WHO) launched the Global Program to Eliminate Lymphatic Filariasis (GPELF) with the goal of elimination of lymphatic filariasis by the year 2020 by administering preventive chemotherapy with Diethyl Carbamazine citrate (DEC) and ivermectin. This has led to decline in cases of filariasis in India but still prevalent in endemic areas. India has about 40% of the global filariasis burden and 50% of the global population at risk of infection [5]. In Indian subcontinent filariasis is a major health problem in states like Bihar, Andhra Pradesh, Odisha, Tamil Nadu, Gujarat and Kerala [6].

Tropical pulmonary eosinophilia is estimated to be <0.5% of filarial infections. The degenerating microfilaria entrapped in the lungs microcirculation triggers a wide range of cellular and humoral immune response which includes Type I, II and IV immune reactions resulting in clinical symptomatology of Tropical Pulmonary Eosinophilia (TPE). Eosinophils are the host immune component predominantly responsible for nematode clearance. Various eosinophilic granule proteins such as Eosinophilic Cationic Protein (ECP), Eosinophil Derived Neurotoxin (EDN), Major Basic Protein (MBP) etc., have shown helminthotoxic activity. This in association with eosinophil

induced cytokine response results in parasite clearance. Besides pulmonary T-helper 1 (Th1) cell response leads to elevated levels of IL4, IL5, high level of filarial specific IgE and IgG and massive pulmonary eosinophilia [7].

The TPE is commonly observed in the age group of 15 to 40 years and mostly males are affected with a male to female ratio of 4:1 [8]. A recent study by Shankar M et al., in post eradication era also showed a similar demographic profile with male preponderance (Male:Female being 2.35:1) and most patients were of less than 30 years [9]. Patients with tropical pulmonary eosinophilia usually presents with non specific clinical symptoms like fever and malaise, anorexia or weight loss and respiratory symptoms like non productive cough, wheeze and shortness of breath and chest pain which are predominantly nocturnal. Because of the similarity in symptoms they are often misdiagnosed as bronchial asthma or sometimes tuberculosis [10-12]. Few cases may present with extrapulmonary manifestations like lymphadenopathy, hepatosplenomegaly, pericarditis or pericardial effusion or pulmonary arterial hypertension [13-15]. Eosinophilic leucocytosis in peripheral blood is common which may be as high as 50000 to 80000/mm<sup>3</sup>. The ESR is usually high and serum IgE and IgG levels are elevated. Peripheral blood usually does not show any microfilaria. Pulmonary function test in advanced cases usually show restrictive pattern, but, during acute TPE may show mild obstructive pattern. Bilateral fine diffuse reticulonodular opacities in the middle and lower lung zones are the most common radiological findings in TPE. Sometimes fine mottling in chest X-ray is observed creating a confusion of miliary TB whereas 20% cases may have normal X-ray. The predominant computed tomography scan finding in HRCT thorax is the presence of widespread ill-defined bronchocentric nodules which need to be differentiated from conditions like hypersensitive pneumonitis, infections like tuberculosis, vasculitis, pneumoconiosis, bronchiolitis or metastasis [16].

But significant eosinophilia with radiologically pulmonary infiltrates in TPE put this clinical entity into a group of disorders termed as "Pulmonary infiltrates with eosinophilia" caused by a variety of infectious, inflammatory and allergic conditions. The differential diagnosis includes primary pulmonary eosinophilic disorders like acute and chronic eosinophilic pneumonia, Churg-Strauss syndrome, allergic bronchopulmonary aspergillosis, Loeffler's syndrome secondary to helminth infection or drug reaction, hypersensitive pneumonitis and idiopathic pulmonary fibrosis [17].

The diagnostic criteria for TPE includes [18]:

- History of residence or travel to a filarial endemic region
- Paroxysmal and nocturnal cough with dyspnoea
- Leukocytosis with peripheral blood eosinophilia >3000/mm<sup>3</sup>
- Elevated serum IgE and filarial antibody titers
- Pulmonary infiltrations in chest X-ray and
- Clinical improvement with DEC.

Recommended therapy for TPE is oral DEC at a dose of 6 mg/Kg in three divided doses per day for 21 days [19]. Rapid response to DEC is very characteristic of TPE [20]. A failure rate of 20-40% after DEC therapy has been reported mostly in advanced cases. In such cases treatment with corticosteroids have shown promising results, but, before steroid therapy pulmonary strongiloidosis should be ruled out [21].

Though unusual presentations of TPE has been reported by various authors like consolidation, pericardial effusion, lung cavity lesions and also misdiagnosed as other clinical conditions like miliary tuberculosis or bronchial asthma, present case masqueraded as interstitial lung disease but latter on was diagnosed as TPE which is never reported in literature before [10-14] [Table/Fig-7].

Author and year of study	Type of report	Presentation/Misdiagnosis of Tropical Pulmonary Eosinophilia (TPE)
Ray S et al., (2011) [12]	Case report	TPE misdiagnosed as Miliary Tuberculosis (TB)
Kumar S and Gautam P, (2013) [13]	Case report	TPE presenting as lung mass
Kumar S and Singh R, (2016) [14]	Case report	TPE presenting as cavitation and pneumonic consolidation with hydropneumothorax
Randev S et al., (2018) [11]	Case report	TPE misdiagnosed as bronchial asthma
Tsanglao WR et al., (2019) [10]	Case series	TPE masquerading asthma
Present study (2022)	Case report	TPE misdiagnosed as Interstitial Lung Disease (ILD)

**[Table/Fig-7]:** Case reports and case series (from India) showing unusual presentations or misdiagnosis of TPE [10-14].

## CONCLUSION(S)

Tropical Pulmonary Eosinophilia (TPE) may present with atypical clinical and radiological presentations like interstitial lung disease in addition to other unusual presentations like bronchial asthma, miliary tuberculosis or pulmonary arterial hypertension. These atypical clinical cases lead to confusion in clinical decision making like wrong diagnosis and improper treatment. So, though eradication program of lymphatic filariasis has reduced the incidence of the disease in endemic areas and has resulted in elimination of the disease in some countries, high level of suspicion of TPE in part of treating physicians is required while evaluating cases who present with such unusual presentations. This may prevent misdiagnosis of a fairly treatable clinical entity like TPE.

## REFERENCES

- Agarwal R, Baid R, Sinha DP. Clubbing: The oldest clinical sign in medicine. *CHRISMED J Health Res.* 2019;6:72-75.
- Santeliz JV. Tropical Pulmonary Eosinophilia: An epidemiological and clinical Review. *Int J Respir Pulm Med.* 2019;6:102.
- Weingarten RJ. Tropical eosinophilia. *Lancet.* 1943;1:103-05.
- World Health Organization. Global programme to eliminate lymphatic filariasis: Progress report on mass drug administration, 2014. *Weekly Epidemiol Rec.* 2015;90:489-504.
- World Health Organization. Global programme to eliminate lymphatic filariasis: Progress report, 2019. *Wkly Epidemiol Rec.* 2020;95(43):509-24.
- Swaminathan S, Perumal V, Adinarayanan S, Kaliannagounder K, Rengachari R, Purushothaman J. Epidemiological assessment of eight rounds of mass drug administration for lymphatic filariasis in India: Implications for monitoring and evaluation. *PLoS Negl Trop Dis.* 2012;6(11):e1926.
- O'Bryan L, Pinkston P, Kumaraswami V, Vijayan V, Yenokida G. Localized eosinophil degranulation mediates disease in tropical pulmonary eosinophilia. *Infect Immun.* 2003;71:1337-42.
- Mullerpattan J, Udawadia Z, Udawadia F. Tropical pulmonary eosinophilia-A review. *Indian J Med Res.* 2013;138:295-302.
- Shankar M, Ejaji MA, Choubey S, Kumar D. Clinicodemographic Profile of Tropical Pulmonary eosinophilia in a Tertiary Care Institute of Bihar. *Indian J Respir Care.* 2022;11(2):112-16.
- Tsanglao WR, Nandan D, Chandelia S, Arya NK, Sharma A. Filarial tropical eosinophilia: A condition masquerading asthma, a series of 12 cases. *Journal of Asthma.* 2019;56(7):791-98.
- Randev S, Kumar P, Dhilon P, Jindal G, Guglani V. Tropical pulmonary eosinophilia masquerading as asthma in a five year old girl. *Paediatrics and International Child Health.* 2018;38(3):231-34.
- Ray S, Kundu S, Goswami M, Mitra S. Tropical pulmonary eosinophilia misdiagnosed as miliary tuberculosis. A case report and literature review. *Parasitology International.* 2011;69(2):381-84.
- Kumar S, Gautam P. Case report: Atypical presentation of tropical pulmonary eosinophilia as a lung mass. *Biomed Res.* 2013;25:135-37.
- Kumar S, Singh R. A rare presentation of hydropneumothorax in tropical pulmonary eosinophilia: Cavitation and pneumonic consolidation in a child. *Trop Doct.* 2016;46:105-08.
- Jindal S, Nath A, Patra JK, Kumar S. Tropical pulmonary eosinophilia presenting as severe pulmonary arterial hypertension. *Ann Trop Med Public Health.* 2013;6:339-42.
- Angirish B, Jankharia B, Sanghavi P. The role of HRCT in Tropical Pulmonary Eosinophilia. *Eur J Radiol.* 2020;131(3):109207.
- Meeker DP. Pulmonary infiltrates and eosinophilia revisited. *Cleve Clin J Med.* 1989;56:199-11.
- Vijayan VK. Tropical pulmonary eosinophilia: Pathogenesis, Diagnosis and management. *Curr Opin Pulm Med.* 2007;13(5):428-33.
- Lymphatic filariasis: The disease and its control. Fifth report of the WHO Expert Committee on Filariasis. World Health Organization Technical Report Series. 1992;821:01-71.
- Vijayan VK, Sankaran K, Venkatesan P, Pravakar R. Effect of diethylcarbazine on the alveolitis of tropical eosinophilia. *Respiration.* 1991;58:255-59.
- Madan M, Gupta P, Mittal R, Chhabra S. Tropical pulmonary eosinophilia. Effect of addition of corticosteroid after failure of diethylcarbamazine therapy. *Adv Respir Med.* 2017;85:51-54.

### PARTICULARS OF CONTRIBUTORS:

- Professor, Department of Medicine, Kalinga Institute of Medical Sciences, Bhubaneswar, Odisha, India.
- Professor, Department of Medicine, Kalinga Institute of Medical Sciences, Bhubaneswar, Odisha, India.
- Postgraduate Resident, Department of Medicine, Kalinga Institute of Medical Sciences, Bhubaneswar, Odisha, India.
- Postgraduate Resident, Department of Medicine, Kalinga Institute of Medical Sciences, Bhubaneswar, Odisha, India.
- Postgraduate Resident, Department of Medicine, Kalinga Institute of Medical Sciences, Bhubaneswar, Odisha, India.

### NAME, ADDRESS, E-MAIL ID OF THE CORRESPONDING AUTHOR:

Dr. Pradip Kumar Behera,  
Flat No. B202, Elegance Apartment, Kalarahanga, PO KIIT, Bhubaneswar, Odisha, India.  
E-mail: drpradip76@gmail.com

### AUTHOR DECLARATION:

- Financial or Other Competing Interests: None
- Was informed consent obtained from the subjects involved in the study? Yes
- For any images presented appropriate consent has been obtained from the subjects. Yes

### PLAGIARISM CHECKING METHODS: [Jain H et al.]

- Plagiarism X-checker: Mar 08, 2022
- Manual Googling: Mar 16, 2022
- iThenticate Software: Apr 14, 2022 (16%)

### ETYMOLOGY: Author Origin

Date of Submission: **Mar 03, 2022**  
Date of Peer Review: **Mar 22, 2022**  
Date of Acceptance: **May 10, 2022**  
Date of Publishing: **Jun 01, 2022**