

Anaesthetic Management of a Patient with Dilated Cardiomyopathy and Acute Decompensated Heart Failure

NITU YADAV¹, BHARTI VERMA², PRIYANKA AGGARWAL³, RAHUL⁴, JOSEPH DEEVEN KRANTHIKAR CHILUKA⁵



ABSTRACT

Dilated Cardiomyopathy (DCM) is a non ischaemic heart muscle disease with left or biventricular dilatation and systolic dysfunction in the absence of other heart diseases. DCM can lead to substantial morbidity and mortality due to complications like heart failure and arrhythmias. Intraoperative management of a patient with acute decompensated heart failure due to DCM is a challenge for anaesthesiologists. This case report is about a 58-year-old male patient, who was a known case of DCM with low left ventricular ejection fraction (10-15%), Chronic Kidney Disease (CKD), chronic pancreatitis, and hypertension. He came to the Emergency Department with acute decompensated heart failure and subacute intestinal obstruction. After initial stabilisation, he was scheduled to undergo emergency exploratory laparotomy for obstruction. Intraoperative management of the patient was done successfully by ensuring normovolaemia, avoiding ventricular afterload, avoiding myocardial depression and providing adequate pain relief through multimodal analgesia. The article mentions various anaesthetic concerns, risks involved and preparations required in such a case.

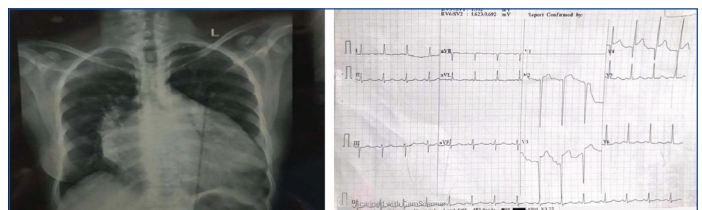
Keywords: Anaesthetic concerns, Intestinal obstruction, Systolic dysfunction

CASE REPORT

A 58-year-old male patient, who was known to have idiopathic Dilated Cardiomyopathy (DCM), visited the Emergency Department with complaints of difficulty in breathing since morning and abdominal pain, non passage of stools since five days. He also had a history of admissions for acute heart failure in the past. He was hypertensive, and had chronic pancreatitis and Chronic Kidney Disease (CKD) since four years. He was a chronic smoker and chronic alcoholic. He was operated for intestinal obstruction in 2015 under general anaesthesia. He was not taking any medications currently.

On examination, the patient was tachypneic with respiratory rate of 30/min. He had dilated neck veins, bilateral pedal oedema, distended abdomen, and bilateral crackles were heard on auscultation. Diagnosis of acute decompensated heart failure was made. The patient was put on oxygen therapy and the physician started tab. ecosprin plus atorvastatin, tab. torasemide plus spironolactone, tab. ivabradine, tab. ramipril and tab. glyceryl trinitrate. After initial stabilisation, ultrasound of the abdomen and Contrast Enhanced Computed Tomography (CECT) of the abdomen were done, which was suggestive of subacute intestinal obstruction. So, the patient was scheduled for emergency exploratory laparotomy.

On preanaesthetic examination, the patient was conscious and oriented. He had pallor and pedal oedema. He had heart rate of 97/min, blood pressure 90/60 mmHg, respiratory rate 18/min, bilateral crackles on auscultation, and he maintained 95% saturation on simple face mask at 5L/min of oxygen flow. On per abdomen examination, distension and guarding was present. Investigations showed haemoglobin 8 g/dL, Total Leucocyte Count (TLC)-3000 cmm, blood urea 118 mg/dL, serum creatinine 2.4 mg/dL and International Normalised Ratio (INR) 0.8. His chest radiograph showed cardiomegaly [Table/Fig-1]. Electrocardiogram (ECG) showed sinus tachycardia, left axis deviation, QS wave in V2-V3, ST elevation in V2-V4 [Table/Fig-2]. Ultrasound of the abdomen revealed dilated gut loops, cholelithiasis, chronic pancreatitis, hepatosplenomegaly and increased echogenicity of kidneys. 2D Echocardiography showed left ventricular ejection fraction of 10-15%.



[Table/Fig-1]: Chest radiograph showing enlarged heart shadow.

[Table/Fig-2]: ECG showing sinus tachycardia, left axis deviation, ST elevation in lead V2-V4 and QS wave in V2-V3. (Images from left to right)

The patient was shifted to the Operation Theatre (OT) after explaining all risks and taking informed consent. All routine monitors were attached. Prior to induction, under all aseptic precautions, two wide bore i.v. cannulas were secured, cannulation of the left radial artery was done and epidural catheter at T9-T10 was inserted. Induction was done using injection fentanyl 100 mcg, inj. etomidate 14 mg and inj. succinylcholine 100 mg. Injection lignocaine 2%, 60 mg was given intravenously (i.v.) to blunt intubation response. Rapid sequence intubation under direct laryngoscopy with endotracheal tube of 7.5 mm was done. Maintenance of anaesthesia was done using isoflurane+nitrous oxide+injection atracurium, FiO_2 was kept 0.35, under all aseptic precautions right internal jugular vein was cannulated. Arterial blood pressure monitoring was done. Central venous pressure-guided fluid therapy was given intraoperatively using balanced salt solution. Multimodal analgesia was given using inj. ketorolac i.v., inj. paracetamol i.v. and with epidural top ups using inj. bupivacaine 0.125%. Inj. lasix 20mg i.v. was given in graded manner for low urine output. Total blood loss was 400 mL during surgery. So, one-unit packed cell volume (PCV) was transfused. The patient had non sustained ventricular tachycardia intraoperatively, which was managed using inj. amiodarone. Multimodal mode of analgesia was used including paracetamol, opioids and thoracic epidural.

After completion of surgery, the patient was shifted to Intensive Care Unit (ICU) for elective ventilation. He was successfully extubated after 12 hours and shifted to the ward in stable condition after two days. The patient was discharged after five days with advice for follow-up in cardiac and surgery Outpatient Department (OPD).

DISCUSSION

Dilated Cardiomyopathy is a myocardial disease with structural and functional abnormalities of heart which reduces global myocardial contractility and left ventricular or biventricular dysfunction [1]. Aetiologies of DCM include genetic mutations, exposure to toxins, autoimmune diseases, endocrine and neuromuscular causes, inflammation and infections [2]. DCM may clinically present with dyspnoea, weakness, swollen legs, swollen ankles, fatigue and chest pain, arrhythmias, acute or chronic decompensation of heart, and cardiogenic shock [3]. Pharmacological modalities of treatment include Angiotensin-Converting Enzyme (ACE) inhibitors, angiotensin receptor antagonists, mineralocorticoid antagonists and funny current channel (If) inhibitors [4]. Cardiac pacing is considered in moderate to severe symptomatic heart failure (New York Heart Association (NYHA) grade 3 and 4) patients [5]. Prognosis of DCM patients depend upon the degree of systolic dysfunction of left ventricle, with threshold limit of 35% for high risk of sudden cardiac death on the basis of clinical trials done previously [6].

If a patient is in acute heart failure and requires any surgery, usually one week wait is preferred before proceeding for surgery. But this cannot not be applied for patients requiring emergency surgery. Anaesthetic concerns in the index patient were acute decompensation of heart, low ejection fraction (10-15%), emergency nature of the surgery and other multiple co-morbidities - hypertension and CKD. Induction agents with minimal or no myocardial depression effect are preferred like ketamine and etomidate [7]. Inhalational agents in low Minimum Alveolar Concentration (MAC) (≤ 1) and opioids like fentanyl and remifentanyl does not cause myocardial depression in low doses [8]. Multimodal analgesia is preferred. Epidural reduces afterload, thus increasing left ventricular forward flow and cardiac output [9].

There are a few cases that have been reported regarding the management of patients having DCM. Singh T et al., reported a case of anaesthetic management of a 23-year-old parturient with DCM undergoing elective caesarean section. The patient was known to have DCM since six years and her symptoms were well controlled on drugs. She had ejection fraction of 36%, mitral regurgitation, aortic regurgitation, global hypokinesia, and poor systolic function of left heart. In the OT, routine monitors (ECG, SpO₂ and non-invasive blood pressure) were attached. I.V. line was secured using 18 G cannula. Under all aseptic precautions, spinal anaesthesia was given using 1.2 mL of 0.5% bupivacaine plus 25 µg fentanyl at L3-L4 space. Postoperative analgesia was provided with diclofenac transdermal patch [10]. This case differs from the index case as it was elective surgery and she was not in acute decompensation of heart. Also, they did not use invasive monitoring and multimodal analgesia for intraoperative and postoperative pain relief. Good intra and postoperative analgesia is necessary to reduce pain and stabilisation of haemodynamics and reducing mortality and morbidity.

Raj R et al., reported a similar case of anaesthetic management of a 43-year-old female undergoing emergency appendectomy. She had DCM since one and half years. She had no other co-morbidities

and had no feature of Congestive Heart Failure (CHF). Her echocardiography showed left ventricular ejection fraction of 20%. Inside the OT all routine monitors were attached. After securing i.v. line, the left radial artery and right internal jugular vein cannulation was done under local anaesthesia. Combined spinal epidural block was given under all aseptic precautions. Intraoperative hypotension was managed using boluses of ephedrine [11]. This case differs from the index case as this patient had no other co-morbidities and she was not in CHF. Appendectomy is a lower abdominal surgery, so it is done under regional anaesthesia, while exploratory laparotomy required general anaesthesia.

CONCLUSION(S)

Intraoperative management of DCM is an anaesthetic challenge especially if the patient has low cardiac output and severe left ventricular dysfunction. Acute decompensation of the heart is another concern. Management of such patients coming for emergency surgery requires good preoperative assessment of the patient, meticulous planning and managing intraoperative complications. This case report mentions the significance of suitable invasive and non invasive intraoperative monitoring, maintenance of preload, reduction of afterload, good analgesia, and avoidance of myocardial depression drugs for successful intraoperative management of DCM patients.

REFERENCES

- [1] Falk RH, Hershberger RE. The dilated, restrictive, infiltrative cardiomyopathies. In: Mann DL, Zipes DP, Libby P, Bonow RO, editors. Braunwald's Heart Disease: A Textbook of Cardiovascular Medicine. 10th ed., Ch. 65. Philadelphia: Elsevier Saunders. 2015:1551-74.
- [2] Richardson P, McKenna W, Bristow M, Maisch B, Mautner B, O'Connell J, et al. Report of the 1995 World Health Organization/International Society and Federation of Cardiology Task Force on the definition and classification of cardiomyopathies. *Circulation*. 1996;93(5):841-42.
- [3] Dec GW, Fuster V. Idiopathic dilated cardiomyopathy. *N Engl J Med*. 1994;331:1564-75.
- [4] Zannad F, McMurray JJV, Krum H, Veldhuisen DJV, Swedberg K, Shi H, et al. Eplerenone in patients with systolic heart failure and mild symptoms. *N Engl J Med*. 2011;364(1):11-21.
- [5] Cleland JGF, Daubert JC, Erdmann E, Freemantle N, Gras D, Kappenberger L, et al. The effect of cardiac resynchronization on morbidity and mortality in heart failure. *N Engl J Med*. 2005;352:1539-49.
- [6] Priori SG, Lundqvist CB, Mazzanti A, Blom N, Borggrefe M, Camm J, et al. ESC guidelines for the management of patients with ventricular arrhythmias and the prevention of sudden cardiac death. *Eur Heart J*. 2015;36(41):2793-867.
- [7] Schechter WS, Kim C, Martinez M. Anesthetic induction in a child with end-stage cardiomyopathy. *Can J Anaesth*. 1995;42:404-08.
- [8] Stevens WC, Cromwell TH, Halsey MJ, Eger EL 2nd, Shakespeare TF, Bahlman SH. The cardiovascular effects of a new inhalation anesthetic, Forane, in human volunteers at constant arterial carbon dioxide tension. *Anesthesiology*. 1971;35:8-16.
- [9] Srivastava D, Tiwari T, Sahu S, Chandra A, Dhiraaj S. Anaesthetic management of renal transplant surgery in patients of dilated cardiomyopathy with ejection fraction less than 40%. *Anesthesiol Res Pract*. 2014;2014:525969.
- [10] Singh T, Taxak S, Hasija N, Anand A. Anaesthetic management of a parturient with dilated cardiomyopathy: A case report. *Egypt J Anaesth*. 2014;30:439-41.
- [11] Raj R, Kumar M, Batra M. Anaesthetic management of a case of dilated cardiomyopathy for emergency appendectomy. *Anesth Essays Res*. 2014;8(1):105-07.

PARTICULARS OF CONTRIBUTORS:

1. Senior Resident, Department of Anaesthesia, PGIMS, Rohtak, Haryana, India.
2. Postgraduate Student, Department of Anaesthesia, PGIMS, Rohtak, Haryana, India.
3. Postgraduate Student, Department of Anaesthesia, PGIMS, Rohtak, Haryana, India.
4. Postgraduate Student, Department of Anaesthesia, PGIMS, Rohtak, Haryana, India.
5. Postgraduate Student, Department of Anaesthesia, PGIMS, Rohtak, Haryana, India.

NAME, ADDRESS, E-MAIL ID OF THE CORRESPONDING AUTHOR:

Dr. Nitu Yadav,
Number 412, First Floor, Sector-14, Rohtak, Haryana, India.
E-mail: ynitu29@gmail.com

AUTHOR DECLARATION:

- Financial or Other Competing Interests: None
- Was informed consent obtained from the subjects involved in the study? Yes
- For any images presented appropriate consent has been obtained from the subjects. Yes

PLAGIARISM CHECKING METHODS: [Jain H et al.]

- Plagiarism X-checker: Feb 12, 2022
- Manual Googling: Mar 31, 2022
- iThenticate Software: Jun 13, 2022 (11%)

ETYMOLOGY: Author Origin

Date of Submission: **Feb 09, 2022**
Date of Peer Review: **Mar 16, 2022**
Date of Acceptance: **Mar 31, 2022**
Date of Publishing: **Jun 01, 2022**