

# A Harrowing Experience of Pinna Lacerations

RB NAMASIVAYA NAVIN<sup>1</sup>, S PRABAKARAN<sup>2</sup>, S RAJASEKARAN<sup>3</sup>, PN ASWIN VAISHALI<sup>4</sup>, R KARTHIKA<sup>5</sup>

## ABSTRACT

Otological injuries are not rare presentations to the Emergency Department but they may sometimes be harrowing. These injuries can sometimes lead to haematoma and perichondritis which may lead to cosmetic disfigurement. Hence, opportune and prudent intervention is required to prevent the complications. The present study was conducted to examine the wide range of pinna lacerations, various methods of repair to obtain best cosmetic results and outcome, prevention of development of complications. This case series is about 27 patients with pinna laceration and its management in patients who attended the Emergency Department at a tertiary care hospital. All lacerations of pinna due to any cause were included in the study except chemical and thermal burns. Detailed history was recorded. These patients were managed with wound debridement, suturing and were followed-up regularly to monitor the development of complications. Out of 27 patients, 21 patients had a complete wound healing without any complications. Two patients developed wound gapping and underwent resuturing under local anaesthesia. Perichondritis of pinna has occurred in three patients. Timely intervention is very important for healing and prevention of complications. Normal anatomical contour and good cosmetic results is achieved by adequate wound debridement, maximum tissue restoration, meticulous suturing and wide antibiotic coverage.

**Keywords:** Perichondritis of pinna, Pinna abrasions, Pinna avulsion, Pinna deformity

## INTRODUCTION

Trauma to the ear is complex occurs due to various harmful agents which affects different parts of the ear [1]. Most of the pinna lacerations are due to road traffic accidents but other causes include assault and sporting injury. Trauma to the external ear can cause abrasions, lacerations, auricular haematomas, and partial or total avulsions [2]. Pinna lacerations may range from a simple laceration to complex avulsions. The proper recognition of the injuries and time management is very important to improve the treatment and outcomes and, to avoid the development of complications [1].

These injuries can sometimes lead to haematoma and perichondritis resulting in cosmetic disfigurement. Hence, opportune and prudent intervention is required to prevent the complications. The golden rule in the management is to balance minimal wound debridement with maximal tissue preservation under adequate anaesthesia [3]. Under aseptic precautions, a good approximation of a wound with adequate vascularity with wound care will result in the best outcome [4]. The type of reconstruction will depend on the extent, size of the injuries, and cosmesis expected by the procedure [2]. The involvement of the cartilage, poor vascularity of the region, and need for high cosmetic satisfaction are the complicating factors while reconstructing the pinna making it difficult to manage and chance for deformity is more common [5].

The objective of documenting this series of cases is to present the wide range of pinna lacerations and repair of the same to obtain best cosmetic results and outcome, prevention of development of complications.

## CASE SERIES

A total of 27 cases who presented to the Emergency Department of the tertiary care centre in the last one year have been presented here. All lacerations of pinna due to any cause were included in the series, except chemical and thermal burns [Table/Fig-1]. Detailed history was recorded.

Tetanus toxoid injection was given through intramuscular route for prophylaxis. All patients were locally anaesthetised in the

Cause	Number of cases
Road traffic accident	17 (62.96%)
Assault	6 (22.22%)
Slip and fall	4 (14.82%)
Total	27 (100%)

[Table/Fig-1]: Causes for pinna lacerations.

form of auricular block with 4% xylocaine with adrenaline after giving test dose. Thorough wash was done with saline followed by metronidazole. Devascularised tissues have been debrided. The lacerated wound was sutured with 4-0 ethilon and dressing was done. Following which patient was given prophylactic oral ciprofloxacin 500 mg twice daily with aceclofenac and serratiopeptidase. Patient was kept on regular follow-up and the complications were recorded.

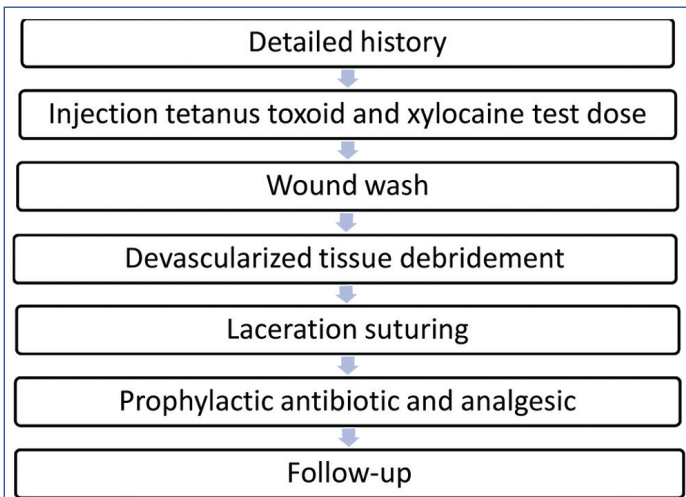
Out of 27 patients, 15 patients were male and 12 patients were female [Table/Fig-2]. All the patients were treated with a standard protocol [Table/Fig-3].

Variables	Number of patients
<b>Age group (years)</b>	
<18 years	5
18-40 years	19
>40 years	3
<b>Gender</b>	
Male	15
Female	12

[Table/Fig-2]: Distribution of age and gender.

All patients were followed-up regularly to assess the wound healing and development of complications [Table/Fig-4]. Out of 27 patients, 21 had a complete wound healing without any complications [Table/Fig-5,6], two patients developed wound gapping [Table/Fig-7] and underwent resuturing under local anaesthesia. Perichondritis of pinna has occurred in three patients and were admitted for intravenous antibiotics to prevent further complications and one

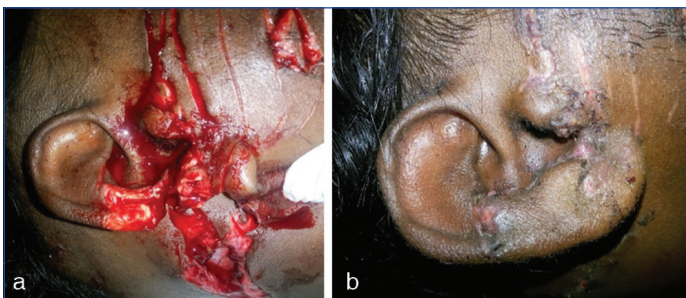
patient developed perichondria abscess which leads to fibrosis, scarring, and finally minimal pinna deformity [Table/Fig-8].



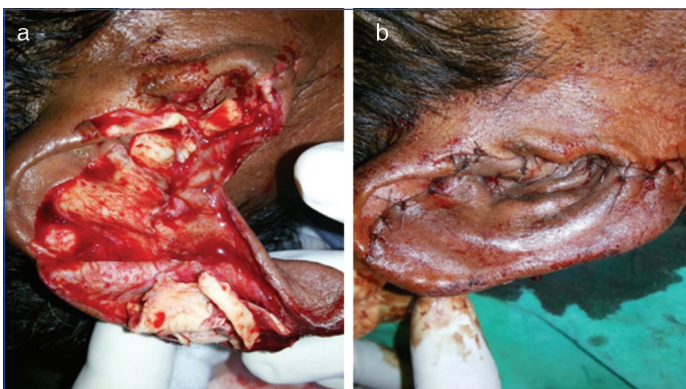
[Table/Fig-3]: Standard protocol for pinna laceration.

Results	Number of patients
Complete wound healing	21
Wound gapping	2
Perichondritis	3
Deformity	1

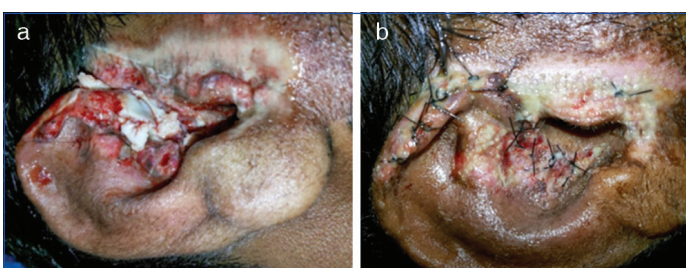[Table/Fig-4]: Results of pinna laceration postsuturing (N=27).



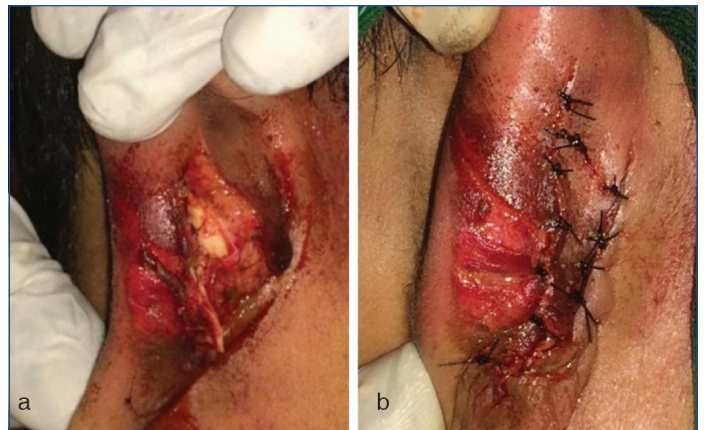[Table/Fig-5]: Pinna laceration with postoperative wound healing; a) Pinna laceration due to road traffic accident; b) Complete wound healing.



[Table/Fig-6]: Avulsion of pinna with cartilage laceration; a) Assault causing laceration of right pinna; b) After suturing of laceration.



[Table/Fig-7]: Lateral aspect of pinna laceration and abrasion due to road traffic accident with minimal wound gapping; a) Right pinna injury due to road traffic accident; b) Minimal wound gapping.

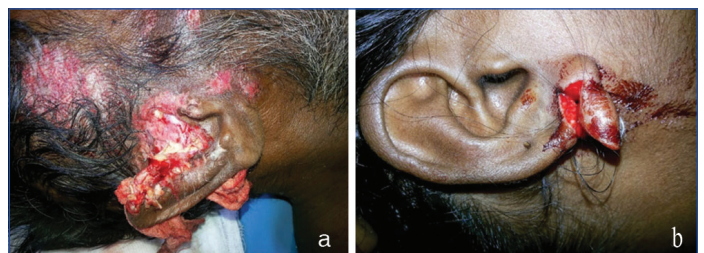

[Table/Fig-8]: Medial aspect of pinna laceration with perichondritis; a) Pinna laceration involving its medial surface; b) Injury associated with perichondritis.

## DISCUSSION

The pinna is made up of single elastic cartilage which is tightly adherent to skin on its lateral surface and slightly loose and mobile on medial surface [1]. It is supplied by posterior auricular, superficial temporal and occipital artery. The cartilage is present between the skin and its protruded nature is the reason for traumatic injuries and post-traumatic infections [5]. The incidence of trauma to the face is a common initial presentation in the Emergency Departments [2].

Traumatic pinna injuries vary from simple abrasion to laceration and complete avulsions involves skin, cartilage or both [2]. The causes of pinna injuries are road traffic accidents, ballistic injuries and animal/human bites [Table/Fig-9]. These injuries are caused by various mechanisms such as blunt trauma, blow and slaps to the ears which results in various spectrum of injuries [6]. The main goal of the treatment is to achieve the normal contour without infection. Immediate suturing, maximum tissue preservation and prevention of perichondritis are very crucial in reducing the cosmetic pinna deformity [3]. These external injuries of pinna are managed by Oral and Maxillofacial Surgeons, Otolaryngologists and also Plastic Surgeons [7].



[Table/Fig-9]: Various types of pinna laceration; a) Pinna avulsion due to road traffic accident; b) Pinna laceration due to accidental injury by sharp object.

Under local anaesthesia, the wound should be washed thoroughly with saline followed by metronidazole to remove any foreign bodies. Devitalised tissue should be removed and irregular skin edges can be trimmed. Lacerated wound is sutured with non absorbable suture material. Absorbable sutures can be used in paediatric age groups. After meticulous suturing, pressure dressing and prophylactic antibiotics is necessary for proper healing without any complications [8]. Patient should be followed-up regularly to monitor the development of any complications. A study conducted on pinna injuries on 24 patients reported that 16 had complete healing, 3 developed perichondritis, 3 had minor, and 3 had major deformity [1]. Singla B et al., reported a case of pinna laceration managed by primary repair with wedge resection and obtained good cosmetic result [3]. Shameem Ahmad SV et al., studied 45 cases of pinna injuries, complete healing occurred in 80%, perichondritis developed in 15.5%, and deformity occurred in 4.5% [4].

In the present series, all the patients with various types of pinna lacerations were managed with timely suturing, prophylactic antibiotics

and followed-up regularly. Out of the 27 patients, a majority (77.8%) had complete wound healing without any complications. 7.4% of patients developed wound gapping and underwent resuturing under local anaesthesia. Perichondritis of pinna has occurred in 11.1% patients and treated with intravenous antibiotics. Deformity was occurred in 3.7% of patients. Immediate suturing and prophylactic antibiotics are essential for proper healing, restore the normal contour and prevention of deformity. Because of various depressions and elevations in the pinna, skin tightly adherent on the lateral surface of pinna, it is difficult to suture and attain normal contour.

The complications of these injuries are haematoma formation, secondary infection causing perichondritis and finally deformity [4]. Haematoma in subperichondrial plane can cause infection, necrosis, new irregular cartilage formation and finally cauliflower ear [1]. Ear deformity occurs due to stimulation of mesenchymal cells in the perichondrium and new fibrocartilage production [9]. Haematoma can be drained by 18 gauge needle of incision and drainage method [2]. Perichondritis is characterised by pain, redness and local rise of temperature and finally abscess formation. Immediate drainage of pus is very important to prevent development of deformity. Patient should be admitted for administration of intravenous antibiotics and daily dressing of the wound. The development of these complications can be prevented by early intervention, wound debridement, timely suturing and good antibiotic coverage [4].

This study concluded that timely intervention like proper exploration of pinna laceration, thorough washing of the wound with metronidazole, immediate suturing, and prophylactic antibiotics to prevent complications helps in attaining the success rate of 77.8% and the development of deformity is reduced to 3.7%.

## CONCLUSION(S)

Traumatic pinna lacerations are very common due to increased incidence of road traffic accidents. Timely intervention is very important for healing and prevention of complications. Normal anatomical contour and good cosmetic results is achieved by adequate wound debridement, maximum tissue restoration, meticulous suturing and wide antibiotic coverage. Regular follow-up will help in early identification of complications and prompt treatment to prevent the incidence of cauliflower ear.

## REFERENCES

- [1] Saimanohar S, Gadag RP, Subramaniam V, Ravindra P. A study of pinna injuries and their management. *International Journal of Health and Rehabilitation Sciences*. 2012;1(2):81-86.
- [2] Nojumi A, Woo BM. Management of Ear Trauma. *Oral Maxillofac Surg Clin North Am*. 2021;33(3):305-15.
- [3] Singla B, Chawla I, Gautam P, Goyal A, Rathi J. Primary repair of ear laceration with wedge resection. *Plastic and Aesthetic Research*. 2015;2(1):38-39.
- [4] Shameem Ahmad SV, Mukundan A, Githin CR, Mary L. Pinna injuries: Our experience. *Journal of Medical Science and Clinical Research*. 2017;5(3):18782-86.
- [5] Menon A, Alagesan G. Traumatic partial avulsion of pinna reconstruction with Limberg flap. *World J Plast Surg*. 2018;7(2):231-34.
- [6] Haik J, Givol O, Kornhaber R, Cleary M, Ofir H, Harats M. Cauliflower ear—a minimally invasive treatment method in a wrestling athlete: A case report. *International Medical Case Reports Journal*. 2018;11:05-07.
- [7] Sharma R, Sharma P, Sindhi M. Resuturing of avulsed pinna: A case report. *Int J Dent Med Res*. 2014;1(3):63-65.
- [8] Turpin IM. Microsurgical replantation of the external ear. *Clin Plast Surg*. 1990;17(2):397-04.
- [9] Akpalaba IO, Ogisi FO, Momoh RO. Otorhinolaryngological trauma in some private health facilities in Benin City. *Journal of Complementary and Alternative Medical Research*. 2021;13(1):20-28.

### PARTICULARS OF CONTRIBUTORS:

1. Assistant Professor, Department of Otorhinolaryngology, Chettinad Hospital and Research Institute, Chennai, Tamil Nadu, India.
2. Assistant Professor, Department of Otorhinolaryngology, Chettinad Hospital and Research Institute, Chennai, Tamil Nadu, India.
3. Professor and Head, Department of Otorhinolaryngology, Chettinad Hospital and Research Institute, Chennai, Tamil Nadu, India.
4. Junior Resident, Department of Otorhinolaryngology, Chettinad Hospital and Research Institute, Chennai, Tamil Nadu, India.
5. Junior Resident, Department of Otorhinolaryngology, Chettinad Hospital and Research Institute, Chennai, Tamil Nadu, India.

### NAME, ADDRESS, E-MAIL ID OF THE CORRESPONDING AUTHOR:

Dr. S Prabakaran,  
3/286, Pachaiyappar Street, Periyar Salai, Palavakkam, Chennai, Tamil Nadu, India.  
E-mail: somu.prabakaran@gmail.com

### PLAGIARISM CHECKING METHODS: [Jan H et al.]

- Plagiarism X-checker: Jan 10, 2022
- Manual Googling: May 20, 2022
- iThenticate Software: Jun 15, 2022 (3%)

### ETYMOLOGY: Author Origin

### AUTHOR DECLARATION:

- Financial or Other Competing Interests: None
- Was informed consent obtained from the subjects involved in the study? Yes
- For any images presented appropriate consent has been obtained from the subjects. Yes

Date of Submission: **Jan 03, 2022**

Date of Peer Review: **Feb 01, 2022**

Date of Acceptance: **May 23, 2022**

Date of Publishing: **Aug 01, 2022**