

Urethral Sounding: Experience from Two Tertiary Care Centres in Northern India

MOHD MUBASHIR ALI KHAN¹, GYANENDRA SINGH², MUKESH KUMAR³, APUL GOEL⁴

ABSTRACT

Introduction: Foreign bodies have been removed from urethra and bladder of young females since time immemorial. Various explanations have been offered by the patients but the variety, multiplicity and large sizes indicate masturbation as the major cause.

Aim: To study the characteristics and find out the actual motive of urethral sounding at two tertiary care centres in Uttar Pradesh, India.

Materials and Methods: This was a retrospective study conducted between January 2021 to December 2021 analysing the records of all patients who presented to Urology Emergency of King George's Medical University, Lucknow and Uttar Pradesh University of Medical Sciences, Saifai, Etawah between June 2006 to June 2020 with foreign bodies in the urethra or urinary bladder. Data regarding the age, marital status of patient, type of foreign body and its location in the lower urinary tract, presence of any psychiatric illness, method of removal of the foreign body and possible cause of insertion of the foreign body from the records were collected. Data was segregated, coded and recorded in the Microsoft® Excel

spreadsheet. Descriptive data was presented as percentages and analysed using Statistical Package for the Social Sciences (SPSS) version 24.0 by IBM, USA.

Results: A total of 21 patients presented to the urology emergency with foreign body in the lower urinary tract between June 2006 to June 2020. None of the patients had any known psychiatric illness and all of them were adult males with age ranging from 18 to 45 years. Eight patients were managed by removal of foreign body with the help of artery forceps while 12 patients underwent cystoscopic removal of foreign body. One patient who had knotted electric wire in urinary bladder required laser fragmentation. Thirteen of the patients confessed to urethral masturbation while the rest offered vague explanations like accidental insertion or simply inquisitiveness.

Conclusion: The results of this retrospective study indicate that urethral masturbation using foreign body exists in the healthy adult males. It generally does not come into notice until the patient ends up with impaction of the foreign body. More studies need to be done to see whether this could be a possible cause of urethral stricture in patients with inadequate history.

Keywords: Foreign body, Orgasm, Paraphilia, Sexual gratification, Urethral masturbation

INTRODUCTION

Foreign bodies have been removed from urethra and bladder of young females since time immemorial. Various explanations have been offered by the patients but the variety, multiplicity and large size indicate masturbation as the major cause. Presentation may be late in some patients due to fear of embarrassment [1]. Patient usually presents with difficulty in urination, haematuria, dysuria or may lead up in complete urinary retention [2]. These foreign bodies are easily diagnosed by ultrasonography or x-ray imaging. Polyembolokolomania is the term described for the act of inserting various foreign bodies into the bodily orifices [3,4]. There have been several case reports of urethral sounding in the literature [5]. Most of these studies report sexual or erotic pleasure as the reason for insertion of foreign body [1,6-8]. Limited evidence exists in literature for the analysis of the nature and cause of urethral sounding in patients over a long period of time [9]. In present study, authors have shared their experience about incidence and real motive of urethral sounding at two tertiary centres over a period of 14 years.

MATERIALS AND METHODS

This was a retrospective study conducted between January 2021 to December 2021 analysing the records of all patients who had presented to Urology Emergency with foreign bodies in the urethra or urinary bladder between June 2006 to June 2020 at King George's Medical University, Lucknow and Uttar Pradesh University of Medical Sciences, Saifai, Etawah, Uttar Pradesh, India. Permission to assess, analyse and publish the data of these patients were taken from the Head of Department of Urology of the two centres.

Data regarding the age, marital status of patient, type of foreign body and its location in the lower urinary tract, presence of any psychiatric

illness, method of removal of the foreign body and possible cause of insertion of the foreign body from the medical records were collected. Informed consent was taken from all the patients.

STATISTICAL ANALYSIS

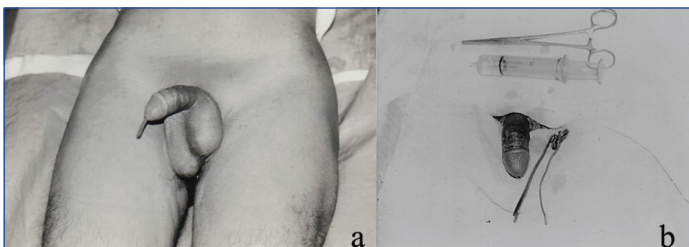Data was segregated, coded and recorded in the Microsoft® Excel spreadsheet. Descriptive percentages and frequencies were represented by constructing tables. Mean and standard deviation were summarised for continuous variables, whereas frequencies and proportions for categorical variables. All statistical analysis was performed with statistical software using Statistical Package for the Social Sciences (SPSS) version 24.0 by IBM, USA.

RESULTS

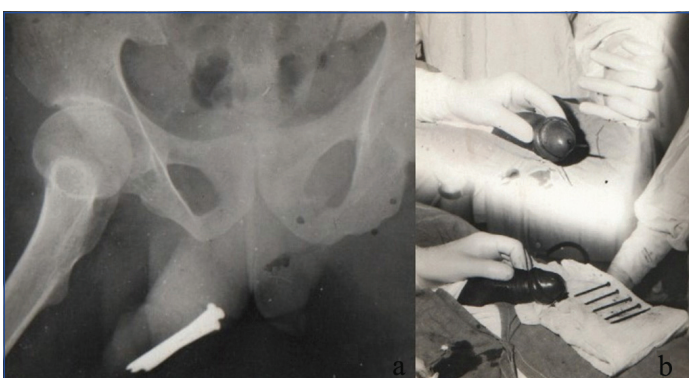
A total of 21 patients presented in the Urology Emergency of King George's Medical University, Lucknow and Uttar Pradesh University of Medical Sciences, Saifai, Etawah with foreign body in the lower urinary tract during June 2006 to June 2020. Patient characteristics, type and location of foreign body, cause of insertion and management strategies are enlisted in [Table/Fig-1]. None of the patients had any known psychiatric illness and all of them were adult males with age ranging from 18 to 45 years. Mean age was 29.3±2.1 years, 12 (57.14%) of them were married, 10 (47.62%) patients had foreign body impacted in the anterior urethra, 5 (23.81%) patients had the foreign body in the posterior urethra while the foreign body in the urinary bladder was found in 6 (28.57%) patients. Seven patients had inserted insulated plastic wire [Table/Fig-2], four patients had inserted a long needle, four patients had inserted nails [Table/Fig-3], three patients had inserted thin wooden stick, two patients had inserted house broom straw and one patient had inserted hair pin [Table/Fig-4].

Characteristics	n (%)
Marital status	
Married	12 (57.14)
Unmarried	9 (42.86)
Divorced	0
Presence of any psychiatric illness	
	0
Location of foreign body	
Anterior urethra	10 (47.62)
Posterior urethra	5 (23.81)
Urinary bladder	6 (28.57)
Type of foreign body	
Insulated plastic wire	7 (33.33)
Long needle	4 (19.05)
Nails	4 (19.05)
Thin wooden stick	3 (14.28)
House broom straw	2 (9.52)
Hair pin	1 (4.77)
Management strategy	
Removal by artery forcep	8 (38.10)
Cystoscopic removal	12 (57.14)
Transurethral laser fragmentation	1 (4.76)
Type of anaesthesia used	
Spinal anaesthesia	6 (28.57)
Local anaesthesia	15 (71.43)
Cause of insertion of foreign body as given by the patient	
Urethral masturbation	13 (61.90)
Accidental insertion	8 (38.10)

[Table/Fig-1]: Patient characteristics, type, location, causes and treatment of foreign bodies in urethra or urinary bladder (N=21).

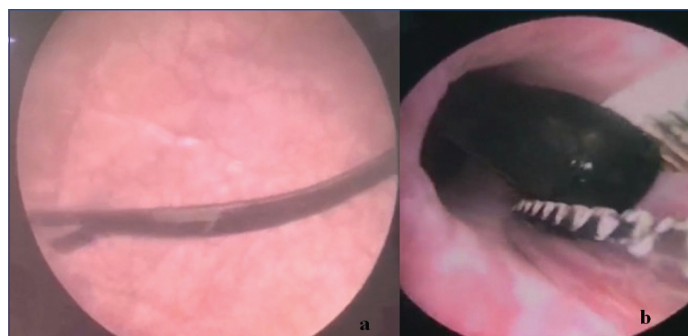


[Table/Fig-2]: Insulated plastic wire in the urethra (a) which was extracted from the urethra with the help of artery forcep (b).



[Table/Fig-3]: Multiple nails seen in the penile urethra in X-ray pelvis (a) which were extracted by gentle milking (b).

About 13 (61.90%) patients confessed to urethral masturbation while the rest offered vague explanations like accidental insertion or simply inquisitiveness. Spinal anaesthesia was given in 6 (28.57%) cases while 15 (71.43%) were managed by local anaesthesia [Table/Fig-1]. Foreign bodies palpated in the penile urethra (n=8) were gently milked distally under local anaesthesia and pulled out with an artery forceps. Foreign bodies which were presented in the bulbar



[Table/Fig-4]: Hair pin in the urinary bladder (a) which was removed with the aid of 21 Fr Storz cystoscope and forceps under 20x magnification (b).

urethra, posterior urethra or bladder (n=12) were removed with the help of cystoscope. One case of knotted electric wire located in the urinary bladder was removed by the laser fragmentation.

None of the patients had haematuria. After removal of the foreign body, catheter was inserted for two-three days in 15 patients while six were left as such. The decision to catheterise was taken if there was urethral inflammation or if the foreign body was present for more than a day.

All patients were referred to Psychiatry Department for psychological evaluation. All patients were given broad spectrum oral antibiotics (cefixime) and oral analgesics (aceclofenac) for a period of three to five days. All patients were counselled and followed-up on Outpatient Department (OPD) basis. None of the patients reported any significant problems like stricture or haematuria in the follow-up visits.

DISCUSSION

The case reports of insertion of foreign bodies in the urethra have ever been increasing [5,8-10]. The various reasons for insertion of these bodies are erotic impulses, mental illness and sexual curiosity [11]. The facts that were borne out of the present study were that the patients practising urethral sounding were healthy males without any reported psychological disorder. Thirteen of them confessed on confidential questioning to achieving an orgasm like state after the insertion of foreign body in the urethra.

Many authors consider urethral masturbation both as a psychiatric as well as urologic disease [12-14]. There are few theories that explain the reason for self-insertion of foreign bodies into the urethra. As per Kenney RD theory, there often tends to be an accidentally discovered pleasurable stimulation of the urethra. He further proposed that a particular psychological predisposition to sexual gratification drives the patient to repeat this behaviour using objects which he think are potentially harmless [13]. Wise TN considered self-insertion of foreign bodies into the urethra as a type of paraphilia and has a combination of sadomasochistic and fetishist elements [14]. An internet-based survey done on 2000 men who had sex with men reported a 10% incidence of recreational urethral sounding. The study also concluded that urethral masturbation was associated with a higher risk of sexually transmitted infections and indulgence in high-risk sexual behaviours including sex with strangers and multiple sexual partners [6]. However such behaviour was not found among the patients in this study.

None of the patients included in this study had haematuria indicating a careful rehearsed insertion of the foreign body. The male urethra has the verumontanum with the opening of seminal vesicles close by and muscle sphincter distal to it [15]. Authors propose that the stimulation of urethra or the verumontanum is the objective but the simultaneous contraction of distal sphincter sucks in the foreign body causing impaction at the bladder neck. The length of the foreign body is also an indication that the purpose was stimulation of the posterior urethra.

There are several techniques that can be utilised for the removal of these self-inserted foreign bodies. These include cystoscopy, suprapubic cystostomy, meatotomy, fogarty catheterisation, internal or external urethrotomy and injection of solvents [10]. In the present study, all the foreign bodies were successfully removed either by endoscopic retrieval or adequate lubrication with milking. The process was atraumatic because no haematuria or subsequent stricture formation was reported. No suprapubic cystostomy or urethrotomy was required. All the patients were given adequate psychiatric counselling at the time of discharge as the risk of recurrence is high in these cases [16,17].

Urethral sounding often leads to impacted or retained foreign bodies either in the urethra or urinary bladder. These could predispose the patient to urinary complications like infections, haematuria, acute urinary retention and dysuria. Such conditions need urgent intervention and removal of the foreign bodies [9].

Limitation(s)

The present study had few limitations. Firstly, the actual prevalence of urethral masturbation could not be determined as only those patients who end up in some complication from this practice only visit the hospital. Secondly, long-term follow-up was not done so long-term complications like urethral stricture could not be evaluated. Thirdly, the recurrence rate of urethral masturbation after proper psychiatric counselling in these patients was not evaluated.

CONCLUSION(S)

The results of this retrospective study indicate that urethral masturbation using foreign body exists in the healthy adult males. It generally does not come into notice until the patient ends up with impaction of the foreign body. More studies are required to see whether this could be a possible cause of urethral stricture in patients with inadequate history.

REFERENCES

- [1] Van Ophoven A, deKernion JB. Clinical management of foreign bodies of the genitourinary tract. *J Urol.* 2000;164(2):274-87.
- [2] Thomsen TW, Setnik GS. Videos in clinical medicine. Male urethral catheterization. *N Engl J Med.* 2006;354(21):e22.
- [3] Lesser JM, Hughes SV, Jemelka JR, Griffith J. Sexually inappropriate behaviors. Assessment necessitates careful medical and psychological evaluation and sensitivity. *Geriatrics.* 2005;60(1):34:36-37.
- [4] Rosenthal M, Berkman P, Shapira A, Gil I, Abramovitz J. Urethral masturbation and sexual disinhibition in dementia: A case report. *Isr J Psychiatry Relat Sci.* 2003;40(1):67-72.
- [5] Aggarwal P, Sandhu, AS. Urethral masturbation, urethral foreign body-Review of cases. *Indian J Surg.* 2021;83:1574-77.
- [6] Breyer BN, Shindel AW. Recreational urethral sounding is associated with high risk sexual behaviour and sexually transmitted infections. *BJU International.* 2012;110(5):720-25.
- [7] Rinard K, Nelius T, Hogan L, Young C, Roberts AE, Armstrong ML. Cross-sectional study examining four types of male penile and urethral "play". *Urology.* 2010;76:1326-33.
- [8] Grubišić I, Stimac G, Pezelj I, Svagaša I, Katušić J, Spajić B. Intravesical foreign body as a result of self catheterization: Case report. *Acta Clin Croat.* 2014;53(3):359-61.
- [9] Bansal A, Yadav P, Kumar M, Sankhwar S, Purkait B, Jhanwar A, et al. Foreign bodies in the urinary bladder and their management: A single-centre experience from North India. *Int Neurourol J.* 2016;20(3):260-69.
- [10] Bedi N, El-Husseiny T, Buchholz N, Masood J. 'Putting lead in your pencil': Self-insertion of an unusual urethral foreign body for sexual gratification. *JRSM Short Rep.* 2010;1(2):18. Doi: 10.1258/shorts.2010.010014.
- [11] Craciun M, Omorphos S, Lunawat R, Kanaga-Sundaram S. Searching for the G spot in the urinary bladder: Autoerotism and potential complications. *J Sur Case Rep.* 2014;2014(3):rju020.
- [12] Costa G, Di Tonno F, Capodiecì S, Laurini L, Casagrande R, Lavelli D, et al. Self-introduction of foreign bodies into the urethra: A multidisciplinary problem. *Int Urol Nephrol.* 1993;25(1):77-81.
- [13] Kenney RD. Adolescent males who insert genitourinary foreign bodies: Is psychiatric referral required? *Urology.* 1988;32(2):127-29.
- [14] Wise TN. Urethral manipulation: An unusual paraphilia. *J Sex Marital Ther.* 1982;8(3):222-27.
- [15] Chavez J. Anatomy & histology-male urethra. *PathologyOutlines.com website.* <https://www.pathologyoutlines.com/topic/prostateurethramalenormal.html>. Accessed May 5th, 2022.
- [16] Ali Khan S, Kaiser CW, Dailey B, Krane R. Unusual foreign body in the urethra. *Urol Int.* 1984;39(3):184-86.
- [17] Lackey JT, Acosta S. Unusual objects found in lower urinary tract. *Urology.* 1973;2(1):75-76.

PARTICULARS OF CONTRIBUTORS:

1. Assistant Professor, Department of Urology, Uttar Pradesh University of Medical Sciences, Etawah, Uttar Pradesh, India.
2. Assistant Professor, Department of Urology, Uttar Pradesh University of Medical Sciences, Etawah, Uttar Pradesh, India.
3. Assistant Professor, Department of Urology, Uttar Pradesh University of Medical Sciences, Etawah, Uttar Pradesh, India.
4. Professor, Department of Urology, King George's Medical University, Lucknow, Uttar Pradesh, India.

NAME, ADDRESS, E-MAIL ID OF THE CORRESPONDING AUTHOR:

Dr. Gyanendra Singh,
554/1374, Pawanpuri, Alambagh, Lucknow-226005, Uttar Pradesh, India.
E-mail: sgyanendra24@gmail.com

PLAGIARISM CHECKING METHODS: [Jain H et al.]

- Plagiarism X-checker: May 26, 2022
- Manual Googling: Jun 08, 2022
- iThenticate Software: Jul 29, 2022 (8%)

ETYMOLOGY: Author Origin

AUTHOR DECLARATION:

- Financial or Other Competing Interests: None
- Was Ethics Committee Approval obtained for this study? No
- Was informed consent obtained from the subjects involved in the study? Yes
- For any images presented appropriate consent has been obtained from the subjects. Yes

Date of Submission: **May 19, 2022**

Date of Peer Review: **Jun 08, 2022**

Date of Acceptance: **Jul 20, 2022**

Date of Publishing: **Aug 01, 2022**